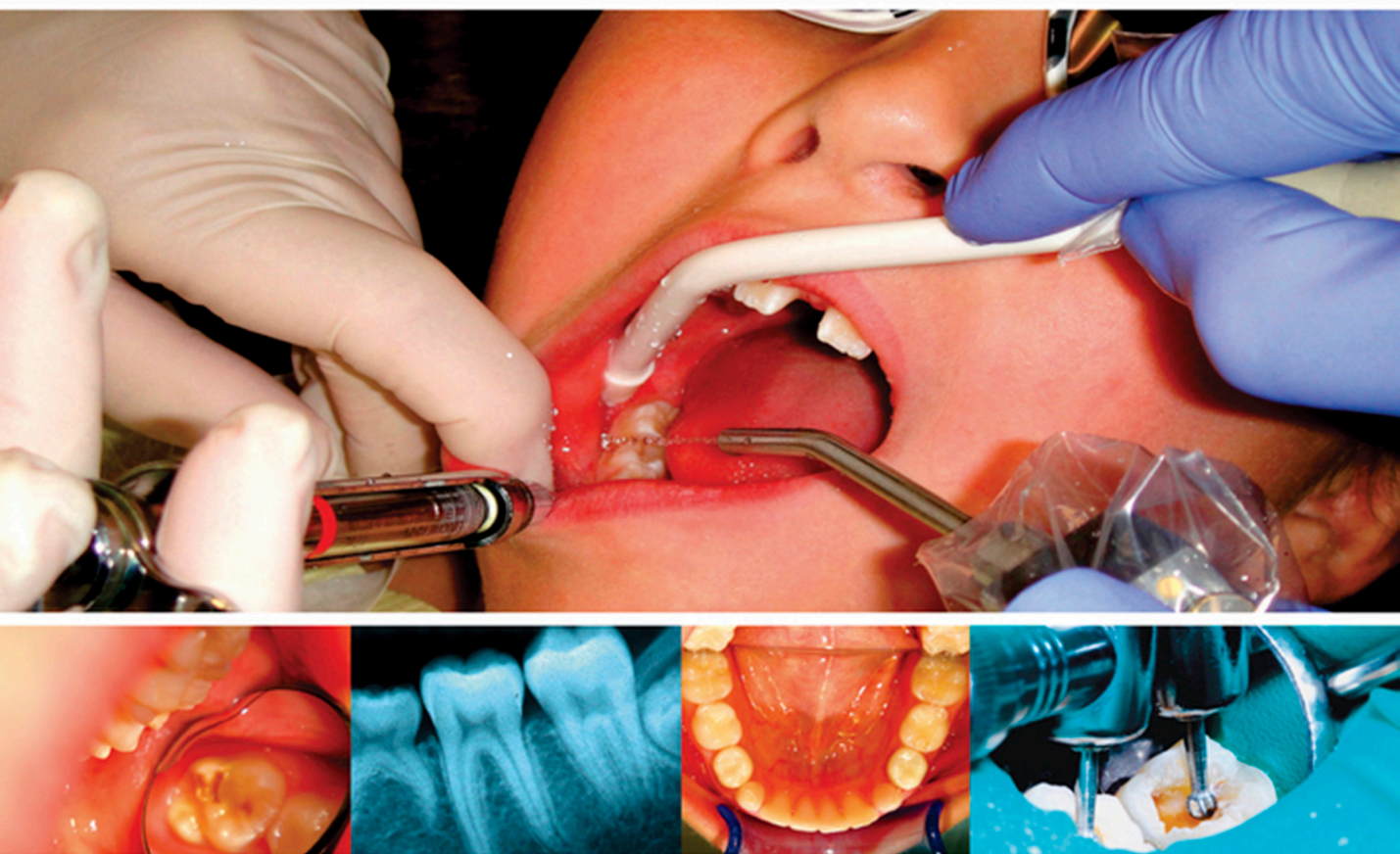

Handbook of Clinical Techniques in Pediatric Dentistry



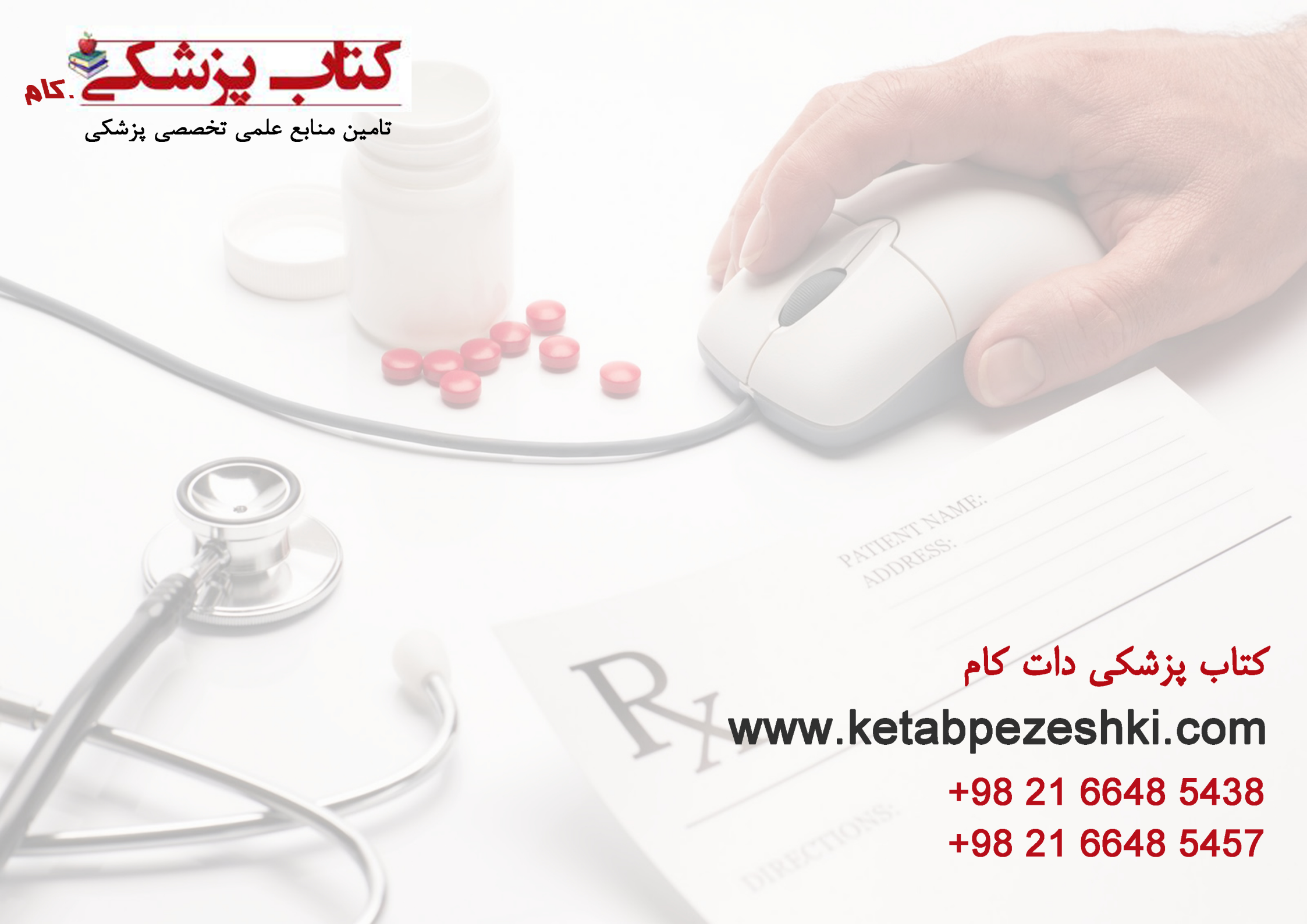Edited by **Jane A. Soxman**



WILEY Blackwell

کتاب پزشکی کام

تامین منابع علمی تخصصی پزشکی



کتاب پزشکی دات کام

www.ketabpezeshki.com

+98 21 6648 5438

+98 21 6648 5457

Handbook of Clinical Techniques in Pediatric Dentistry

Handbook of Clinical Techniques in Pediatric Dentistry

EDITED BY

Jane A. Soxman, RN, DDS

WILEY Blackwell

This edition first published 2015 © 2015 by John Wiley & Sons, Inc.

Editorial offices: 1606 Golden Aspen Drive, Suites 103 and 104, Ames, Iowa 50010, USA
The Atrium, Southern Gate, Chichester, West Sussex, PO19 8SQ, UK
9600 Garsington Road, Oxford, OX4 2DQ, UK

For details of our global editorial offices, for customer services and for information about how to apply for permission to reuse the copyright material in this book please see our website at www.wiley.com/wiley-blackwell.

Authorization to photocopy items for internal or personal use, or the internal or personal use of specific clients, is granted by Blackwell Publishing, provided that the base fee is paid directly to the Copyright Clearance Center, 222 Rosewood Drive, Danvers, MA 01923. For those organizations that have been granted a photocopy license by CCC, a separate system of payments has been arranged. The fee codes for users of the Transactional Reporting Service are ISBN-13: 978-1-118-79269-8/2015.

Designations used by companies to distinguish their products are often claimed as trademarks. All brand names and product names used in this book are trade names, service marks, trademarks or registered trademarks of their respective owners. The publisher is not associated with any product or vendor mentioned in this book.

The contents of this work are intended to further general scientific research, understanding, and discussion only and are not intended and should not be relied upon as recommending or promoting a specific method, diagnosis, or treatment by health science practitioners for any particular patient. The publisher and the author make no representations or warranties with respect to the accuracy or completeness of the contents of this work and specifically disclaim all warranties, including without limitation any implied warranties of fitness for a particular purpose. In view of ongoing research, equipment modifications, changes in governmental regulations, and the constant flow of information relating to the use of medicines, equipment, and devices, the reader is urged to review and evaluate the information provided in the package insert or instructions for each medicine, equipment, or device for, among other things, any changes in the instructions or indication of usage and for added warnings and precautions. Readers should consult with a specialist where appropriate. The fact that an organization or Website is referred to in this work as a citation and/or a potential source of further information does not mean that the author or the publisher endorses the information the organization or Website may provide or recommendations it may make. Further, readers should be aware that Internet Websites listed in this work may have changed or disappeared between when this work was written and when it is read. No warranty may be created or extended by any promotional statements for this work. Neither the publisher nor the author shall be liable for any damages arising herefrom.

Library of Congress Cataloging-in-Publication Data

Library of Congress Cataloging-in-Publication Data

The handbook of clinical techniques in pediatric dentistry / edited by Jane A. Soxman.

p. ; cm.

Includes index.

ISBN 978-1-118-79269-8 (pbk.)

I. Soxman, Jane A., editor.

[DNLM: 1. Dental Care for Children—methods. 2. Pediatric Dentistry—methods. 3. Tooth Diseases—therapy. WU 480]

RK63

617.6'45—dc23

2014036985

A catalogue record for this book is available from the British Library.

Wiley also publishes its books in a variety of electronic formats. Some content that appears in print may not be available in electronic books.

Typeset in 8.5/12pt MeridienLTStd by Laserwords Private Limited, Chennai, India

1 2015

Table of contents

- List of Contributors, vii
- Foreword, ix
- Preface, xi
- Acknowledgements, xiii
- 1** Interim Therapeutic Restoration in the Primary Dentition, 1
Jane A. Soxman
- 2** Local Anesthesia for the Pediatric Patient, 5
Jane A. Soxman and Stanley F. Malamed
- 3** Primary Incisor Restoration, 13
Ari Kupietzky
- 4** Primary Molar Adhesive Tooth Restoration, 29
Constance M. Killian and Theodore Croll
- 5** Full Coverage Restoration for Primary Molars, 39
Jane A. Soxman
- 6** Vital Pulp Therapy for Primary Molars, 51
Jane A. Soxman
- 7** Pulpectomy for Primary Teeth, 59
James A. Coll
- 8** Extraction of Primary Dentition, 71
Jane A. Soxman
- 9** Sealants, 77
Jane A. Soxman and Patrice B. Wunsch
- 10** Indirect Pulp Therapy for Young Permanent Molars, 83
Patrice B. Wunsch
- 11** Direct Pulp Therapy for Young Permanent Molars, 93
Patrice B. Wunsch
- 12** Diagnosis and Treatment of Molar–Incisor Hypomineralization, 99
J. Timothy Wright
- 13** Ectopic Eruption of Maxillary First Permanent Molar, 107
Ari Kupietzky and Jane A. Soxman
- 14** Ectopic Eruption of Maxillary Permanent Canines, 121
Jane A. Soxman

- 15 Infraocclusion of Mandibular Primary Molars, 127
Jane A. Soxman
- 16 Space Maintenance, 133
Jane A. Soxman
- 17 Pulpal Treatment in Young Permanent Incisors Following Traumatic Injuries, 143
Joe H. Camp
- 18 Reattachment of Permanent Incisor Enamel Fragments, 157
Jane A. Soxman
- 19 Non-Nutritive Sucking and Parafunctional Habits, 163
Jane A. Soxman
- 20 Behavior Guidance, 173
Jane A. Soxman
- Index, 183

List of contributors

Editor

Jane A. Soxman, RN, DDS

Diplomate of the American Board of Pediatric Dentistry, Private Practice Pediatric Dentistry, Allison Park, PA, USA
Division of Dental Medicine, Allegheny General Hospital, General Practice Residency Seminar and Clinical Instructor, Pittsburgh, PA, USA
Veterans Affairs Pittsburgh Health Care System, General Practice Dental Residency Educational Consultant, Pittsburgh, PA, USA
Adjunct Assistant Professor of Pediatric Dentistry, Department of Pediatric Dentistry, University of Pittsburgh School of Dental Medicine, Pittsburgh, PA, USA

Contributors

Joe H. Camp DDS, MSD

Private Practice Endodontics, Charlotte, NC, USA
Adjunct Professor, Department of Endodontics, University of North Carolina School of Dentistry, Chapel Hill, NC, USA

James A. Coll DMD, MS

Diplomate of the American Board of Pediatric Dentistry, Private Practice Pediatric Dentistry 1974-2013, York, PA, USA
Clinical Professor, University of Maryland Dental School, Department of Pediatric Dentistry, Baltimore, MD, USA

Theodore P. Croll, DDS

Diplomate of the American Board of Pediatric Dentistry, Private Practice Pediatric Dentistry, Doylestown, PA, USA
Affiliate Professor, Department of Pediatric Dentistry, University of Washington School of Dentistry, Seattle, WA, USA
Adjunct Professor, Pediatric Dentistry, University of Texas Health Science Center at San Antonio Dental School, San Antonio, TX, USA

Constance M. Killian, DMD

Diplomate of the American Board of Pediatric Dentistry, Private Practice Pediatric Dentistry, Doylestown, PA, USA
Adjunct Associate Professor of Pediatric Dentistry, University of Pennsylvania School of Dental Medicine, Philadelphia, PA, USA

Ari Kupietzky, DMD, MSc

Diplomate of the American Board of Pediatric Dentistry, Visiting Professor, Department of Pediatric Dentistry, Rutgers School of Dental Medicine, Rutgers, The State University of New Jersey, Newark, New Jersey, USA
Clinical Instructor, Department of Pediatric Dentistry, The Hebrew University–Hadassah School Of Dental Medicine, Jerusalem, Israel

Stanley F. Malamed, DDS

Dentist Anesthesiologist, Emeritus Professor of Dentistry, Ostrow School of Dentistry of USC, Los Angeles, CA, USA

William F. Waggoner, DDS, MS

Diplomate of the American Board of Pediatric Dentistry, Private Practice, Las Vegas, NV, USA

J. Timothy Wright, DDS, MS

Diplomate of the American Board of Pediatric Dentistry, Bowden Distinguished Professor and Chair, Department of Pediatric Dentistry, University of North Carolina, Chapel Hill, NC, USA

Patrice Barsamian Wunsch, DDS, MS

Diplomate of the American Board of Pediatric Dentistry, Director, Advanced Education in Pediatric Dentistry, Virginia Commonwealth University, Richmond, VA, USA

Foreword

This *Handbook of Clinical Techniques in Pediatric Dentistry* is targeted primarily to general dentists and young pediatric dentists who would like a simplified, clinically relevant, step-by-step approach to delivering effective and efficient dental care to children of all ages. Why is a handbook such as this necessary or desirable? The answer lies primarily within the following set of facts and numbers. (i) Dental disease is the most common chronic illness in children in the United States. (ii) According to various government reports, between 25% and 44% of children will have a cavity by the time they enter kindergarten. (iii) By the age of 19 years, over two-thirds of children will have experienced tooth decay in permanent teeth. (iv) There are an estimated 74 million children between the ages of 1 and 17 years in the United States. (v) There are only 6400 active pediatric dentists in the United States, so there is virtually no possibility that 6400 practitioners could provide for the dental needs of 74 million children. (vi) There are approximately 165,000 active general dentists in the United States, many of whom see children in their practice, but might increase the numbers they see, if they felt more confident in the administration of pediatric dental techniques and skills. So considering these facts, not only is it desirable those general dental practitioners see more of the children, but also it is a logistical necessity, in order that many more children may receive appropriate oral health care.

Dr. Soxman, along with many well-known, experienced practitioners, academicians, and other related specialists, has created a well-illustrated, simplified, step-by-step approach to the most common clinical challenges and procedures that a practitioner treating

children needs to know. One of the aspects of this handbook that sets it apart from many pediatric dental textbooks is the number of chapters written, or contributed to, by pediatric practitioners who have over 20–25 years of private practice dental experience, as opposed to chapters written in most textbooks by those with a primary academic background. While this book is academically solid, its strength is in the clinical relevance and presentation of the various techniques from those who have accomplished them hundreds and thousands of times.

This handbook should become a strong clinical reference manual for those dentists who wish to improve their skills, efficiency, and confidence in treating children. Most importantly, it can help them provide an effective dental home for some small part of those 74 million children who deserve the best oral health care that can be made possible.

Congratulations to Dr. Soxman for embarking on this publishing endeavor and for acquiring such a great group of experienced, knowledgeable contributors. Over the years, I have come to know nearly all nine of the contributors in various capacities, and I know that their labors in creating this handbook is because each has given a professional lifetime of dedication to serving children. In addition, I believe that children will be well served by the practitioners who read and implement the information in this *Handbook of Clinical Techniques in Pediatric Dentistry!*

William F. Waggoner, DDS, MS, FAAPD, FACD
Las Vegas, NV

Preface

While speaking at an annual session of the American Dental Association, Wiley Blackwell publications requested that I meet with a commissioning editor. He inquired whether I had ever considered writing a book and if so, on what subject. My response was without hesitation. Over the past 20 plus years as a national speaker in continuing education and as a seminar instructor for general practice residents, I recalled the myriad of questions asked. I had often thought that a book on clinical techniques would provide much needed guidelines and directions for dental students, general dentists, and graduate general practice and pediatric dental residents. This book would include step-by-step descriptions, augmented with clinical photographs of routinely performed procedures and evidence-based recommendations.

The *Handbook of Clinical Techniques in Pediatric Dentistry* provides the clinician with an increased level of expertise and skills for timely identification and intervention for various presentations in the developing dentition. It also clearly describes procedures for treatment in the primary and young permanent dentitions. The most commonly encountered treatment needs are discussed, with the goal of increasing clinician and staff confidence, while decreasing chair time and stress. What you will learn and incorporate into your practice will be of tremendous benefit to you, your staff, and the children for whom you care.

Jane A. Soxman, RN, DDS
Allison Park, Pennsylvania, USA

Acknowledgments

I wish to thank all contributors for accepting my request to donate and share their expertise despite their already exceedingly busy professional lives. I am so grateful for their exceptional contributions and cooperation in writing and co-authoring chapters that have wholly fulfilled my vision.

I thank Miss Beth, my assistant of 22 years, for her dedication, gentle spirit, and support as together we have treated thousands of children. Her patience and determination, taking photographs over and over again,

striving to capture the best possible facial or intraoral photograph, even with a reluctant or uncooperative child, are responsible for the clinical photographs. She sat beside me for hours on end during the evening and on weekends, reviewing clinical photographs, sizing them to specification, and revising and retyping legends.

In honor of her devotion to the children and to me, the *Handbook of Clinical Techniques in Pediatric Dentistry* is dedicated to Beth Ann Sutter.

Jane A. Soxman, RN, DDS

About the companion website

This book is accompanied by a companion website:

www.wiley.com/go/soxman/handbook

The website includes videos demonstrating some procedures described in the book.

1

Interim therapeutic restoration in the primary dentition

Jane A. Soxman

Interim therapeutic restoration (ITR) may be the procedure of choice for restoration in uncooperative children, young children, or children with special needs when definitive restorative treatment cannot be performed. ITR avoids the use of sedation or general anesthesia until a child is old enough to cooperate or curtails caries progression and/or emergency care, while awaiting availability of sedation or general anesthesia services (Kateeb *et al.*, 2013).

Indications

Alternative/atraumatic restorative technique (ART) is performed with similar indications and techniques as ITR; however, ART restorations have been traditionally placed where people have limited ability to obtain dental treatment and without a plan for future replacement (American Academy of Pediatric Dentistry, 2014a; AAPD Reference Manual, pp. 48–49). ART was first introduced 26 years ago in Tanzania and has developed into an accepted protocol for caries management to improve quality and access to dental treatment over the world (Frencken *et al.*, 2012). Mahoney *et al.* (2008) state that ART should be used only when the restoration can be periodically evaluated to insure integrity of the restoration.

ITR is minimally invasive and includes only asymptomatic primary incisors or molars with lesions confined to dentin with sound enamel margins, along with a

plan for future follow-up and final restoration (Amini & Casamassimo, 2012). Two surfaces may be treated, but the use of a matrix and rubber dam increases the complexity of the procedure, and the longevity of a multisurface glass ionomer restoration is reduced compared to a one-surface restoration. Survival rates over the first 2 years of 93% for single surface and 62% for multiple surface primary molar restorations are reported (de Amorim *et al.*, 2012). Carious lesions ideal for ITR are mesial caries on maxillary incisors, facial caries, cervical caries, and occlusal caries in the primary dentition (Figures 1.1–1.4).

Stepwise excavation of open carious lesions is another indication for ITR (American Academy of Pediatric Dentistry, 2014b; AAPD Reference Manual, pp. 48–49). Partial removal of carious dentin avoids pulpotomy. Microbial counts of bacteria are reduced under the restoration with or without complete removal of the carious dentin (Lula *et al.*, 2009).

Procedure

The procedure can be performed in 5 min or less without the use of local anesthesia or a rubber dam. The nonpainful carious dentin is removed with a large round bur in a slow-speed rotary instrument (Figure 1.5). A spoon excavator may also be used, but cautiously, due to the risk of unroofing the pulp chamber with a large mass of carious dentin (Figure 1.6). A dri-angle or

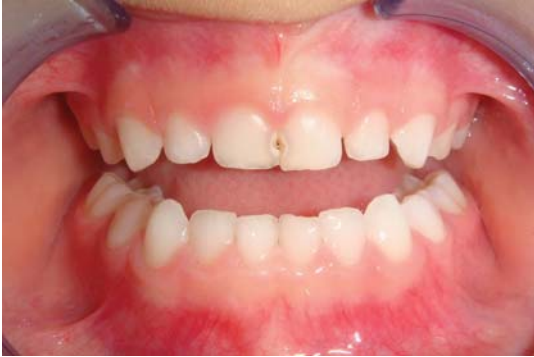

Figure 1.1 Mesial caries maxillary primary central incisors.

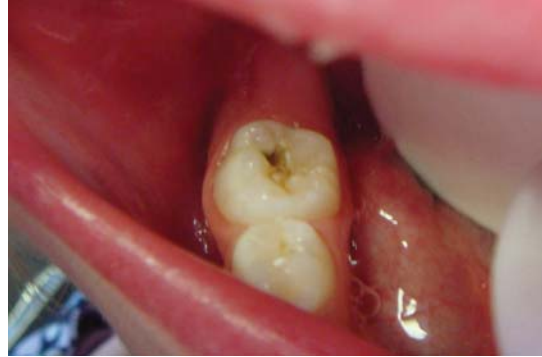

Figure 1.4 Occlusal caries mandibular right second primary molar.

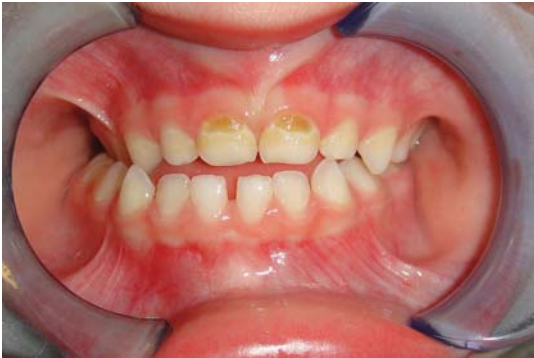

Figure 1.2 Facial caries maxillary primary central incisors.

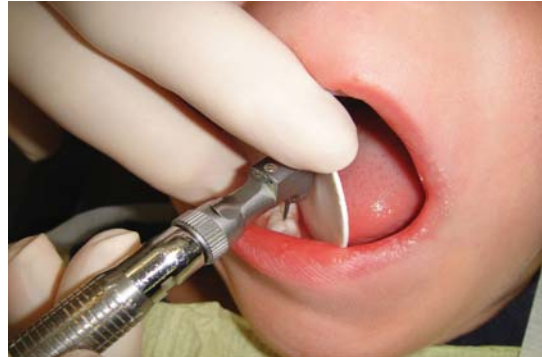

Figure 1.5 Slow speed with round bur to remove superficial caries.

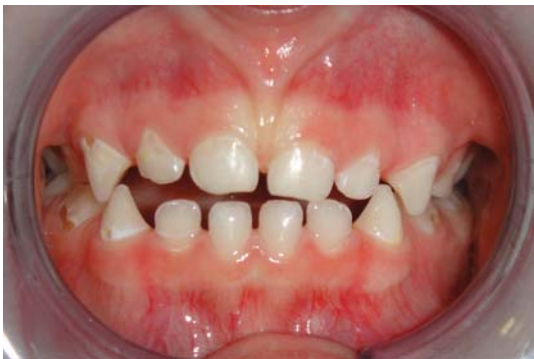

Figure 1.3 Cervical caries primary canines and first primary molars.

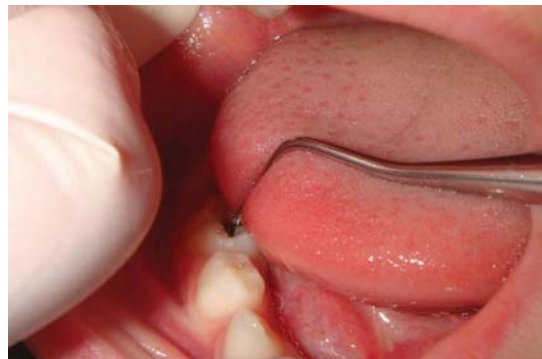

Figure 1.6 Spoon excavator to remove superficial caries.

dri-aid is used to cover Stensen's duct and provide cheek retraction for a posterior restoration. When restoring a mandibular primary molar, a second dri-angle/dri-aid may be placed on the lingual to retract the tongue, while placing the glass ionomer restoration (Figure 1.7).

Materials

A high-viscosity glass ionomer is the material of choice for restoration owing to the ease of use and

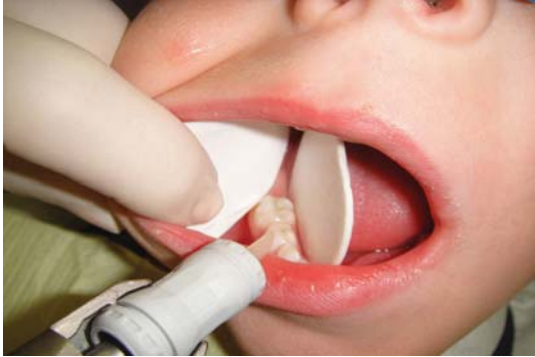

Figure 1.7 Dri-angles to retract cheek and tongue while placing glass ionomer.

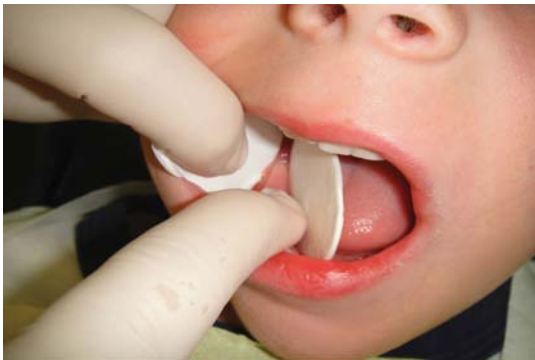

Figure 1.8 Clinician's finger compressing glass ionomer.

physical properties. Glass ionomer is fluoride releasing, esthetically acceptable, tolerates some moisture contamination, chemically bonds to the tooth, and chemically cures. Application with the use of preloaded capsules in a capsule applicator or gun significantly reduces working time. After placement in the preparation,

finger pressure may be used to compress the material, removing occlusal contacts to increase longevity of the restoration (Figure 1.8). Finishing is not necessary. Select a material with a fast setting time to insure the procedure is completed in the shortest possible chair time.

References

- American Academy of Pediatric Dentistry. (2014a) Policy on interim therapeutic restorations (ITR). *Pediatric Dentistry*, **36** (special issue), 48–49.
- American Academy of Pediatric Dentistry. (2014b) Guideline on restorative dentistry. *Pediatric Dentistry*, **36** (special issue), 230–241.
- Amini, H. & Casamassimo, P. (2012) Early childhood caries managed with interim therapeutic restorations. In: Moursi, A.M. (ed.), *Clinical Cases in Pediatric Dentistry*. Wiley-Blackwell, Oxford, UK, pp. 190–197.
- de Amorim, R.G., Leal, S.C. & Frencken, J.E. (2012) Survival of atraumatic restorative treatment (ART) sealants and restorations: a meta-analysis. *Clinical Oral Investigation*, **16** (2), 429–441.
- Frencken, J.E., Leal, S.C. & Navarro, M.F. (2012) Twenty-five year atraumatic restorative treatment (ART) approach: a comprehensive overview. *Clinical Oral Investigation*, **16** (5), 1337–1346.
- Kateeb, E., Warren, J., Damiano, P. *et al.* (2013) Atraumatic restorative treatment (ART) in pediatric dentistry residency programs: a survey of program directors. *Pediatric Dentistry*, **35**, 500–505.
- Lula, E.C., Monteiro-Neto, V., Alves, C.M. & Ribeiro, C.C. (2009) Microbiological analysis after complete or partial removal of carious dentin in primary teeth: a randomized clinical trial. *Caries Research*, **43** (5), 354–358.
- Mahoney, E., Kilpatrick, N. & Johnston, T. (2008) Restorative paediatric dentistry. In: Cameron, A.C. & Widmer, R.P. (eds), *Handbook of Pediatric Dentistry*, 3rd edn. Mosby, London, pp. 71–93.

2

Local anesthesia for the pediatric patient

Jane A. Soxman and Stanley F. Malamed

The number one reason children give for fear of going to the dentist is the fear of injection (AlShareed, 2011). Parents/guardians should be told not to discuss the injection before an appointment for restoration or extraction with the child. With the use of topical anesthetic, distraction, and good injection technique, most children are unaware of receiving the injection. Anxiety is the biggest predictor of poor pain control (Nakai *et al.*, 2000). Before beginning any procedure, note red splotches, rash, or evidence of trauma to rule out allergic reaction to the local anesthetic or responsibility of the practice for an injury that previously occurred. Any unusual finding is immediately shown to the parent/guardian and documented in the chart. Anxiety may cause a diffuse rash (Figure 2.1). An allergic reaction to medication being taken may also present as a rash (Figure 2.2).

The local anesthetic may be described as to “sleepy juice.” The child is told that his/her tooth will go to sleep for a little while but will “awaken” later, just as the child awakens each morning. The dentist or a staff member should monitor the child after the injection, while awaiting effective anesthesia. The rubber dam is referred to as a blanket to cover the sleeping tooth. After the rubber dam is removed, the child is told that the tooth, lip, and/or tongue will soon awaken. A time frame described in hours for a return to normal sensation, when the tooth will feel exactly the same as before taking the nap, is meaningless to a child. A concrete time, such as lunchtime or dinnertime, may be better word choices for the child to understand.

Infiltration in the mandible results in lip anesthesia, which can be distressing and compounds the anesthetic sensation. If possible, begin with buccal infiltration in the maxilla for a primary molar to desensitize the child. This approach will help him/her to become accustomed to the sensation created by the local anesthesia before introducing more profound mandibular anesthesia, including the lower lip and/or tongue. Parents/guardians are informed before administering the local anesthetic that the feeling of being numb after the procedure is completed is often more distressing for the child than the injection or procedure. This exaggerated response is usually seen immediately after the rubber dam is removed (Figure 2.3). The young child complains, “it hurts.” A sticker, reminding the child not to bite or suck on his/her lip/cheek or tongue, should be placed on the child’s shirt on the same side as the anesthetized lip and/or tongue. Hot beverages should be avoided. These instructions are given with the parent/guardian present. A photograph of the appearance of a lip after chewing or biting during anesthesia can be shown to the parent/guardian and, if old enough to understand, also the child (Figure 2.4). If damage to the lip or oral mucosa occurs, Vitamin E applied to the area may soothe and hasten healing. The patient’s chart should include the dosage of local anesthetic administered in milligrams, the site of injection, and the type of injection(s) such as infiltration, intraosseous, or block, along with needle gauge and length (extra short or short). The patient’s reaction to

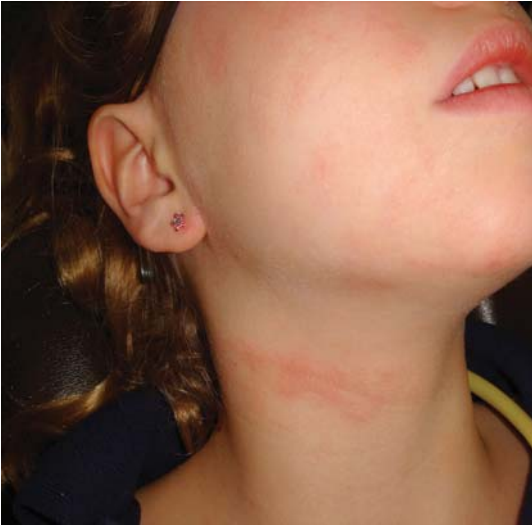

Figure 2.1 Diffuse rash due to anxiety.

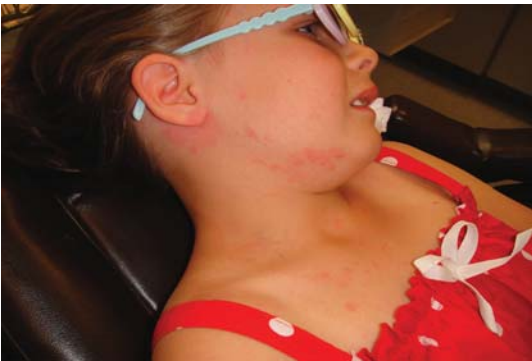

Figure 2.2 Rash due to suspected allergic reaction to penicillin.

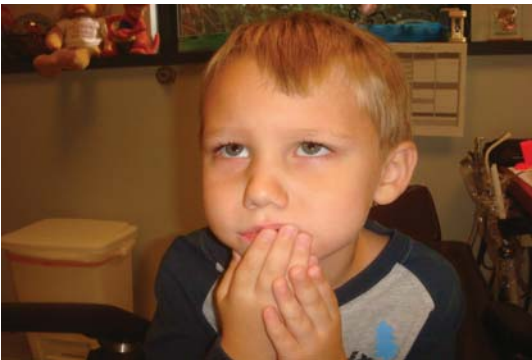

Figure 2.3 Child immediately after procedure distressed by the numb sensation.

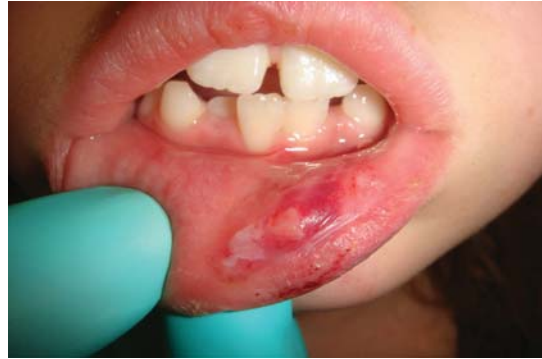

Figure 2.4 Lip swelling and ecchymosis due to lip chewing.

the injection and post-injection instructions given to the parent/guardian and patient should also be included in the chart (American Academy of Pediatric Dentistry, 2014).

Local anesthetic choice

Bupivacaine, prilocaine, articaine, lidocaine, and mepivacaine are injectable amide local anesthetics approved for pediatric use. Bupivacaine is not recommended for a young child or for some special needs patients with mental or physical disabilities because of prolonged anesthesia with risks of self-inflicted soft tissue injury. One of prilocaine's end products causes the formation of methemoglobin, which decreases the ability of hemoglobin to carry oxygen (American Academy of Pediatric Dentistry, 2014). Prilocaine should be used cautiously or avoided in children with oxygen transport diseases such as sickle cell disorder, anemia, respiratory disease, cardiovascular disease, or abnormal hemoglobin. Gutenberg *et al.* found that administration of 4% prilocaine without a vasoconstrictor with a dose of 5 mg/kg resulted in significantly elevated levels of methemoglobin. Because peak methemoglobin blood levels are reached 1 h after injection, children should be observed for at least 1 h after a procedure using 4% prilocaine as the local anesthetic. Gutenberg *et al.* (2013) did not find increased methemoglobin levels using 2% lidocaine with 1:100,000 epinephrine. Two percent lidocaine with 1:100,000 epinephrine is most often used for pediatric patients, but 4% articaine has gained some popularity. Prolonged numbness with 4% solutions may be distressing to children younger than

7 years, with 40% reporting numbness after 3 h and 11% after 5 h. Soft tissue injury, particularly of the lip, is more likely to occur (Adewumi *et al.*, 2008). The use of 1:200,000 epinephrine instead of the 1:100,000 concentration with the 4% articaine should not change the efficacy and may be preferable for the pediatric patient. A study by Meechan did not find effectiveness of buccal infiltration in the mandibular first molar area to be influenced by the concentration of the epinephrine solution (Meechan, 2011). The efficacy of articaine 4% has been reported to be more effective in obtaining good anesthesia in infected sites and so may be a good local anesthetic choice for extraction due to abscess (Kurtzman, 2014). The low pH of the epinephrine in both articaine and lidocaine may cause a burning sensation. Three percent mepivacaine, pH 4.5–6.8, does not contain epinephrine and may reduce injection discomfort (Friedman, 2000). Because mepivacaine does not contain a vasoconstrictor, rapid systemic uptake can occur. The maximum dosage of 3% plain mepivacaine, 4.4 mg/kg or 2.0 mg/lb, should be carefully calculated (American Academy of Pediatric Dentistry, 2014). Three percent mepivacaine may offer a good alternative for single quadrant occlusal or interproximal restorations in the primary dentition with the shorter duration of those procedures and soft tissue anesthesia.

Dosage

Local anesthetic overdoses were found in 41% of malpractice insurance claims involving anesthesia for pediatric dental patients. Of those claims, 43% occurred when local anesthetic was the only drug administered (Chicka *et al.*, 2012). The cortical plate of bone is thin, and the bone is more vascular with rapid uptake of local anesthesia in the pediatric patient. The use of a vasoconstrictor, epinephrine, reduces the risk of rapid systemic absorption and overdose. A vasopressor-containing local anesthetic is recommended for use when more than one quadrant is being restored in the same visit (American Academy of Pediatric Dentistry, 2014).

Dosage is based on a child's weight and should never exceed the listed maximum dosage. The maximum dosage of 4% articaine with 1:100,000 epinephrine recommended is 7.0 mg/kg or 3.2 mg/lb (Webb *et al.*,

2012; Widmer *et al.*, 2008; American Academy of Pediatric Dentistry, 2014). The maximum dosage of 2% lidocaine with 1:100,000 epinephrine is 4.4 mg/kg or 2.0 mg/lb (Webb *et al.*, 2012; American Academy of Pediatric Dentistry, 2014). Four percent solutions contain 40 mg/mL of drug, and 2% solutions contain 20 mg/mL. One cartridge of 4% articaine contains 68 mg. Although the cartridge label reads 1.7 mL, the actual volume is ~1.76 mL. Therefore, it is most prudent when determining maximum dosage to employ 1.8 mL. The label change was made at the request of the Food and Drug Administration (FDA) when articaine (Septocaine) was introduced in 2000. The volume of 1.76 mL is consistent for all local anesthetic cartridges, and one cartridge of 2% lidocaine contains 36 mg. Most procedures for primary molars are performed with infiltration of one-third to two-thirds of a cartridge of 2% lidocaine with 1:100,000 epinephrine. Vital pulp therapy in the mandible may require inferior alveolar nerve (IAN) block along with buccal infiltration using two-thirds to a full cartridge of 2% lidocaine with 1:100,000 epinephrine.

Injection discomfort

Needle penetration is related to the discomfort of intraoral injections (Meechan *et al.*, 2005). Lidocaine-based (amide) topical anesthetics are rapidly absorbed into systemic circulation and can contribute to drug overdose. They should be applied sparingly to tissue dried with gauze and limited to the area of needle penetration (Figure 2.5a). Benzocaine-based ester topical, with concentration up to 20%, is poorly absorbed into the circulatory system with minimal chance of overdose but also for use only in small amounts (Kohli *et al.*, 2000). Topical anesthetic should remain in place for at least 2 min and is more effective on mucosa than attached gingiva. A small piece of gauze is placed over the topical to avoid spreading or swallowing of the anesthetic; the gauze should always be visible (Figure 2.5b).

Needles for dental injection are manufactured as follows: long (32 mm), short (22 mm), and extra short (10 mm), with gauges that range from 23 to 30. There is no significant difference in pain experienced during tissue penetration with 25-, 27-, or 30-gauge needles for maxillary injections or with a 25- or 27-gauge needle for mandibular injections (Flanagan *et al.*, 2007).

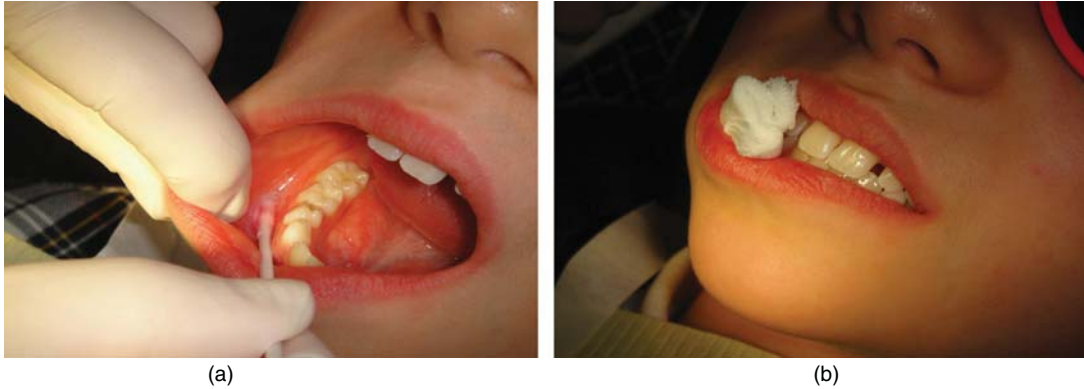

Figure 2.5 (a) Placing topical anesthetic for long buccal injection. (b) 2 × 2 gauze after placement of topical anesthetic.

The benefit of wider-gauge needle is less likelihood of breakage or deflection and less pressure necessary for aspiration. More pressure is necessary to inject local anesthetic through a 30-gauge needle, possibly causing hydrostatic damage and increasing discomfort during injection (Kurtzman, 2014). Injection may be performed with a short needle if the thickness of the soft tissue is less than 20 mm (American Academy of Pediatric Dentistry, 2014). A 27-gauge short needle is preferable to a 30-gauge needle for inferior alveolar block in a child. The orientation of the bevel of the 27-gauge needle either toward or away from the mandibular ramus does not affect achievement of pulpal anesthesia (Steinkruger *et al.*, 2006). Warming local anesthetic solution from room temperature to body temperature before injection has not been shown to decrease discomfort (Ram *et al.*, 2002). The low pH between 2.9 and 4.4 may contribute to pain during injection and delay onset of anesthesia. Buffering the local anesthetic, bringing it to a more physiologic pH by alkalizing the anesthetic directly in the cartridge just before the injection, has been shown to reduce injection discomfort and reduce onset time (Malamed *et al.*, 2013).

Inferior alveolar nerve block

The highest incidence of intravascular injection has been reported to occur with the IAN block. A 27-gauge short needle is recommended for IAN. The long needle

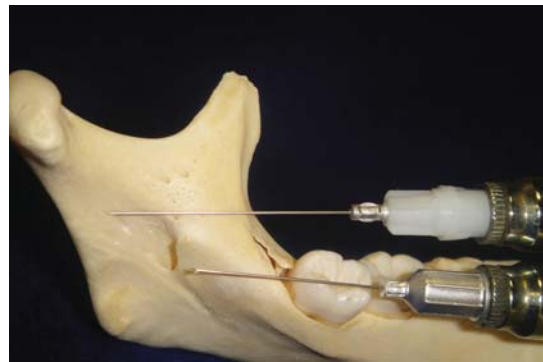


Figure 2.6 Comparison of 27-gauge long needle and 27-gauge short needle for inferior alveolar nerve block to demonstrate preferable short length in mandible of 8-year-old child.

may increase the risk of puncture of the venous plexus or artery with increased chance of deflection or breakage because of unexpected strong avoidance behavior (Figure 2.6). Aspiration should be performed before and repeatedly during the injection to avoid injecting too rapidly and intravascular injection (Malamed, 2011). The most influential factor to prevent overdose is the rate of injection. Sixty seconds to inject a full cartridge is consistently recommended in the literature (Webb *et al.*, 2012). The mandibular foramen is below the occlusal plane in the primary dentition and level with the occlusal plane by 8.5 years of age (Figure 2.7). With growth, the vertical height of the ramus increases, so the needle is moved upward for insertion. With a short face and for older patients, the needle insertion is further from the occlusal plane than in long-face or

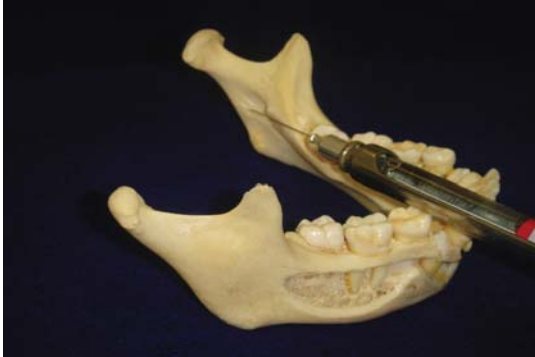

Figure 2.7 Mandible of 8-year-old child showing level of inferior alveolar foramen with syringe level to occlusal plane.

younger patients. The anteroposterior position of the mandibular foramen is one-half to two-thirds the width

of the ramus, measured from the anterior border (Epars *et al.*, 2013). Injecting anesthetic below the mandibular foramen is often the cause of inadequate anesthesia (Malamed, 2011).

For IAN block, the operator places his or her thumb intraorally on the coronoid notch, which is the deepest depression on the anterior border of the ramus, and the index finger on the posterior border of the ramus. The thumb and index finger may be reversed according to operator preference. The barrel of the syringe is at the opposite corner of mouth, and the syringe is parallel with the occlusal plane at an appropriate level for the patient's age. The local anesthetic is injected two-thirds of the distance between the thumb and index finger (Figure 2.8a, 2.8b, 2.8c, and 2.8d).

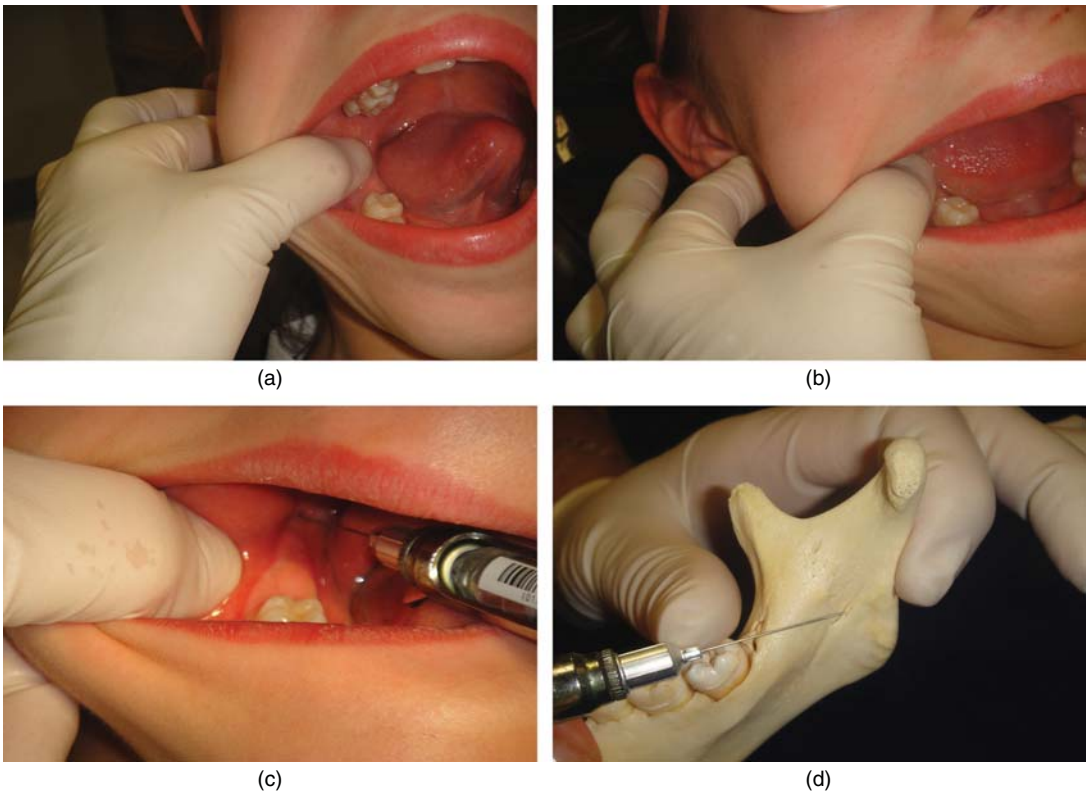


Figure 2.8 (a) Technique for administering inferior alveolar nerve block anesthesia with operator's thumb on the coronoid notch. (b) Operator's index finger on posterior border of ramus. (c) Inferior alveolar nerve block with syringe level to occlusal plane for 8-year-old child. (d) Photograph showing operator's approximate thumb position, accounting for soft tissue with inferior alveolar foramen two-thirds of the distance between the thumb and index finger.

Distraction

Talk to the child and keep the syringe out of his/her sight. Distraction with audiovisual glasses is an effective means to reduce pain with injection of local anesthesia (El-Sharkawi *et al.*, 2012) (Figure 2.9). Telling the child to raise his/her leg during the injection or bite down hard during infiltration or using the air/water syringe to spray water while suctioning at injection site also provides excellent distraction (Figures 2.10–2.12).

The DentalVibe™ (Bing Innovations) may significantly decrease the fear of the “shot” and provide a more comfortable or pain-free injection by overriding the discomfort of tissue distension with vibration. Features include cordless, rechargeable, illumination with fiber optic LED light, and disposable nonlatex tips to provide retraction with pulsed vibration, blocking the neural pain pathway

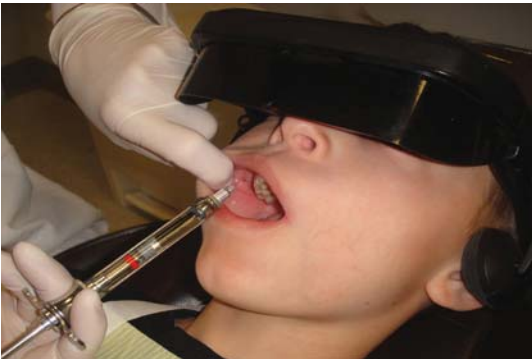

Figure 2.9 Audiovisual glasses for distraction during injection of local anesthesia.

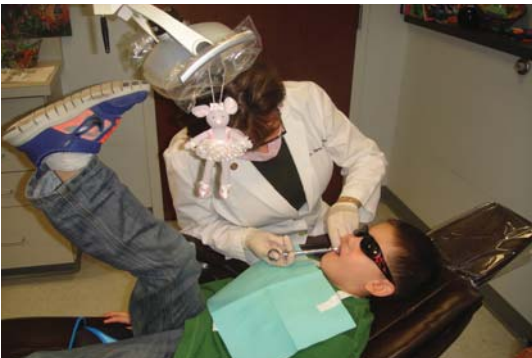

Figure 2.10 Patient raising a leg during injection of local anesthesia.

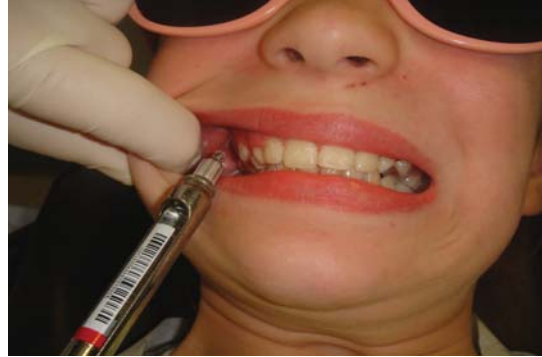

Figure 2.11 Child biting down hard during buccal infiltration in maxilla.

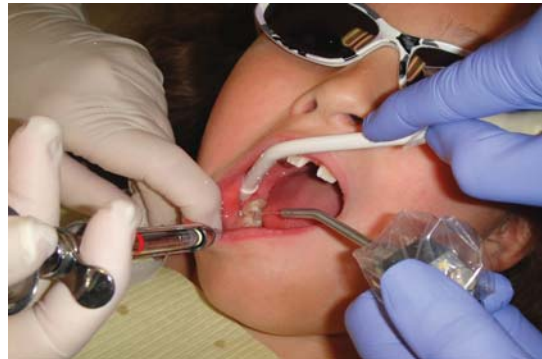

Figure 2.12 Water and suction at injection site while performing buccal infiltration in mandible.

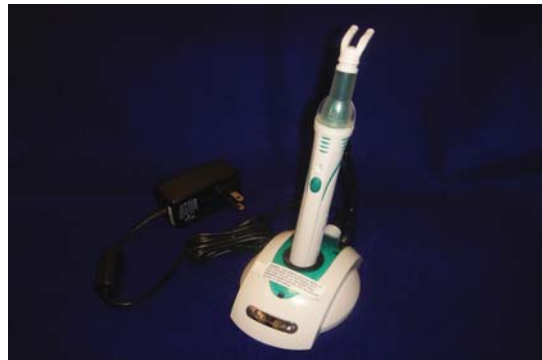

Figure 2.13 DentalVibe™ device.

(Figure 2.13). The first question parents/guardians often ask, after being informed of the need for a restoration, is whether a “shot” will be necessary for the procedure. Explanation and demonstration regarding the use of the

DentalVibe ease the parent/guardian's concern, which typically transfers to the child, resulting in less apprehension or fear at the outset for both. In the author's experience, the device is not well accepted in children younger than 4 years but is very effective to reduce injection anxiety in adolescent patients. Ching *et al.* (2014) found that adolescent patients reported significantly less pain during injections performed using the DentalVibe. Discomfort with palatal injection is significantly reduced with all ages. Tell-show-do precedes the injection. Topical anesthetic is necessary to diminish the discomfort of the needle piercing the tissue. The needle is inserted next to one of the comfort tip prongs (Figures 2.14 and 2.15). Extraction of overretained, extremely mobile primary incisor or primary molar coronal fragments can be performed quickly and virtually painlessly using topical anesthetic, augmented with the DentalVibe placed next to the coronal fragment (Figure 2.16).

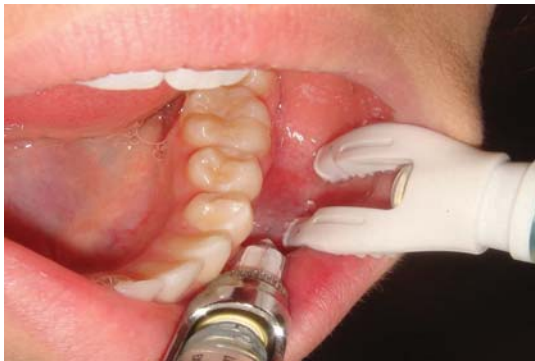

Figure 2.14 DentalVibe™ for buccal infiltration.

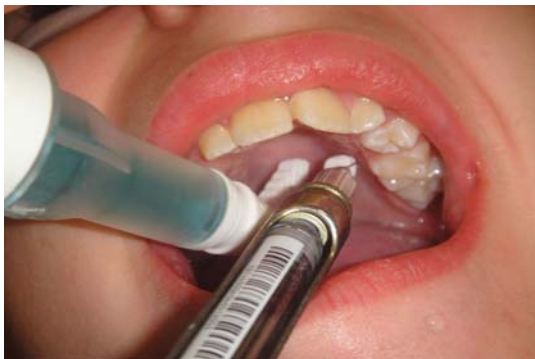

Figure 2.15 DentalVibe™ for palatal injection.

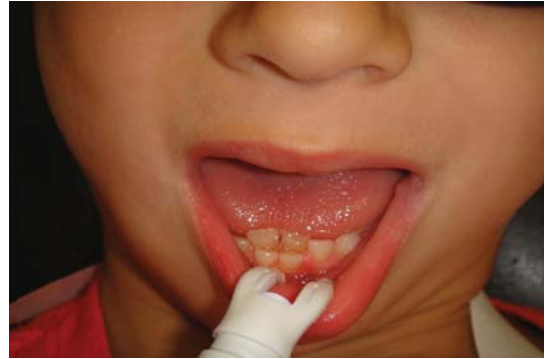

Figure 2.16 DentalVibe™ to augment topical anesthetic for extraction of extremely mobile coronal fragments.

References

- Adewumi, A., Hall, M., Guelmann *et al.* (2008) The incidence of adverse reactions following 4% septocaine (Articaine) in children. *Pediatric Dentistry*, **30**, 424–428.
- AlShareed, M. (2011) Children's perception of their dentists. *European Journal of Dentistry*, **5**, 186–190.
- American Academy of Pediatric Dentistry (2014) Guideline on use of local anesthesia for pediatric dental patients. *Pediatric Dentistry*, **36** (special issue), 197–203.
- Chicka, M.C., Dembo, J.B., Mathu-Muju, K.R. *et al.* (2012) Adverse events during pediatric dental anesthesia and sedation: a review of closed malpractice insurance claims. *Pediatric Dentistry*, **34**, 231–238.
- Ching, D., Finkelman, M. & Loo, C.Y. (2014) Effect of the DentalVibe injection system on pain during local anesthesia in adolescent patients. *Pediatric Dentistry*, **36**, 51–55.
- El-Sharkawi, H.F.A., Housseiny, A.A. & Aly, A.M. (2012) Effectiveness of new distraction technique on pain associated with injection of local anesthesia for children. *Pediatric Dentistry*, **34**, 142–145.
- Epars, J.-F., Mavropoulos, A. & Kiliaridis, S. (2013) Influence of age and vertical facial type on the location of the mandibular foramen. *Pediatric Dentistry*, **35**, 369–373.
- Flanagan, T., Wahl, M.J., Schmitt, M.M. *et al.* (2007) Size doesn't matter: needle gauge and injection pain. *General Dentistry*, **55**, 216–217.
- Friedman, M.J. (2000) New advances in local anesthesia. *Compendium of Continuing Education in Dentistry*, **21**, 432–440.
- Gutenberg, L.L., Chen, J.W. & Trapp, L. (2013) Methemoglobin levels in generally anesthetized pediatric dental patients receiving prilocaine versus lidocaine. *Anesthesia Progress*, **60**, 99–108.
- Kurtzman, G.M. (2014) Improving the local anesthesia experience for our patients. *Dentistry Today*, **33**, 120–126.
- Kohli, K., Ngan, P., Crout, R. *et al.* (2000) A survey of local and topical anesthesia use by pediatric dentists in the United States. *Pediatric Dentistry*, **23**, 265–269.

- Malamed, S.F., Tavana, S. & Falkel, M. (2013) Faster onset and more comfortable injection with alkalinized 2% lidocaine with epinephrine 1:100,000. *Compendium of Continuing Education in Dentistry*, **34**, 10–20.
- Malamed, S.F. (2011) Is the mandibular nerve block passé? *Journal of the American Dental Association Special Supplement*, **142**, 3S–7S.
- Meechan, J.G., Howlett, P.C. & Smith, B.D. (2005) Factors influencing the discomfort of intraoral needle penetration. *Anesthesia Progress*, **52**, 91–94.
- Meechan, J.G. (2011) The use of the mandibular infiltration anesthetic technique in adults. *Journal of the American Dental Association Special Supplement*, **142**, 19S–24S.
- Nakai, Y., Milgrom, P., Mancl, L. *et al.* (2000) Effectiveness of local anesthesia in pediatric dental practice. *Journal of the American Dental Association*, **131**, 1699–1705.
- Ram, D., Hermida, L. & Peretz, B. (2002) A comparison of warmed and room-temperature anesthetic for local anesthesia in children. *Pediatric Dentistry*, **24**, 333–336.
- Steinkruger, G., Nusstein, J., Reader, A. *et al.* (2006) The significance of needle bevel orientation in achieving a successful inferior alveolar nerve block. *Journal of the American Dental Association*, **137**, 1685–1691.
- Webb, M.D., Howell, D.L. & Moursi, A.M. (2012) Intraoperative pain management. In: Moursi, A.M. (ed), *Clinical Cases in Pediatric Dentistry*. Wiley-Blackwell, Oxford, UK, pp. 245–248.
- Widmer, R., McNeil, D.W., McNeil, C.B. *et al.* (2008) Child management. In: Cameron, A.C. & Widmer, R.P. (eds), *Handbook of Pediatric Dentistry*, 3rd edn. Mosby, London, pp. 9–37.

3

Primary incisor restoration

Ari Kupietzky

Early childhood caries (ECC) is usually seen in 18- to 36-month-old children, although it can present even younger. Initially, the maxillary incisors develop a band of dull white demineralization along the gum line that goes undetected by the parents. As the condition progresses, the white lesions develop into cavities that girdle the necks of the teeth in a brown or black collar. Frequently, by the time the child is brought to the dentist, much of the anterior clinical crowns are decayed or lost. In advanced cases, the crowns of the four maxillary incisors may be destroyed completely, leaving decayed brownish-black root stumps (Ripa, 1988). The premature loss or unsightly appearance of grossly decayed primary anterior teeth may be initially of concern to parents; however, as the child matures, it may also affect the patient's self-image. Treatment of these badly decayed teeth remains a challenge for the dentist. The toddler and preschooler, due to their young age and lack of cognitive abilities, are usually very uncooperative for dental treatment, and their behavior plays a big factor in the choice of restoration. Many appear with poor oral hygiene practices, presenting swollen, inflamed, and bleeding gingiva.

Treatment plans advocated for grossly decayed primary anterior teeth include the following: restorations, crowns, or extractions followed by partial dentures. This chapter presents step-by-step procedures for the placement of bonded resin composite strip crowns, full coverage prefabricated crowns, and the anterior esthetic fixed appliance (modified Nance or Groper appliance).

Pretreatment

When a toddler presents to the dental clinic and is diagnosed with ECC, specific counseling and patient preparation must be implemented before any definitive restorative treatment may be commenced. Changing the feeding practices and implementing tooth brushing with fluoridated toothpaste are the first steps in controlling the disease. Once accomplished, definitive restorative treatment modalities can then be mandated.

Oral hygiene

It is advantageous to obtain ideal oral hygiene before commencement of treatment. Parents should be instructed and convinced that they bear partial responsibility for the success of treatment by preparing their child's gingiva for the procedure. Inflamed gingiva (Figure 3.1a) may interfere with proper curing of the restorations, resulting in discolored crowns as a result of excessive bleeding during the curing process. Two to three weeks of proper home care is usually enough to achieve healthy, pink, nonbleeding gingiva that will facilitate restorative treatment (Figure 3.1b).

Indications

Full coronal restoration of carious primary incisors may be indicated when: (i) caries is present on multiple

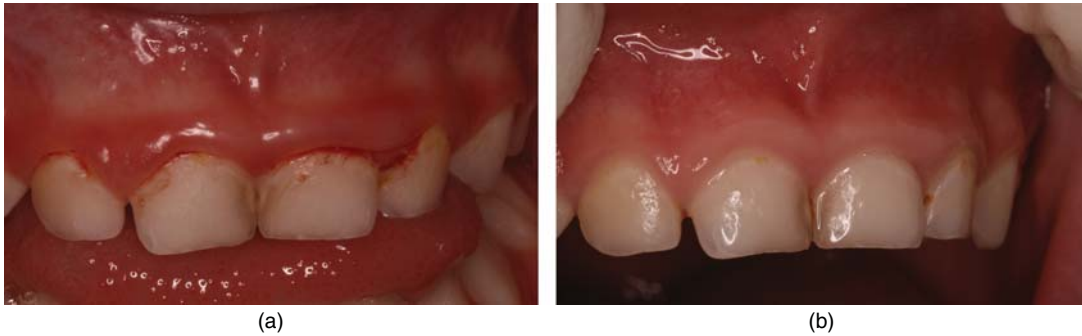


Figure 3.1 (a) The gingival tissue of patients with ECC tends to be inflamed, leading to hemorrhage and compromised aesthetics. Inflamed gingiva may interfere with proper curing of the restorations, resulting in discolored crowns due to excessive bleeding. (b) Three weeks of proper tooth brushing resulted in pink, healthy gingiva, which was necessary to facilitate an aesthetic result.

surfaces, (ii) the incisal edge is involved, (iii) there is extensive cervical decalcification, (iv) pulpal therapy is indicated, (v) caries may be minor, but oral hygiene is very poor (high-risk patients), or (vi) the child's behavior makes moisture control very difficult, creating difficulties in placing Class III restorations (Waggoner, 2002). In addition, the clinician may opt for full coverage in lieu of large Class III restorations: due to the small clinical crown, the relatively large size of the pulp chamber, the close proximity of the pulp horns to the interproximal surfaces, and the thinness of the enamel, repairing interproximal decay in these teeth requires preparations that are conservative in depth with close attention to detail, both to the preparation itself and to the material placement. The technique sensitivity of placing Class III esthetic restorations is very high. Moisture control, hemorrhage control from the gingiva, and retention of the rubber dam are challenges to be overcome to obtain a successful result (Waggoner, 2002); the placement of a full coverage crown will likely be more successful and longer lasting.

Bonded resin composite strip crown

The bonded resin composite strip crown (Figure 3.2) is perhaps the most esthetic of all the restorations available to the clinician for the treatment of severely decayed primary incisors (Webber *et al.*, 1979). However, strip crowns are also the most technique sensitive and may be difficult to place (Croll, 1995). Some simple clinical tips may assist the clinician in achieving an esthetic and superior outcome.

Strip crown preparation

Preparation of the strip crown may be accomplished before the treatment visit. The crown is pierced with a sharp explorer at the mesial or distal incisal angle to create a core vent for the escape of any air bubbles entrapped in the crown (Figure 3.3a). Care must be taken not to damage the proximal seams of the crown. After vent preparation, sharp, curved scissors should be used to trim the crown gingival margins (Figure 3.3b). To ensure sharpness, only task-designated scissors are recommended for this purpose. If there is any doubt of proximal seam integrity, the crown should be discarded. All crowns may be trimmed to an approximate level and can be fine-tuned chair side during treatment.

Isolation and rubber dam placement

The routine use of ligature ties to deflect gingival tissue and retain the rubber dam in place is not suggested, although this is a valid technique used routinely by many dentists with success (Figure 3.4a). Ligature ties at many times may be the cause of bleeding and discomfort for the patient. Their use may inhibit rapid removal and replacement of the rubber dam during treatment. After curing, the removal of the ligatures, which are situated under the hardened restoration, is often difficult and necessitates the otherwise unnecessary subgingival bur finishing for their complete removal. Therefore, with the exception of a case involving severe subgingival carious incisors, it is suggested to use the slit-dam method (Croll, 1985). The application is rapid, and the

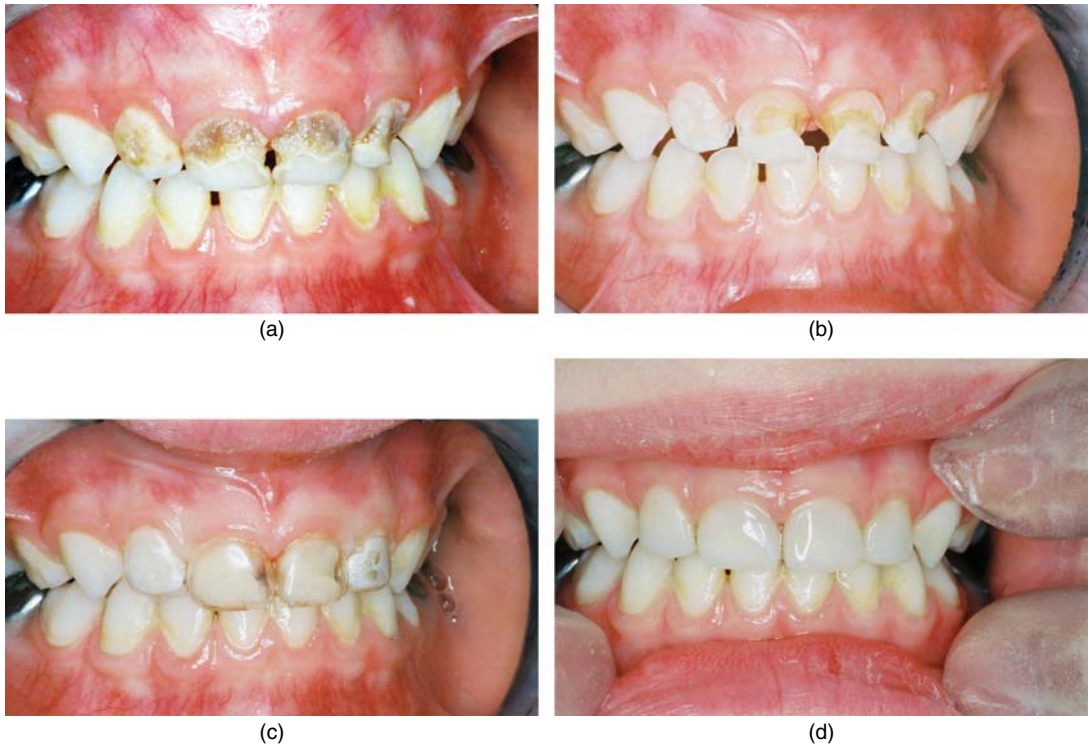

Figure 3.2 (a) The bonded resin composite strip crown is perhaps the most esthetic of all the restorations available to the clinician for the treatment of severely decayed primary incisors. Preoperative view. (b) Caries removal followed by placement of resin-modified glass ionomer cement. Note healthy gingiva. (c) Try-in of crown formers. (d) Postoperative view.

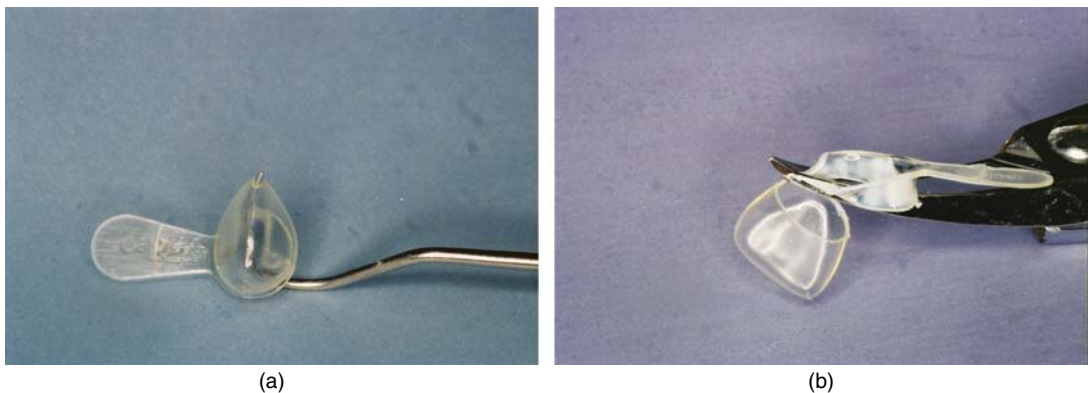


Figure 3.3 (a) The crown is pierced with a sharp explorer at the mesial or distal incisal angle to create a core vent for the escape of any air bubbles entrapped in the crown. (b) Following vent preparation, sharp, curved scissors should be used to trim the crown gingival margins.

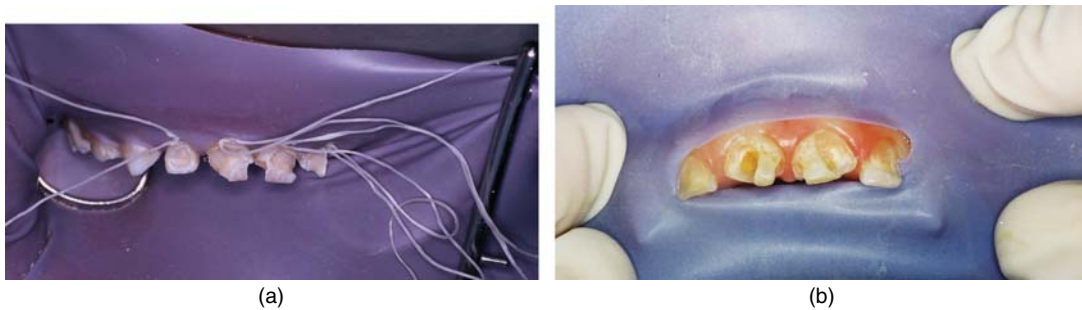


Figure 3.4 (a) The routine use of ligature ties to deflect gingival tissue and retain the rubber dam in place is not suggested, although this is a valid technique used routinely by many dentists with success. (b) It is suggested to use the slit-dam method.

desired teeth are completely available for restorative treatment. Two large holes are punched out 1–2 cm apart and are joined by a scissors cut. The rubber dam may be held in place with digital pressure (Figure 3.4b) or with the use of an elastic band extending between the rubber dam frame and wrapped around the patient's head (Reid *et al.*, 1991). Note that the rubber dam is kept in place only during caries removal; during crown placement, the rubber dam may be removed.

In cases involving severe subgingival carious incisors, it is suggested to use the elastomer method introduced by Psaltis and Kupietzky. Orthodontic elastomeric ligatures are used in place of those for the specific purposes of rubber dam retraction and virtual elimination of the problems of blood and saliva contamination of the operative areas. The success of the technique depends on three key steps as follows:

1. Use a rubber dam punched with four holes of the smallest possible size. This allows the tightest fit, eliminates leakage, and enables the elastomers to retract the dam more effectively around the teeth. It is recommended to space the four holes over the center of each maxillary incisor. Placement too close together will result in stretching of the rubber dam between the teeth and subsequent leakage around the teeth.
2. Place orthodontic elastomers over each incisor after placement of the rubber dam. This is accomplished by threading two strands of floss through each elastomer (Figure 3.5a) and then stretching it over the tooth (Figure 3.5b). If the interproximal areas are sharp or jagged due to caries, the elastomers may tear during this process. If so, slice through the

jagged areas with a thin fissure bur (no. 169 or 1169) to eliminate them. In many cases, the elastomers can be flossed into place by pulling them simultaneously from each tooth's labial and lingual surfaces. It is also sometimes necessary to facilitate this procedure by using a Hollenback carver or a similar hand instrument that can tuck the elastomer well into the gingival sulcus around each tooth (Figure 3.5c). When the elastomers have been properly placed over a well-punched rubber dam, they will almost immediately begin to contract. Consequently, they will also retract the dam and gingival tissues. If any treatment is to be completed in the posterior segments, it is best to proceed and complete them first to give the elastomers more time to continue this retraction process. Once the elastomers are in place, remove the piece of floss from the lingual side, but leave the labial floss in place.

3. Remove the elastomers with the labial floss after the preparation and restoration of the incisors have been completed (Figure 3.5d). It is critical to remove the elastomers, as they will continuously migrate up the conical-shaped root on any of the incisors and, if left in place, can atraumatically and asymptotically "extract" the tooth. Hence, the facial floss provides an easy way to remove the elastomer and serves as a reminder. The proper use of these elastomers eliminates the tedious tying (and removal) of floss ligatures and virtually eliminates any hemorrhaging to ensure a clean field for placement of the strip crowns.

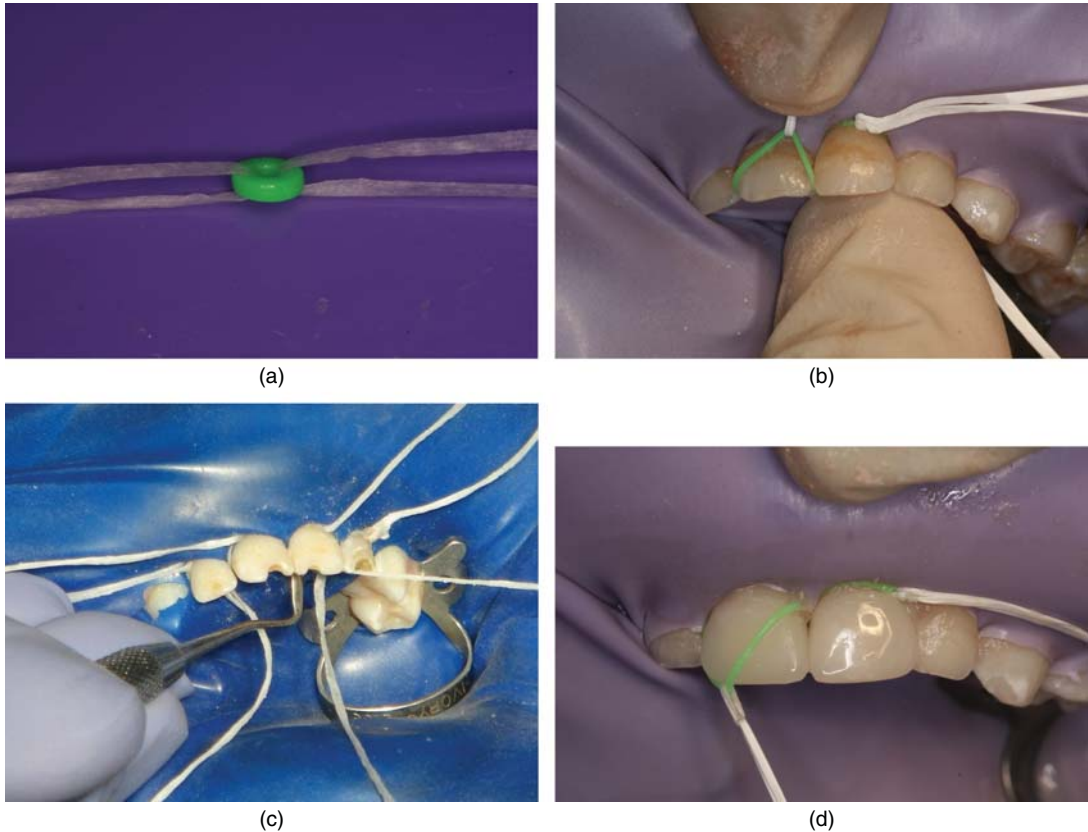


Figure 3.5 (a) Thread two strands of floss through each elastomer. (b) The elastomer is stretched and eased over the tooth with the labial and palatal floss strands. (c) A Hollenback carver or a similar hand instrument may be used to guide the elastomer in place. (d) The elastomers are removed from the facial by using the floss that was left in place.

Caries removal and crown placement—curing and finishing

During caries excavation and removal, extra care should be taken not to damage any gingiva. A stainless steel, round, medium-to-large-sized bur should be used in a low-speed handpiece for this purpose (Figure 3.6a and 3.6b) following initial high-speed tooth reduction. After the application of a resin-modified glass ionomer liner/base for dentin protection (Figure 3.6c and d), all crowns should be fitted and placed (Figure 3.6e). It is suggested to fill and cure each crown individually with unfilled crown forms in place on their respective teeth to ensure proper spacing between restorations (Figure 3.6f). Special care should be taken to carefully remove (before filled crown placement) a collar of cured

bonding agent, which will interfere with proper seating of the crown form if it is left in place (Figure 3.6g). Another cause of failure is overfilling the crown with composite material, resulting in the tearing of the mesial and distal seams of the crown. Minimal filling is highly recommended. Instead of using a rotary instrument to remove the crown form, a sharp, handheld instrument such as a cleoid/discoid carver is recommended to peel off the strip crown shell (Figure 3.6h). This results in only minimal damage to the cured restoration and, consequently, little if any polishing is necessary, and the luster of the labial crown surface is preserved. Care should be taken to apply contra-digital pressure for the patient's benefit.

An excellent result was obtained after the use of the above-described method and is presented in Figure 3.6i and 3.6j.

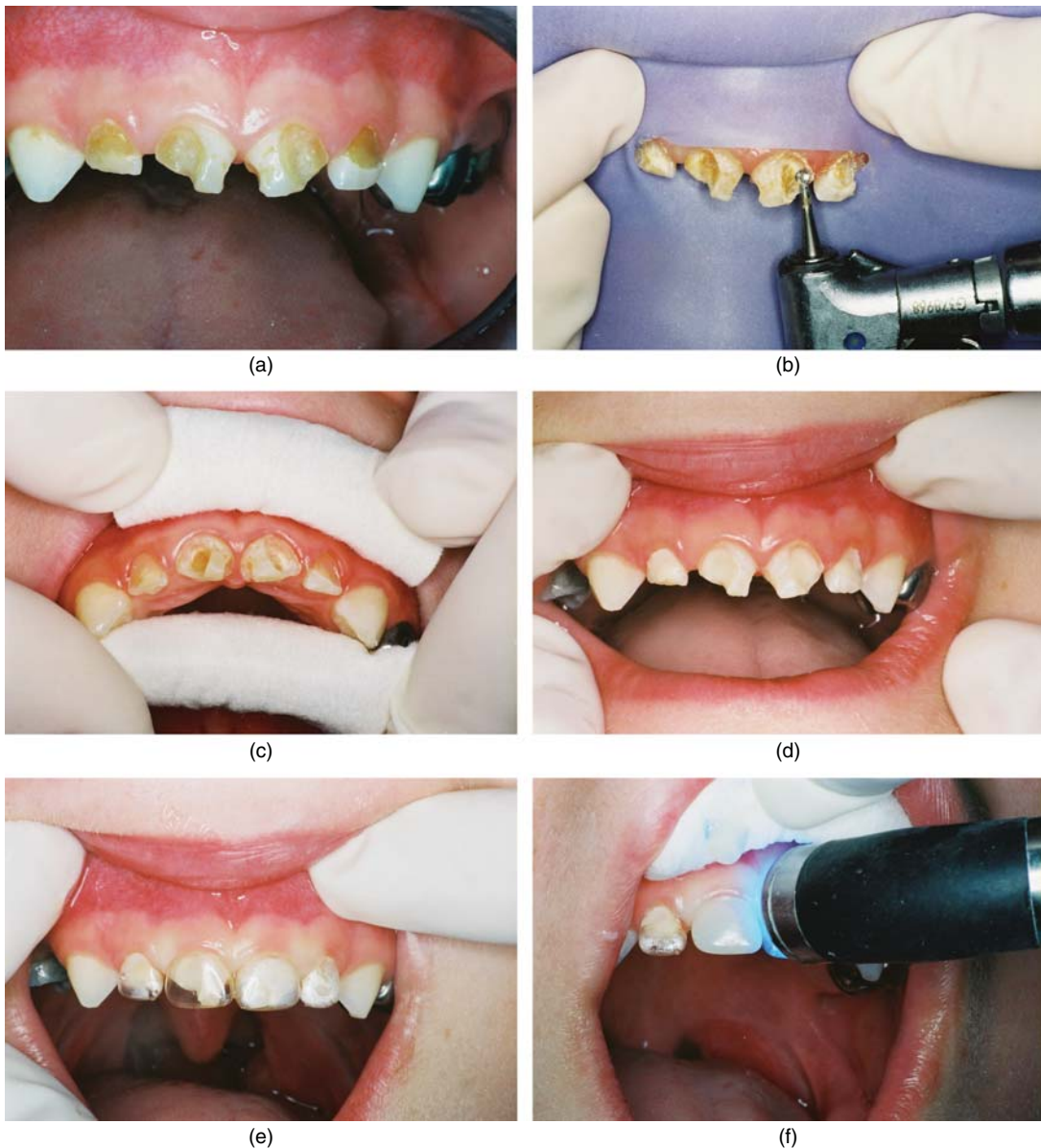


Figure 3.6 (a) Preoperative view. (b) During caries excavation and removal, extra care should be taken not to damage any gingiva. A stainless steel, round, medium-to-large-sized bur should be used in a low-speed handpiece for this purpose. Indirect pulp capping is favorable over pulpal exposure; only infected dentin should be removed. (c) Large cotton rolls are used in place of rubber dam once high-speed and subsequent water spray are not needed anymore. (d) A resin-modified glass ionomer liner/base is applied for dentin protection. (e) All crowns should be fitted and placed to ensure proper spacing. (f) It is suggested to fill and cure each crown individually with unfilled crown forms in place on their respective teeth to ensure proper spacing between restorations. (g) Special care should be taken to carefully remove (before filled crown placement) a collar of cured bonding agent, which will interfere with proper seating of the crown form if it is left in place. (h) A sharp, handheld instrument such as a cleoid/discoid carver is recommended to peel off the strip crown shell. Care should be taken to apply contra-digital pressure for the patient's benefit. (i) An excellent result was obtained following the use of the above-described method. Labial view. (j) Palatal view.

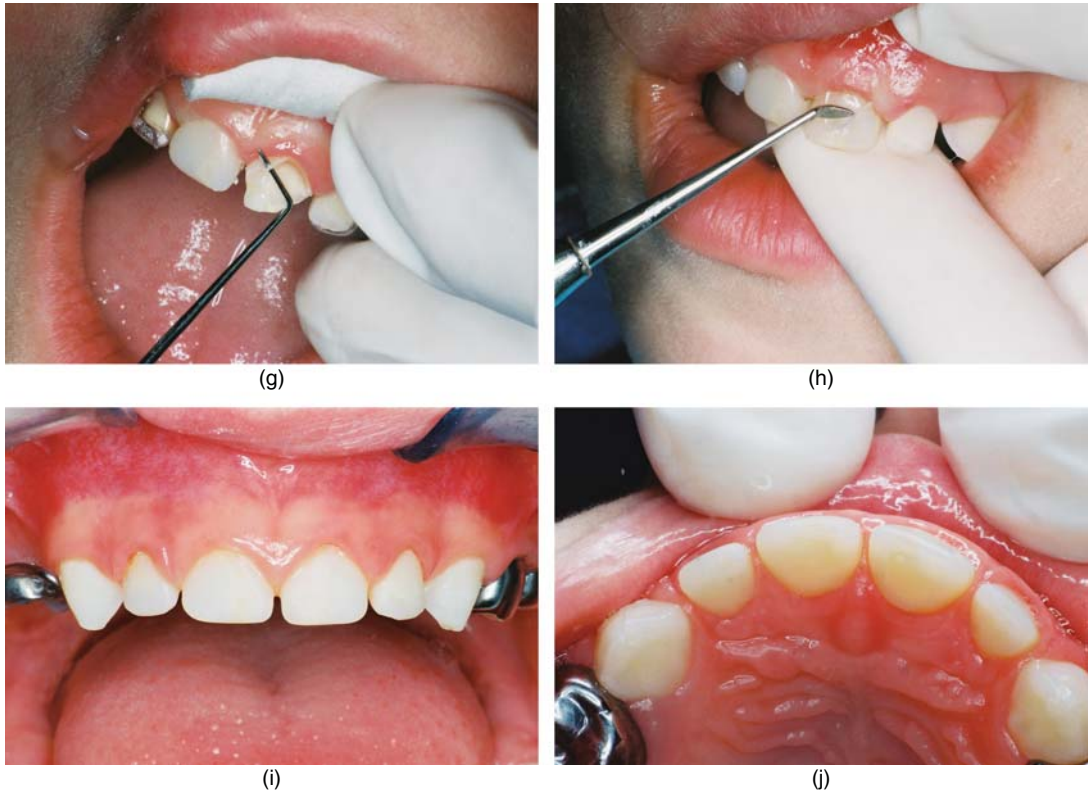


Figure 3.6 (Continued)

The preoperative and postoperative radiographic views are presented in Figure 3.7a and 3.7b.

Full coverage prefabricated crowns

In extreme cases (e.g., severely inflamed gingival tissue, advanced coronal decay, and poor parental compliance), hemorrhage and compromise of the composite aesthetic restoration may be a concern. In these cases, restoration of anterior teeth can be accomplished with preformed anterior crowns (PACs). These restorations can be placed in a single, relatively short appointment, and their aesthetics are not affected by saliva or hemorrhage. There are disadvantages including relative inflexibility, breakage risk under heavy force, significant removal of tooth structure, expense, limited shade choice, and placement difficulty in crowded spaces.

The most common type of PAC is the veneered anterior stainless steel crown (SSC). A recent development has been the introduction of the zirconium anterior crown available from various manufacturers including Cheng Crowns, EZ Pedo, Kinder Crowns, and NuSmile®. The preparation and placement of the PAC are described in Figures 3.8 and 3.9.

The preparation of a PAC is similar to that of a bonded resin composite strip crown with a number of modifications as follows:

1. The crown size should be approximated before commencement of tooth reduction.
2. Crown reduction is more extensive compared to that of a bonded resin composite strip crown: reduce the incisal length of the tooth by approximately 2 mm and open the interproximal contacts. The proximal reduction must be adequate to allow the selected crown to fit passively and should be made parallel to slightly converging incisally. The tooth should be

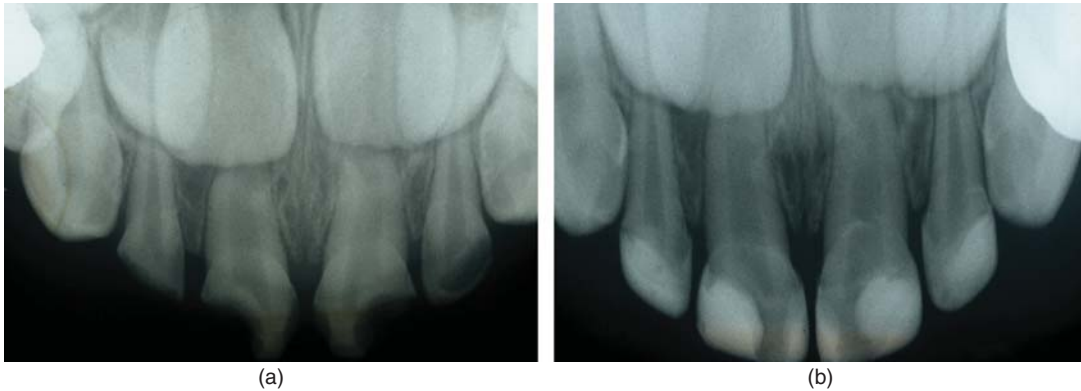

Figure 3.7 (a) Preoperative radiograph. (b) Postoperative radiograph.

reduced circumferentially by approximately 20% or 0.5–1.25 mm as necessary. Adequate reduction of the tooth is extremely important for the crown selected to seat passively.

3. Subgingival reduction: the crown margin should be carefully extended and refined to a feather-edge margin approximately 2 mm subgingivally on all surfaces (Figure 3.10). Avoid excessive tooth reduction in the cervical areas for adequate crown retention. For performing these tooth reductions, thin, tapered diamond or carbide burs may be used. It is important to separate the preparation steps into two using different burs—supra gingival and subgingival to control hemorrhage and avoid excessive tissue trauma.
4. Try-in: it is very important that the crown sits passively on the prepped tooth. The appropriate sized crown will extend subgingivally without any distortion of the gingiva. No force should be applied when seating the crown. Care must be taken to cleanse the internal surfaces of the crown of any blood residue, as this will interfere with proper cementation. Note: one brand (NuSmile ZR Try-In Crowns) has a unique system of try-in crowns, which are used only for provisional fit and then replaced with a new crown to be cemented, thus avoiding contamination with saliva or blood from the prepared internal surface.
5. Cementation: a high-quality self-curing glass ionomer cement should be used. The crowns must be firmly held in position until the cement is set.

When comparing the two methods, that is, the bonded resin composite strip crown and PAC, it must be emphasized that in the latter technique, tooth reduction

is much greater. Effective anesthesia must be obtained, and in many instances, elective pulp therapy may be necessary to allow enough reduction and placement of a well-fitting crown. Inadequate tooth reduction will result in the placement of an oversized crown and an unaesthetic result.

Anterior esthetic fixed appliances

Considerations

The rehabilitation of a young toddler who has developed multiple tooth loss subsequent to rampant EEC or extensive dental trauma may be achieved with an anterior esthetic fixed appliance. Many parents will seek an esthetic solution to replace the lost teeth. When considering the need for an anterior appliance to replace missing primary incisors, the following points should be discussed with the parents (Waggoner & Kupietzky, 2001). The strongest factor for placing an anterior esthetic appliance is *parental* desire and not physiological need. While space maintenance, masticatory function, speech development, and tongue habits may be of some consideration, there is no strong evidence that early loss of maxillary incisors will have any significant, long-lasting effect on the growth and development of the child. Parents may express concern about their child's ability to eat without four incisors. They need to be reassured that feeding is generally not a problem (Koroluk & Riekman, 1991). Children who have had all four maxillary incisors extracted as a result of EEC appear to function well without them. Empirically, many appear to have an improved ability

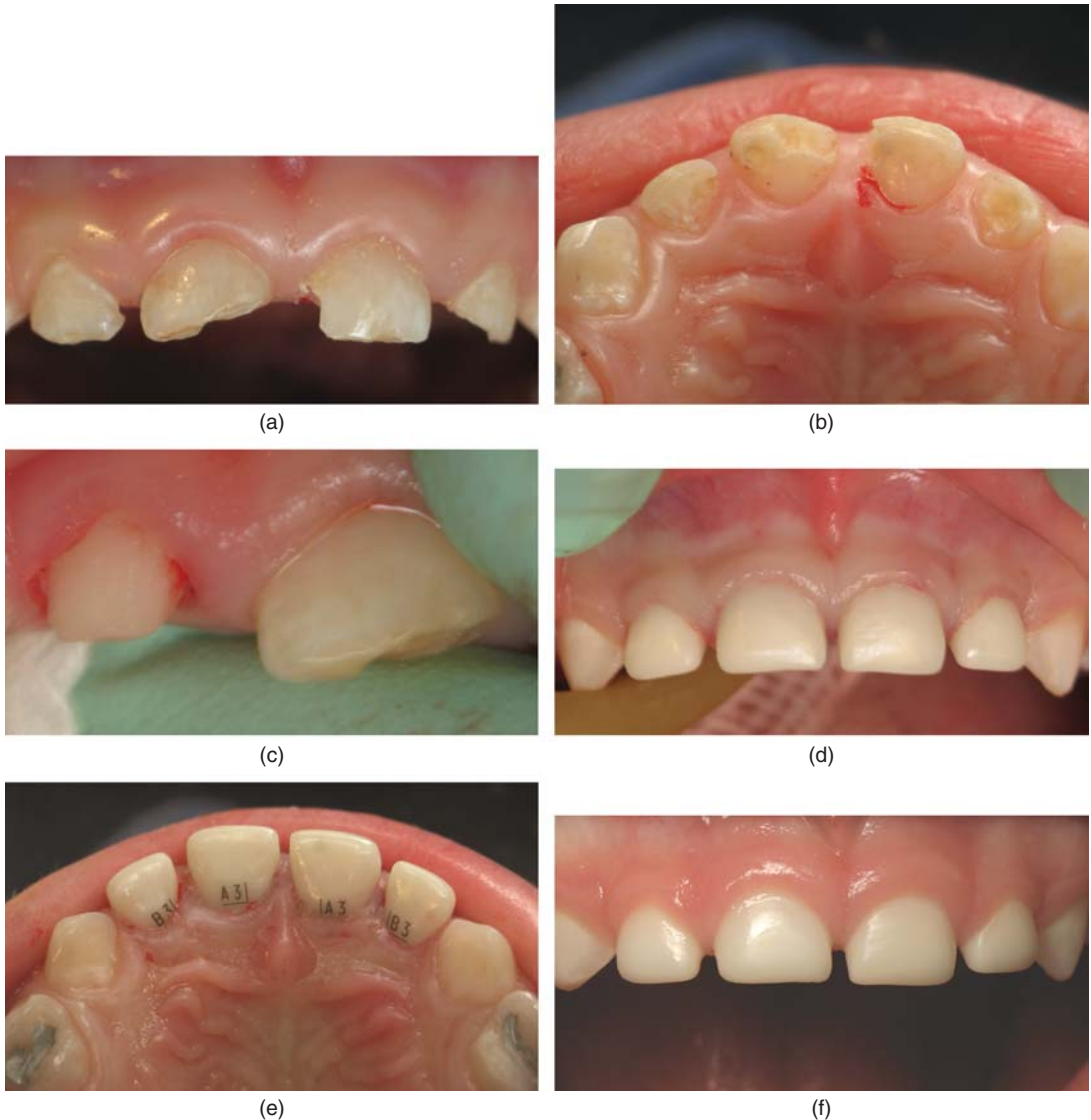

Figure 3.8 (a) Preoperative labial view. Lack of crowding will facilitate placement of PAC: NuSmile ZR crowns were used for restoration of all four maxillary incisors (courtesy of Dr. Sean R. Whalen, Westminster, CO, USA). (b) Preoperative palatal view (courtesy of Dr. Sean R. Whalen, Westminster, CO, USA). (c) Close up of preparation of lateral incisor: note extensive tooth reduction, including subgingival preparation, which is necessary for proper size crown (courtesy of Dr. Sean R. Whalen, Westminster, CO, USA). (d) Cemented NuSmile ZR crowns. Immediate postoperative labial view (courtesy of Dr. Sean R. Whalen, Westminster, CO, USA). (e) Immediate postoperative palatal view (courtesy of Dr. Sean R. Whalen, Westminster, CO, USA). (f) Follow-up. Note excellent gingival adaptation and esthetic result (courtesy of Dr. Sean R. Whalen, Westminster, CO, USA). (g) Follow-up view demonstrating functional occlusion and esthetics (courtesy of Dr. Sean R. Whalen, Westminster, CO, USA). (h) Periapical radiograph at recall: No pathologies noted, centrals approaching exfoliation.

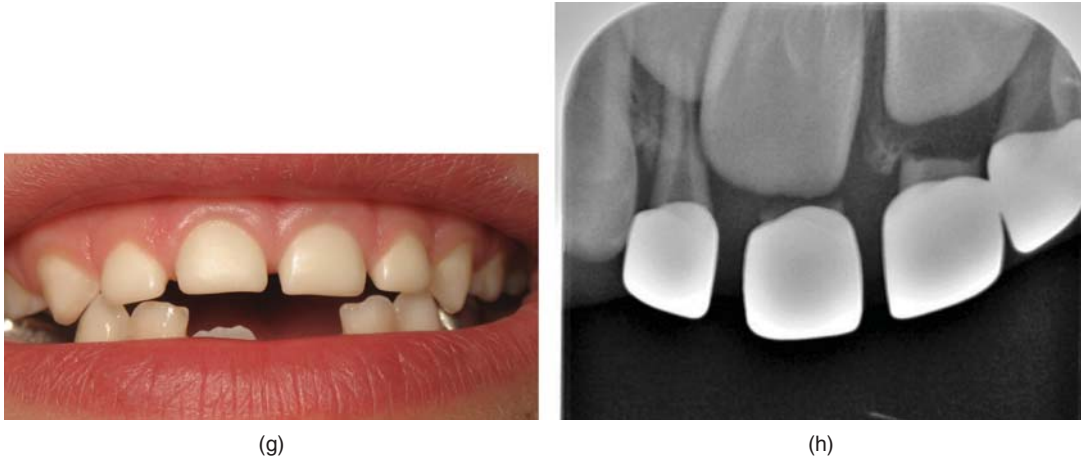


Figure 3.8 (Continued)

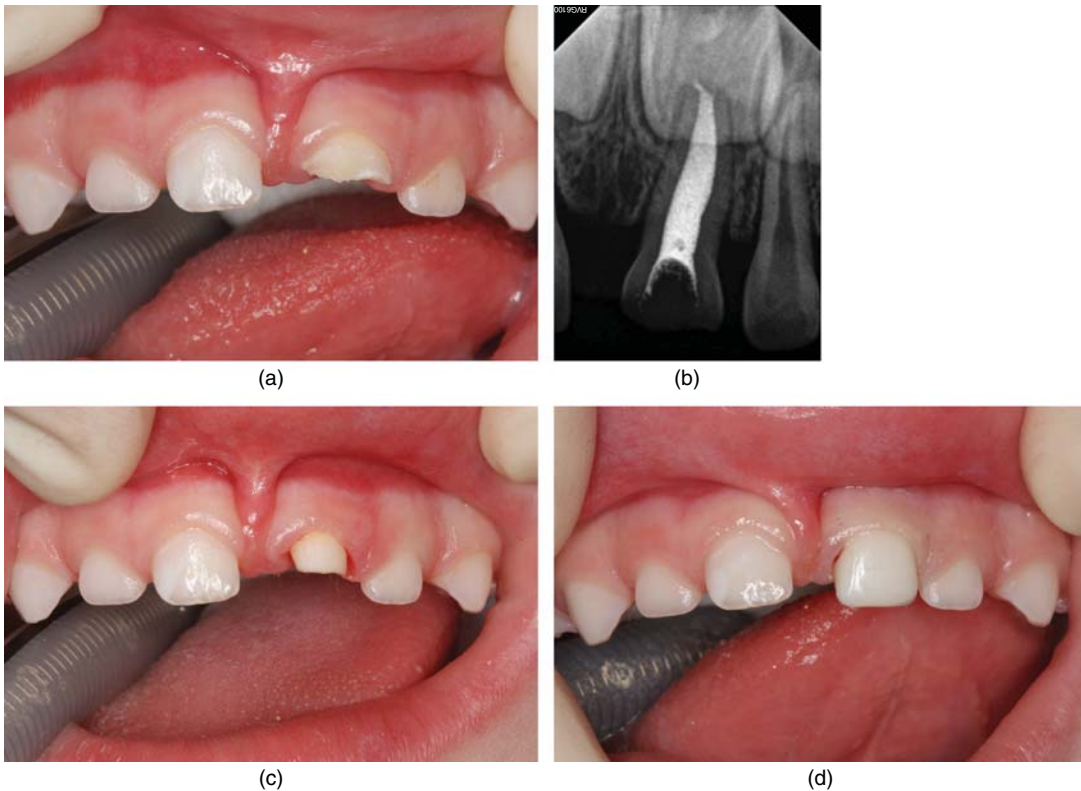


Figure 3.9 (a) Preoperative view of complicated crown fracture of maxillary left primary central incisor with pulpal exposure. Spaced dentition will facilitate placement of a PAC. (courtesy of Dr. Tania Roloff, Hamburg, Germany). (b) Radiograph following root canal therapy (courtesy of Dr. Tania Roloff, Hamburg, Germany). (c) Preparation for NuSmile ZR crown (courtesy of Dr. Tania Roloff, Hamburg, Germany). (d) Immediate postoperative labial view of cemented NuSmile ZR crown (courtesy of Dr. Tania Roloff, Hamburg, Germany). (e) Immediate postoperative palatal view (courtesy of Dr. Tania Roloff, Hamburg, Germany). (f) A discolored bonded resin strip crown following root canal therapy. The translucency of the crown exhibits the underlying change in tooth color. A PAC may be indicated for use in cases involving endodontic treatment of incisors. (g) Six-month follow-up. Note excellent esthetics and no discoloration of restored tooth.

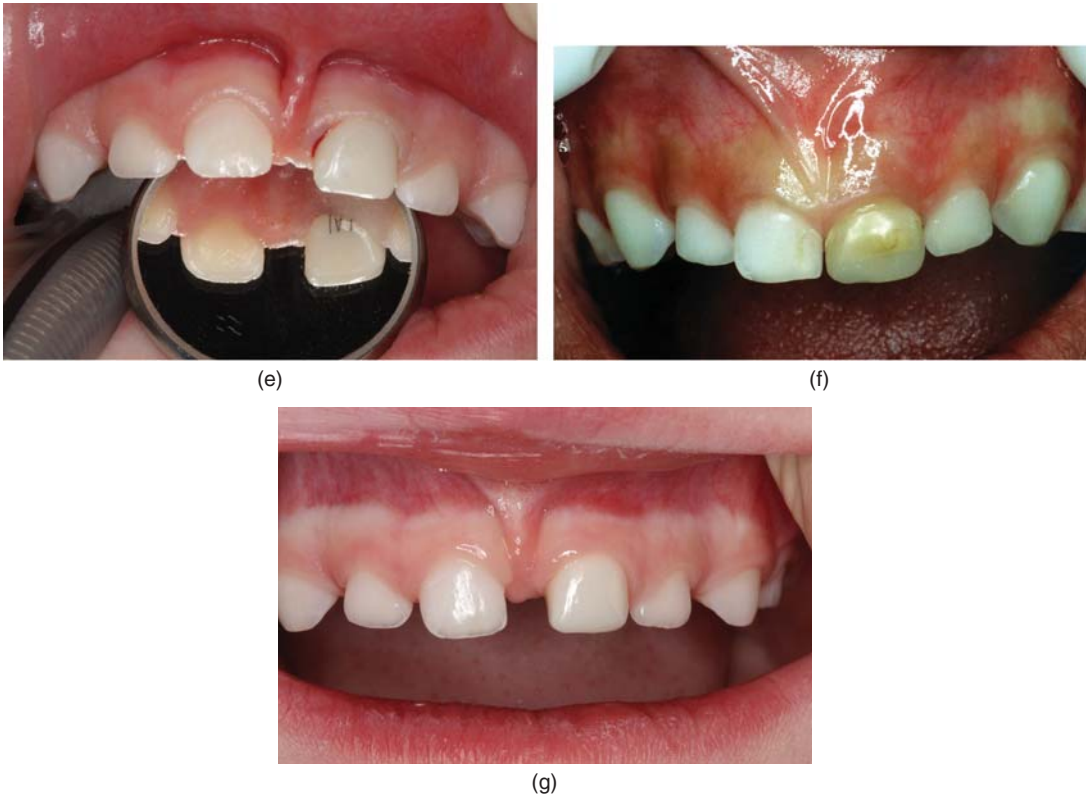

Figure 3.9 (Continued)

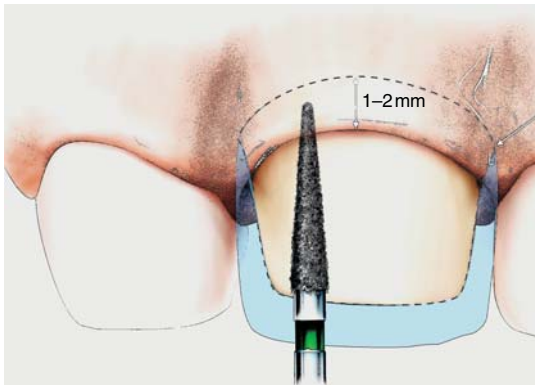


Figure 3.10 Subgingival reduction: the crown margin should be carefully extended and refined to a feather-edge margin approximately 2 mm subgingivally on all surfaces.

to eat and function, likely because the badly decayed or infected incisors inflicted pain on eating.

Another consideration is the child's speech development after extraction of all four incisors. This issue remains somewhat controversial with conflicting opinions as to the affect, if any, on speech development caused by missing primary incisors. It may be prudent to consider appliances for children younger than 3 years who have not yet developed their speech skills. However, children older than 4 years will usually compensate for the tooth loss and not exhibit any long-term speech disorders.

Although space maintenance in the posterior region is an important consideration when there is early loss of primary molars, the anterior segment, from canine to canine, appears to be stable, even with the early loss of several incisors, with no net loss of space from canine to canine. Occasionally, especially in a crowded dentition, if one or more incisors are lost, there may be some rearrangement of space between the remaining incisors, but no space maintenance is usually required if the loss

occurs after the eruption of the primary canines (Ngan & Wei, 1988).

The bottom line is that in most cases, the decision to place an anterior esthetic fixed appliance is individual and personal to be made by the parent in conjunction with the clinician. If parents do not indicate a desire to replace missing anterior teeth, no treatment is usually required. However, if they do wish to replace the missing teeth, they should not be discouraged (Christensen & Fields, 1994). Indeed, some children may be aware of their edentulous appearance and request treatment. When properly fabricated and fitted, these appliances restore a natural and pleasing appearance and thus provide an opportunity for normal psychological development.

Contraindications

The contraindications for the placement of an anterior fixed appliance include the following: patients with seizure disorders, mental retardation, poor ability to follow-up, and very poor hygiene; immune-compromised patients; continuation of inappropriate feeding habits; and significant deep bite, overjet, or anterior crossbite.

Clinical procedure

Appliance design

There are many types of appliances that can be fabricated, including a modified Nance holding arch (Figure 3.11) and the Groper appliance (Figure 3.12). The latter appliance is similar to a Nance holding arch,

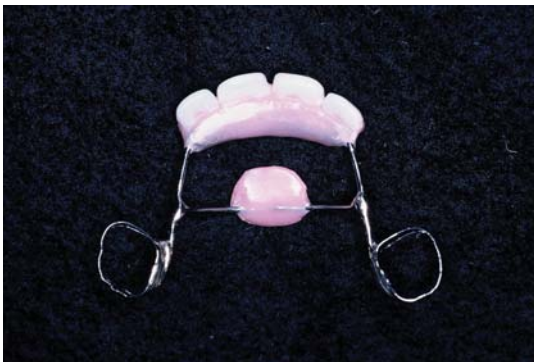

Figure 3.11 The modified Nance holding arch: note palatal acrylic button in the rugae area.

but with plastic teeth processed onto the wire instead of a palatal acrylic button in the rugae area. The round wire should be 0.036–0.040 in. in diameter and is attached to either the first or second primary molars with prefabricated stainless steel bands or SSCs. First molars are preferred as abutments over second molars due to a shorter wire span and less potential interference with erupting 6-year molars. The plastic or acrylic teeth are attached to metal cleats that have been soldered to the palatal wire bar. The teeth sit directly on the alveolar crest without any gingival colored acrylic extending into the vestibule or onto the palate (Figure 3.12).

In instances of asymmetric alveolar ridge deformities, it is suggested to add gingival colored acrylic to mask the missing height and thus achieve symmetry and better esthetics (Figure 3.13).

In general, it is easier to achieve good esthetic results when replacing all four maxillary incisors. The appliance may be used to replace single, double, or triple incisors, but more detailed attention will need to be made when choosing color and designing the appliance's tooth morphology to match the remaining natural teeth in these clinical situations.

Steps in fabrication

First appointment

1. Fit bands on first or second molars.
2. Take an alginate impression of the maxillary jaw with the bands on teeth (Figure 3.13d). Remove the impression, place, and secure the bands in the impression and pour up with dental stone (Figure 3.13f). Note, some laboratories may request that bands be removed after being fitted and an impression be taken *without* the bands in place. The fitted bands are then sent to the laboratory and placed by the technician into the plaster working model.
3. Take a mandibular alginate impression and wax bite registration.
4. Select color (Figure 3.13e).

Second appointment

1. If not performed at the previous appointment, anesthetize and extract the anterior teeth. Small pieces of

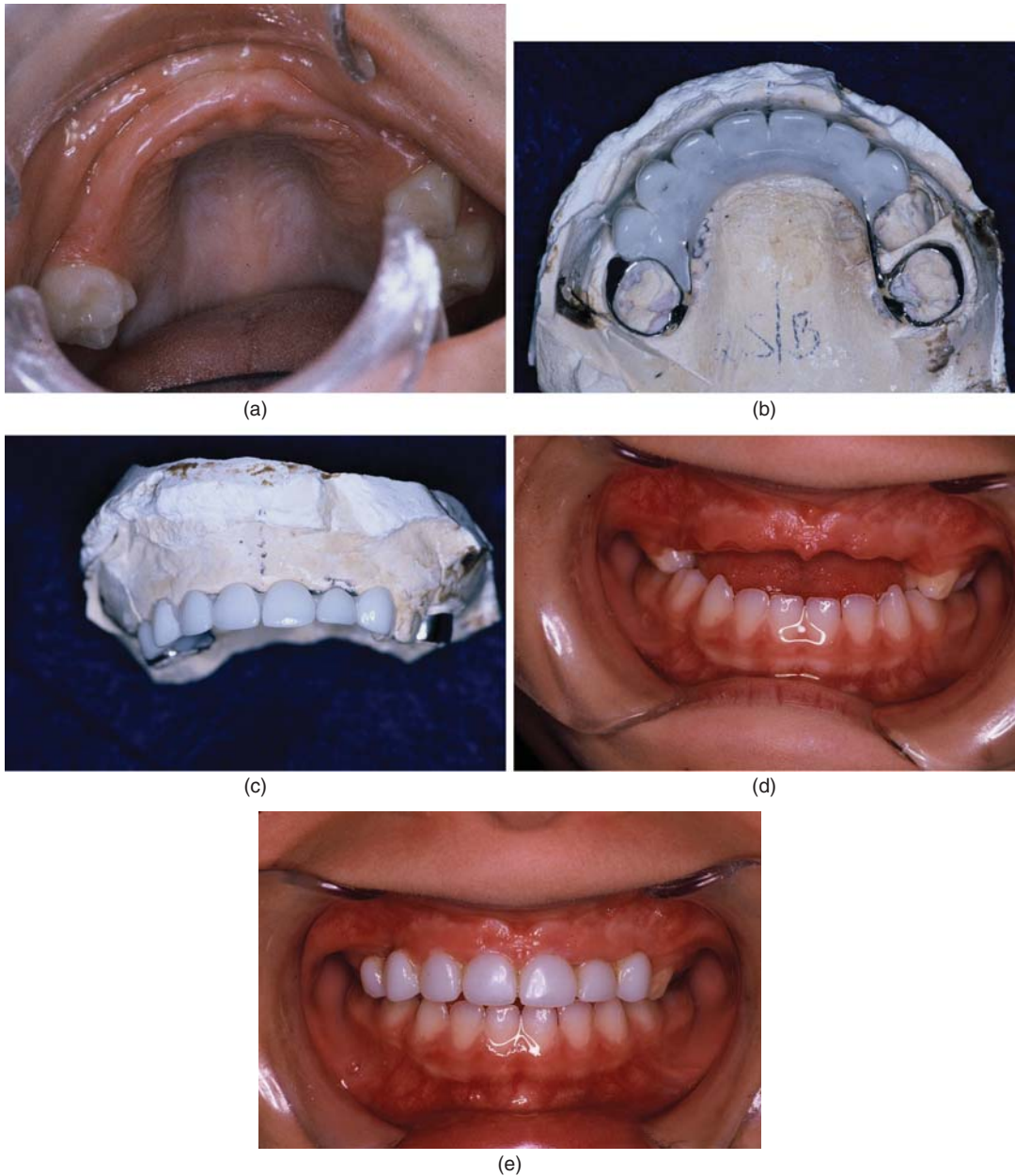


Figure 3.12 (a) At age 19 months, the child sustained complete avulsion of all maxillary incisors, canines, and right first primary molar. (b) At age 34 months, a Groper appliance was fabricated. The plastic or acrylic teeth are attached to metal cleats that have been soldered to the palatal wire bar. (c) The teeth sit directly on the alveolar crest without any gingival colored acrylic extending into the vestibule or onto the palate. (d) Labial view of edentulous anterior region. (e) Intraoral view demonstrating the appliance after 2 years of use.

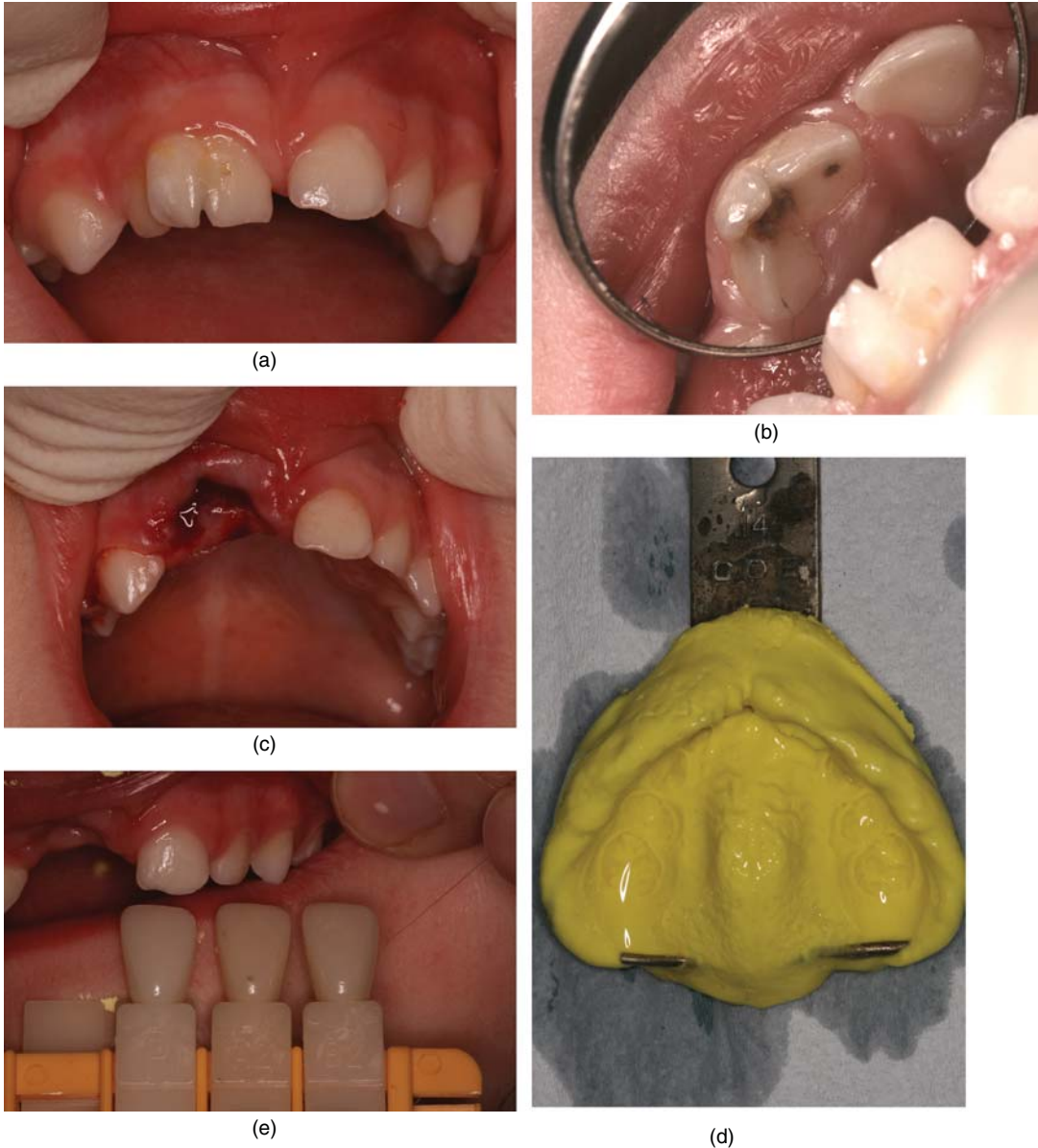


Figure 3.13 (a) A 30-month-old patient with fusion and concrescence of upper right primary central, lateral, and supernumerary teeth. (b) Palatal view demonstrating deep caries; extraction was treatment choice to be followed by placement of fixed appliance. (c) After extraction, note resulting alveolar defect. (d) Alginate impression taken without bands. (e) Color selection is important due to asymmetrical tooth loss. (f) Upper and lower working models are mandatory. In addition, wax bite registration is required. (g) Groper appliance: note gingival extension to compensate for alveolar bone loss and asymmetrical ridge. (h) Anterior view without appliance. (i) Appliance *in situ*. Note morphology of right central constructed to mimic the shape of natural left incisor.

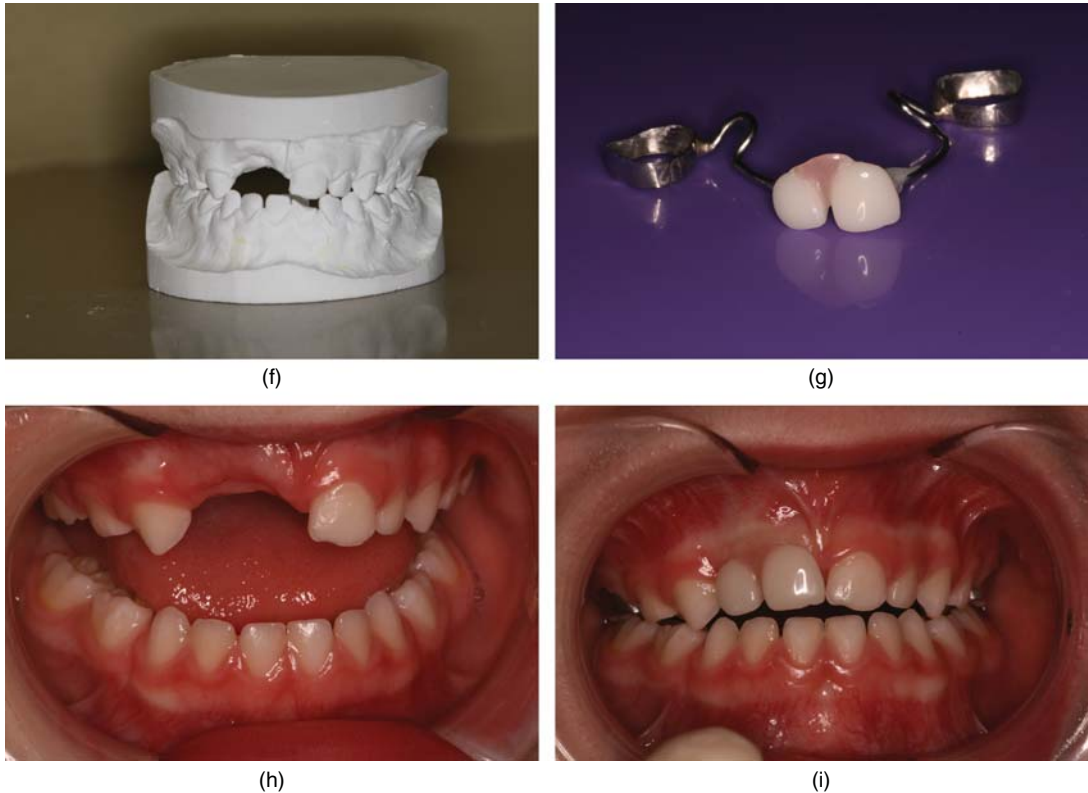


Figure 3.13 (Continued)

absorbable gelatin sponge placed into the sockets will aid hemostasis.

2. Try-in the appliance. Adjust as needed with three-prong pliers and crown crimpers.
3. Cement the appliance with glass ionomer cement or resin-modified glass ionomer cement (Figure 3.13g–3.13i).

Timing of placement: same day as extraction or delay for healing

The timing of placement is somewhat controversial. Historically, it was suggested to allow 6–8 weeks after tooth loss, before fabrication. This delay was thought to allow good a better fitting, more esthetically pleasing appliance. However, personal experience has found that delay is not necessary and immediate placement is possible. Same-day extraction and appliance placement can result in an excellent clinical outcome. Perhaps,

one reason to delay treatment is to ascertain when the parents' concern of esthetics is a real one. Many parents who contemplated an appliance will opt to change their decision and not place it after they observe how well their child adapts to their post-extraction situation. They may observe during this waiting period that no negative change in their child's functioning, eating, or speech has occurred. Esthetically, many parents' image of their child improves within the delay period, and their esthetic concern will dissipate.

Summary

Successful restoration of severely decayed primary incisors may be one of the greatest challenges in pediatric dentistry. Patients with ECC have a greater propensity for developing new and recurrent caries. It is critical for the dentist to treat the disease and not only the individual teeth. Restorative treatment should

commence contingent on proper home care. Proper technique can be successfully achieved with the right planning and execution.

Selected texts and figures have been adapted with permission from Dr. Kupietzky's previous works

- Kupietzky, A. (2001) The treatment and long-term management of severe multiple avulsions of primary teeth in a 19-month-old child. *Pediatric Dentistry*, **23**, 517–521. Figure 3.12
- Kupietzky, A. (2002) Bonded resin composite strip crowns for primary incisors. *Pediatric Dentistry*, **24**, 145–148. Figures 3.3a, 3.3b, 3.4a, 3.4b, 3.6a, 3.6b, 3.6e, 3.6g, 3.6h, 3.6i
- Psaltis, G. & Kupietzky, A. (2008) A simplified isolation technique for placement of composite strip crowns. *Pediatric Dentistry*, **30**, 436–438. Figures 3.5a, 3.5b, 3.5c, 3.5d

References

- Christensen, J.R. & Fields, H.W. (1994) Space maintenance in the primary dentition. In: Pinkham, J.R. (ed), *Pediatric Dentistry: Infancy Through Adolescence*, 2nd edn. W.B. Saunders Company, Philadelphia, pp. 358–363.
- Croll, T.P. (1985) Alternative methods for use of the rubber dam. *Quintessence International*, **16**, 387–392.
- Croll, T.P. (1995) Restorative dentistry for preschool children. *Dental Clinics North America*, **39**, 737–770.
- Koroluk, L.D. & Riekman, G.A. (1991) Parental perceptions of the effects of maxillary incisor extractions in children with nursing caries. *Journal of Dentistry for Children*, **58**, 233–236.
- Ngan, P. & Wei, S.H.Y. (1988) Management of space in the primary and mixed dentitions. In: Wei, S.H.Y. (ed), *Pediatric Dentistry: Total Patient Care*. Lea & Febiger, Philadelphia, pp. 462–470.
- Reid, J.S., Callis, P.D. & Patterson, C.J.W. (1991) *Rubber Dam in Clinical Practice*. Quintessence Publishing, London, pp. 29–30.
- Ripa, L.W. (1988) Nursing caries: a comprehensive review. *Pediatric Dentistry*, **10**, 268–282.
- Waggoner, W.F. (2002) Restoring primary anterior teeth. *Pediatric Dentistry*, **24**, 511–516.
- Waggoner, W.F. & Kupietzky, A. (2001) Anterior esthetic fixed appliances for the preschooler: considerations and a technique for placement. *Pediatric Dentistry*, **23**, 147–150.
- Webber, D., Epstein, N. & Tsamtsouris, A. (1979) A method of restoring primary anterior teeth with the aid of a celluloid crown form and composite resins. *Pediatric Dentistry*, **1**, 244–246.

4

Primary molar adhesive tooth restoration

Constance M. Killian and Theodore Croll

Introduction

Sixty years ago, when Hogeboom (1953) offered the Sixth edition of his classic pediatric dentistry textbook, *Practical Pedodontia or Juvenile Operative Dentistry and Public Health Dentistry*, the materials used to repair primary teeth were as follows: “gutta-percha,” black copper cement, Fleck’s Red Copper Cement, silver amalgam, copper amalgam, Kryptex (“a good silicate”), silver nitrate, ammoniated silver nitrate, chromium alloy deciduous crowns, and rapid setting plastic filling materials (requiring “ample pulp protection”). Stainless steel crowns are still very useful and are known for their durability and reliability. “Plastic” filling materials have made their way to the forefront of direct application restorative dentistry, but today’s materials have little resemblance to the original resin products. Silver amalgams are still used by some dentists for repair of primary teeth, but because they do not bond to tooth structure, have a dark color, and suffer from the continuing false controversy over their safety, they are being offered to parents less and less.

An ideal direct application dental restorative material for primary molars would be biocompatible and tooth colored, adhere to tooth structure with no subsequent marginal leakage, have sufficient physical properties so as not degrade in the mouth, have “on-command” hardening after applied to tooth structure, and handle easily for the practitioner.

Decades of progress have brought us advanced direct placement restoratives that come close to meeting all the above-mentioned requirements to be considered ideal. Resin-based composites (RBCs) and the glass polyalkenoate (glass ionomer) systems have been at the forefront of the “adhesive dentistry” revolution that has immeasurably progressed restorative dentistry for children. Berg (1998) succinctly reviewed modern adhesive restorative materials that are useful in clinical pediatric dentistry.

The ideal operative field: rubber dam isolation

The use of adhesive materials for restoring carious, malformed, or fractured primary molars demands careful attention for moisture control. Many adhesive materials, particularly RBCs, are sensitive to moisture and require isolation of teeth to be treated. There is no better way to achieve such isolation and create an ideal operative field than the rubber dam.

Dr. Sanford Barnum first used a “rubber cloth” to isolate a mandibular molar of R.C. Benedict on March 15, 1864 (Christen, 1977). From that time on, that manner of isolating teeth became the standard protocol in the profession for restorative dentistry (Francis, 1865; Barbakow, 1964). Croll (1985) listed the following benefits of rubber dam use.

- Operating time is reduced.
- Visibility for the dentist is improved.
- Tongue and cheek are protected and out of the way.
- The mouth stays moist and more comfortable for the patient.
- The patient is protected from aspirating or swallowing excess material, water spray, infected tooth substance, or broken instrument fragments.
- Soft tissues in region of operation are better protected from accidental engagement.
- Risk of pulpal contamination is decreased once pulp space is exposed.
- Superfluous patient conversation is decreased.
- Patients become more relaxed and feel safer.
- A dry operating field is much easier to establish and maintain.

Because of the anatomical form of primary molars, stringent tooth-by-tooth application of a rubber dam, as taught in dental schools, can be quite difficult, frustrating, and time-consuming in restorative dentistry for young patients. The rubber dam procedure does not need to be abandoned, however. The “slit dam” technique is an easier but very effective way to apply rubber dam for the restoration of primary molars (Croll, 1985). The steps for isolation using the slit dam technique are as follows.

1. Select an appropriate rubber dam clamp and secure an 18-in. piece of dental floss to the loop of the clamp.
2. Place the rubber dam on the frame. For pediatric patients, a 5-in. frame is typically sufficient (“nonlatex” dam should be used for patients with sensitivity or allergy to latex).
3. Punch two holes in the dam, one for the most posterior tooth to be isolated and the other for the most anterior tooth to be isolated.
4. Using scissors cut a slit to connect the two holes in the dam (Figure 4.1).
5. Use rubber dam forceps to seat the selected clamp onto the most posterior tooth being isolated.
6. Carefully stretch the rubber dam over the clamp, extending it to reveal the quadrant being treated. If necessary, a piece of dental floss or a wooden wedge may be used to secure the dam to the mesial aspect of the most anterior tooth.

Figure 4.1a–4.1c shows the slit dam being used to isolate the teeth to be restored.

Adhesive primary molar tooth restoration

Because of the availability of preventive and restorative dental materials that can micromechanically or chemically bond to tooth structure, much has changed over the last three decades. The term “adhesive dentistry” applies to certain categories of dental materials, including pit and fissure sealants, resin-based composites (RBCs), compomers (COs), and glass ionomer (GI) systems including resin-modified glass ionomers (RMGIs). Practitioners should be familiar with the indications for the various materials and fully understand the advantages and disadvantages of each. Awareness of limitations of each class of material and those of specific brands is essential to success with their use. Knowledge of the handling characteristics of each material is also critical to assure that all the advantages of their use will be optimized.

Pit and fissure sealants

Pediatric dentistry specialists and general dentists treating young children have mixed opinions about pit and fissure sealants for primary teeth. The purpose of resin-bonded sealants is to obdurate enamel imperfections so that bacteria and food debris cannot gain access to the depths of those imperfections. Bonded resin sealants can succeed in primary molars; however, in very young children, their application requires just as much time and effort as does restoration of those teeth if they develop caries lesions... and often they do not. Many dentists, including these authors, recognize that bonded resin sealants do not adhere as well to properly etched primary tooth enamel, even if an ideal technique is used and the enamel is roughened with a diamond bur. Some practitioners report that they will seal a primary molar with at-risk grooves, for no additional fee, when an adjacent tooth is being restored. For example, if a primary first molar requires disto-occlusal repair, the neighboring primary second molar can be sealed, with the rubber dam already in position. The use of resin-bonded sealants for primary molars should be considered on a case-by-case basis for children.

Resin-based composites (RBC)

RBC material is used for tooth-colored restorations in primary posterior teeth. When used as indicated and with careful technique in cooperative patients, RBCs

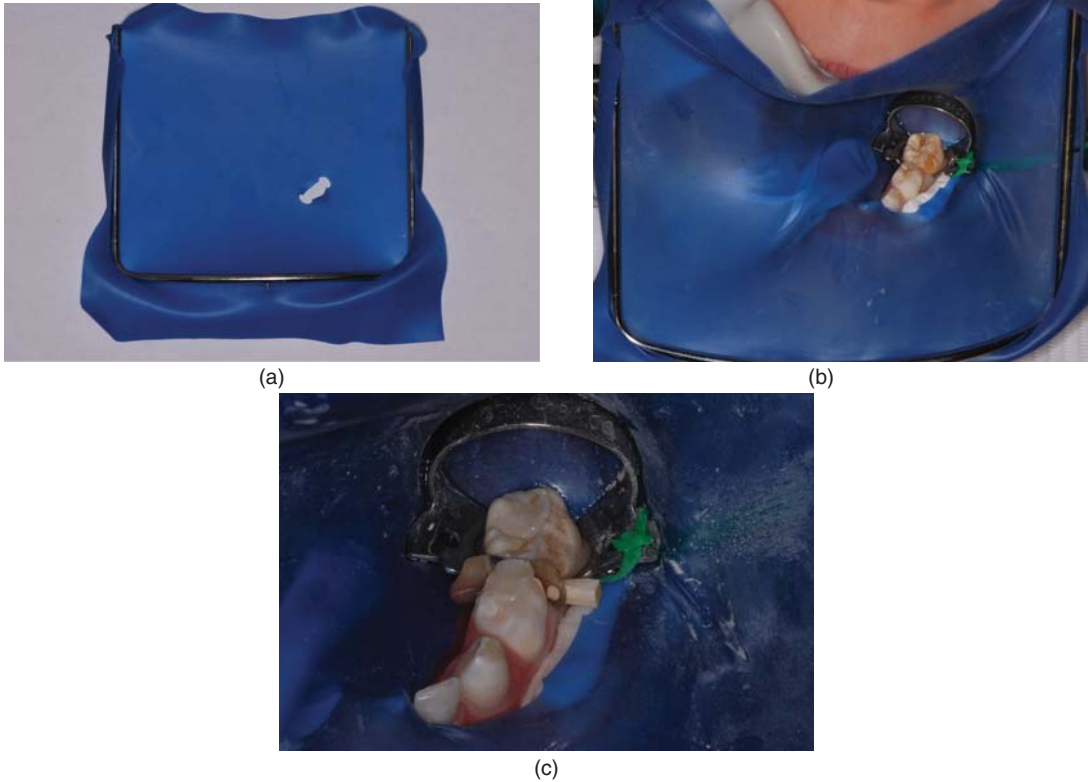


Figure 4.1 (a) Typical placement of holes and slit in rubber dam for mandibular teeth. (b) Rubber dam in place, demonstrating “slit dam” technique. Note placement of Molt mouthprop for patient comfort and bite stability. In addition, a cotton roll has been placed in the buccal vestibule for dry isolation. (c) Close-up view of “slit dam” in place creating an ideal operative field.

have been shown to be effective for Class I, II, and V restorations of primary molars.

RBC materials are classified on the basis of their particle size, ranging from 0.1 (microfilled) to 100 μm (macrofilled). Smaller particle size allows for greater polishability and esthetics, whereas larger particle size provides for greater strengths. There is a wide range of RBC materials available, each with different physical properties and handling requirements. Although some of the RBC materials have the strength and durability to withstand heavy chewing forces and esthetic properties, they do not release fluoride to adjacent tooth structure and require the use of some form of etching and a bonding agent in order to adhere to the tooth preparation. Because resin-bonded composites are extremely sensitive to moisture, isolation and attention to proper technique are critical to the success of these restorations. If proper isolation with rubber

dam is not possible, one can expect a higher degree of failure of the restoration. In addition, because extra time is required for the placement of RBC restorations, it is best to reserve these materials for patients with good cooperation. When using these materials, tooth preparation for limited pit and fissure caries does not require extension of the preparation into healthy areas of the tooth (i.e., “extension for prevention”). Also, Class II restorations in primary molars should not extend beyond the proximal line angles. Postoperative sensitivity has been reported when bonding agent is applied to dentin that has not been protected with any form of base or liner. This postoperative sensitivity can be minimized by using a glass ionomer base or liner before etching and application of the bonding agent and RBC. To summarize, RBC is indicated for the following:

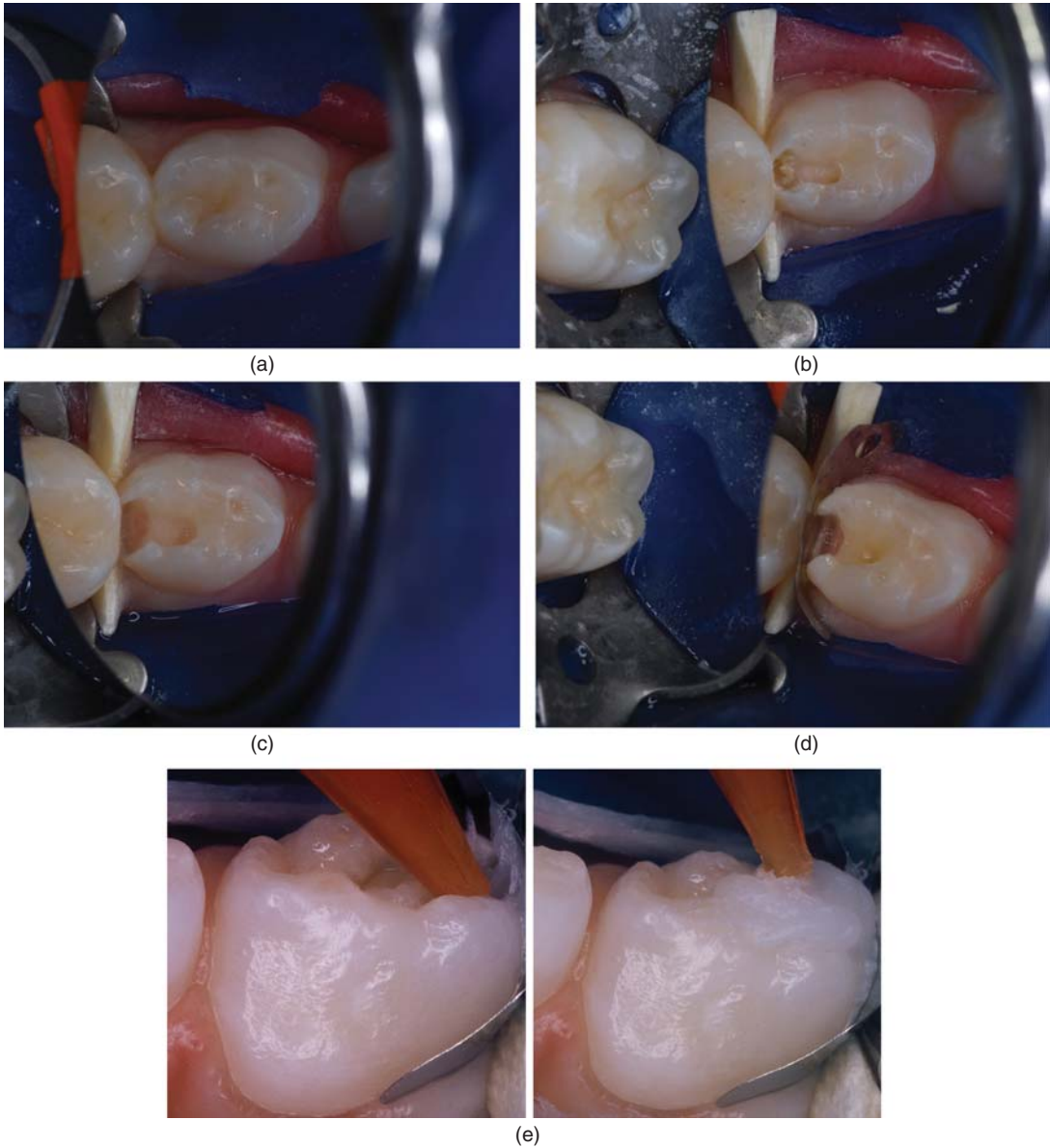


Figure 4.2 (a) Five-year-old child with distal caries lesion of the primary first molar. Tooth isolated using “slit dam” technique. (b) Initial tooth preparation with wooden wedge in place. (c) Carious substance debrided. (d) Contoured matrix strip placed and wooden wedge inserted. (e) First increment of RMGI material injected and light polymerized (left). Second increment follows (right). (f) Restoration sculpted with slow-speed round diamond burs. Marginal ridge contoured. (g) RMGI restoration, 2.5 years after placement. (h) Bitewing films, preoperatively (left) and 3 years postoperatively (right).

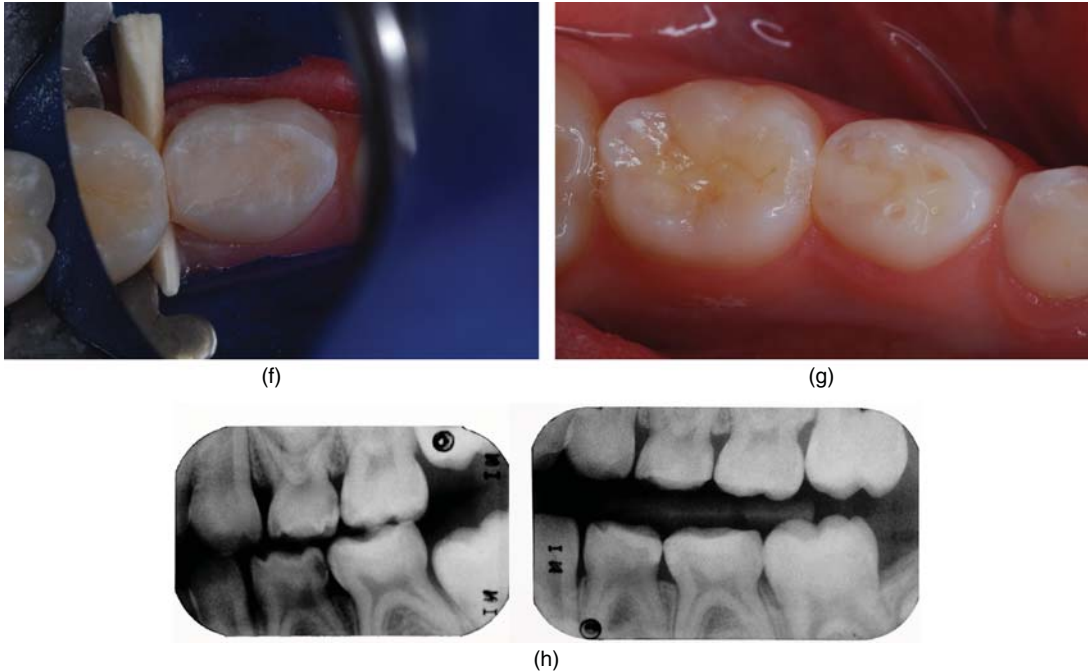


Figure 4.2 (Continued)

Class I restorations—pit and fissure caries and caries extending into dentin.

Class II restorations—where caries does not extend beyond proximal line angles.

Class V restorations.

RBC is contraindicated for patients with a high risk of developing dental caries, uncooperative patients, and patients for whom ideal tooth isolation is not possible.

Compomers (CO)

Compomers (polyacid-modified RBCs) are another category of dental materials that have been used for the restoration of primary molars. Essentially, these are RBC materials with incorporated chunks of hardened glass ionomer cement. Although compomers have some of the properties of RBC, they do not provide the same fluoride release and adaptability of traditional glass ionomers and do not quite have the physical strengths of standard RBCs. In addition, because these materials are resin based, a completely dry operating field is critical. There appears to be no significant benefit to the use of compomers over that of RBCs.

Resin-modified glass ionomer restorative cements (RMGI)

The glass ionomers systems (glass polyalkenoate cements) have a long history of use in pediatric restorative dentistry (Killian & Croll, 1991; Croll *et al.*, 1993; Croll, 1995; Nicholson & Croll, 1997). These materials bond chemically to enamel and dentin, have the ability for uptake and release of fluoride to adjacent tooth structure, have thermal expansion similar to tooth structure, are biocompatible, and are less sensitive to moisture when compared to RBCs and compomers. However, glass ionomers do not display the degree of fracture toughness, other physical strengths, and wear resistance that are often required in order to withstand the forces of mastication; this has limited their use as stand-alone restorations in primary molars to Class V and some Class I restorations. Glass ionomers may also serve as bases or liners beneath RBC materials, providing chemical adhesion to the dentin, some properties, and fluoride release to support the overlying RBC restoration.

Since their introduction in the early 1990s, RMGI restorative cements have been used successfully in the

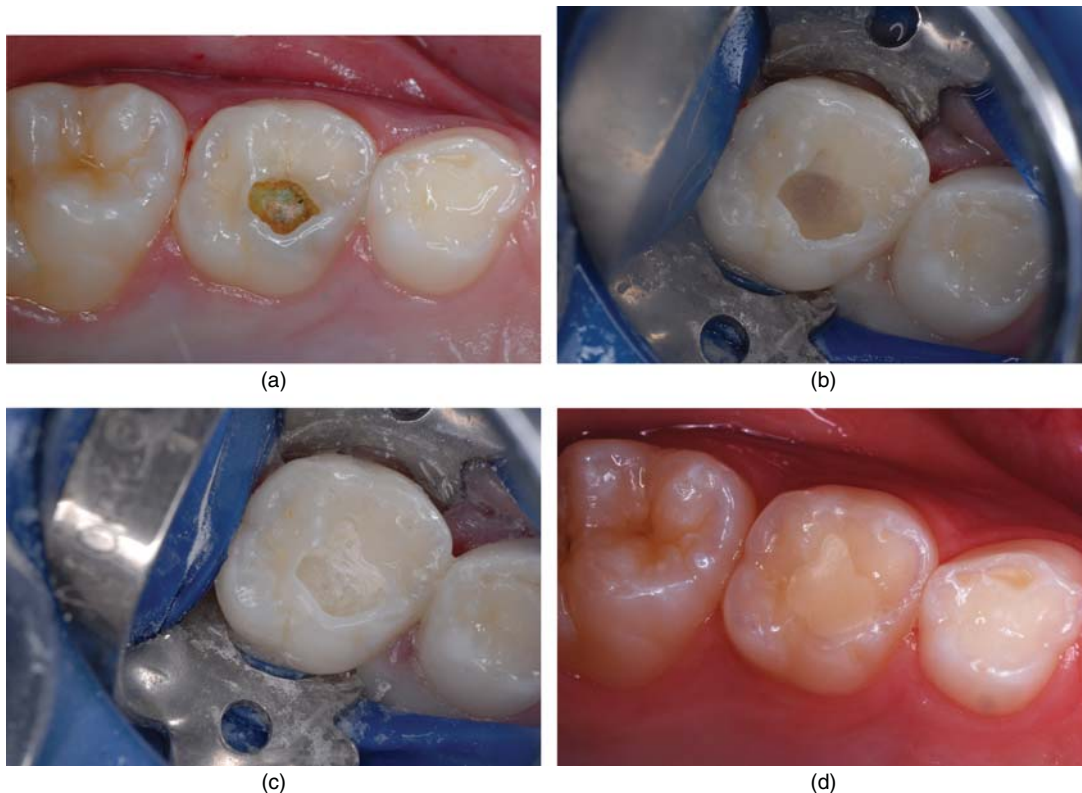


Figure 4.3 (a) Six-year-old child with occlusal caries affecting the maxillary second primary molar, tooth isolated for restoration. (b) Carious substance debrided, demonstrating depth of lesion approximating pulp. (c) Hard-setting calcium hydroxide indirect pulp cap placed, followed by the placement of a resin-modified glass ionomer liner. (d) Final restoration, 26 months postoperatively.

primary dentition (Croll *et al.*, 2001). The RMGI cements are recommended for Class I, II, and V restoration of primary molars and have all the benefits of traditional glass ionomers (biocompatibility, fluoride release, chemical adhesion to tooth structure, and thermal expansion coefficient similar to tooth structure). The incorporation of resin into the glass ionomer formulation has greatly improved wear resistance, physical strengths such as fracture toughness and fracture resistance, and the esthetics of the RMGIs, when compared to traditional glass ionomers. RMGIs harden both by light-curing and by the acid–base glass ionomer setting reaction. The latest version of this material is called a “nano-ionomer” (Ketac Nano, 3M ESPE) (Killian & Croll, 2010). This material combines the fluoroaluminosilicate glass particles with nanofiller and “nanofiller clusters” so that color characteristics and polishability are enhanced, along with some physical properties. We consider

the nano-ionomer innovation as another step in the continuum of RMGIs approaching the wear, strength, and esthetics of RBCs. Because RMGIs are hydrophilic materials, there is less concern with exposure to moisture as is the case with RBCs. Proper isolation is still important, but the placement of these materials is less technique sensitive and less time-consuming than the placement of RBC. This is especially important when dealing with pediatric patients.

RMGI restorative cements are indicated for treatment of Class I, II, and V lesions in primary molar teeth.

Summary

Regardless of the choice of adhesive material for restoring primary molars, the following basic principles apply to all of the materials discussed.

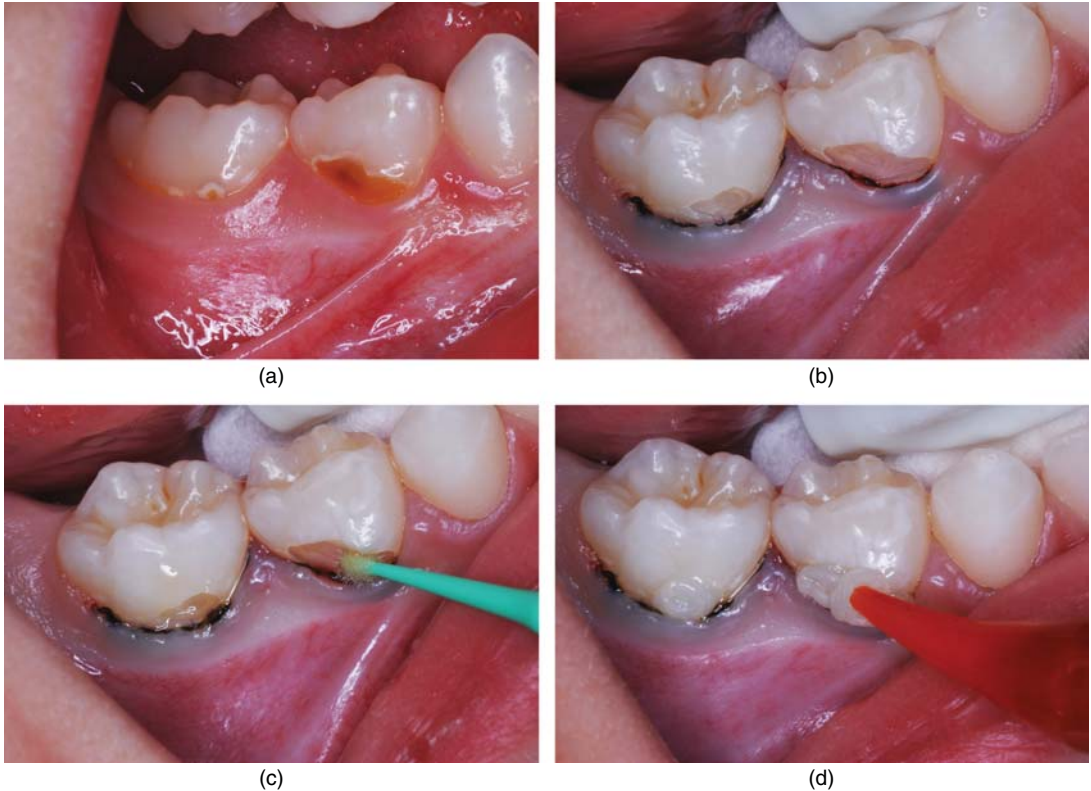


Figure 4.4 (a) Five-year-old child with Class V caries lesions of the mandibular first and second primary molars. (b) Carious substance debried and cord in place for hemostasis and gingival retraction. (c) RMGI primer application; light polymerization followed. (d) Careful injection of RMGI material into cavity preparation. (e) Light polymerization. (f) Diamond finishing burs used to contour restoration. (g) Final restoration, 10 months postoperatively.

- Careful isolation of the teeth being restored will maximize the performance of the chosen material.
- It is important to be familiar with the specific recommendations of the manufacturer regarding indications, application technique, and use of the restorative material. Each category of material discussed (glass ionomer, RBC, CO, RMGI) has technique applications that are unique for that material. In addition, within the specific category, a particular manufacturer will have instructions that are unique to that brand of material. Optimization of performance of the materials is achieved by carefully following the manufacturer's recommendations.
- Tooth preparation should, in most cases, follow traditional outline form, recognizing that some materials (e.g., RBC) may not require "extension for prevention," and a more conservative preparation may be used.
- For Class II restorations, the use of a segmented matrix secured by a wooden wedge can facilitate the placement of the restoration while maintaining appropriate proximal contact.
- Consider using mechanical retention as an adjunct to the overall tooth preparation. Although these materials are "adhesive," some chemically adhering to the tooth directly (glass ionomer, RMGI) and others adhering to the tooth via use of a bonding agent (RBC, compomer), the use of mechanical retention can support the overall retention of the material.
- Recognize the need for incremental placement of some materials (RBC, CO, RMGI), particularly in larger, deeper restorations. Light curing needs to be

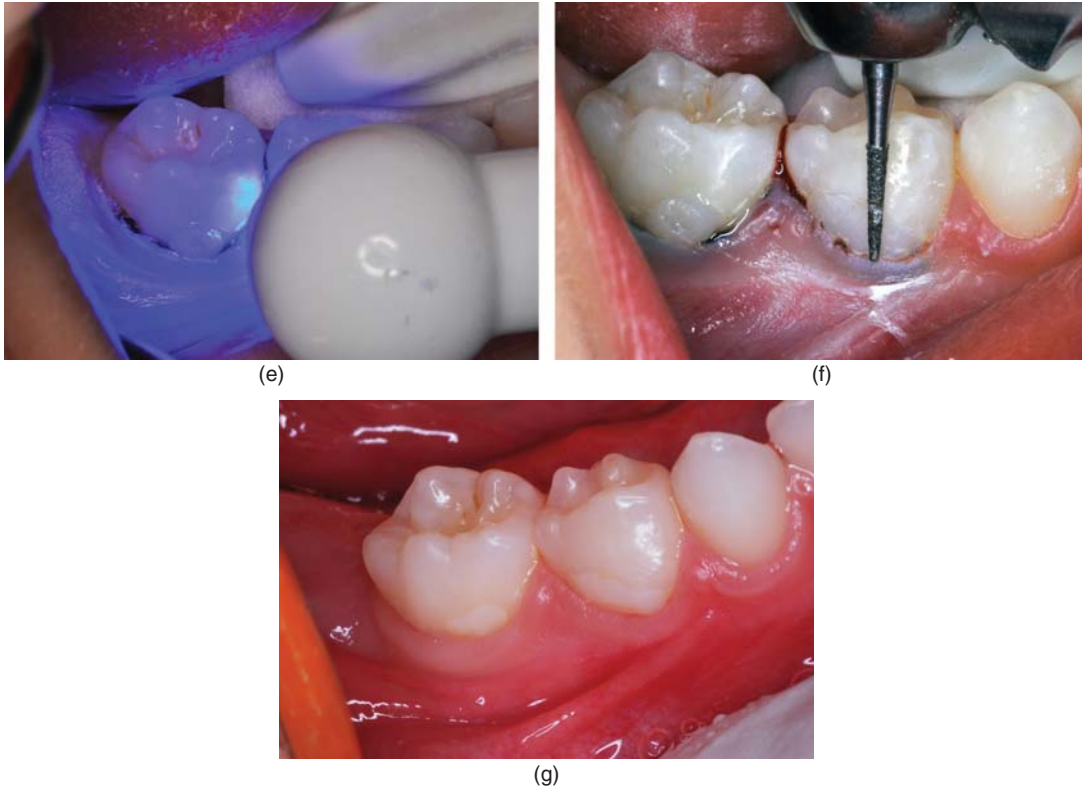


Figure 4.4 (Continued)

complete at each level of the restoration, and inappropriate bulk placement and bulk curing may lead to restoration failure. This is especially important with the nano-ionomer because it does not have a chemical resin curing component such as other RMGIs. Note that it is also important to periodically verify that the light emitted from the light-curing device is of appropriate wavelength and intensity to cure the desired materials. Manufacturers recommend periodic evaluation of the curing light to verify optimal performance. Inadequate light penetration may also lead to failure of the restoration.

7. After placement and curing of the restoration, use burs and hand instruments as well as finishing strips as needed to assure proper contours, contacts, and occlusal relationships. The authors recommend the use of diamond finishing burs for optimal contouring.
8. Document in patients' office records the form of isolation and the specific material(s) used, including any base or liner, the type of bonding agent, and whether

the material was placed in bulk (smaller, shallower preparations) or in increments, as indicated. This will facilitate future assessment of the material's performance.

Figures 4.2a–4.4g illustrate the placement of various categories of adhesive restorations in primary molars (Class I, II, and V). The material used for these illustrations is RMGI, and the technique demonstrated in this case is unique to this material, although the overarching principles of adhesive restoration, as described previously, are common to all materials.

References

- Barbakow, A.Z. (1964) The rubber dam: a 100-year history. *J Southern California State Dental Association*, **32**, 460–464.
- Berg, J.H. (1998) The continuum of restorative materials in pediatric dentistry—a review for the clinician. *Pediatric Dentistry*, **20**, 93–100.

- Christen, A.G. (1977) Sanford C. Barnum, discoverer of the rubber dam. *Bulletin of the History of Dentistry*, **25**, 3–9.
- Croll, T.P. (1985) Alternative methods for use of the rubber dam. *Quintessence International*, **16** (6), 387–392.
- Croll, T.P. (1995) Restorative dentistry for preschool children. In: Johnson, D. & Tinanoff, N. (eds), *Dental Care for the Preschool Child*. W.B. Saunders, Philadelphia *Dental Clinics of North America*, **39**(4):737–770.
- Croll, T.P., Killian, C.M. & Helpin, M.L. (1993) A restorative dentistry renaissance for children: light-hardened glass ionomer/resin cement. *Journal of Dentistry for Children*, **60**, 89–94.
- Croll, T.P., Bar Zion, Y., Segura, A. & Donly, K.J. (2001) Clinical performance of resin-modified glass ionomer cement restorations in primary teeth. *Journal of the American Dental Association*, **132**, 1110–1116.
- Francis, C.E. (1865) The rubber dam. *Dental Cosmos*, **7**, 185–187.
- Hogeboom, F.E. (1953) *Practical Pedodontia or Juvenile Operative Dentistry and Public Health Dentistry*, 6th, Chapter X edn, St. Louis, pp. 165–184.
- Killian, C.M. & Croll, T.P. (1991) Smooth surface glass ionomer restoration for primary teeth. *Journal of Esthetic Dentistry*, **3**, 37–40.
- Killian, C.M. & Croll, T.P. (2010) Nano-ionomer tooth repair in pediatric dentistry. *Pediatric Dentistry*, **32** (7), 530–535.
- Nicholson, J.W. & Croll, T.P. (1997) Glass-ionomers in restorative dentistry. *Quintessence International*, **28** (11), 705–714.

5

Full coverage restoration for primary molars

Jane A. Soxman

Stainless steel crowns

Stainless steel crowns (SSCs) are the restoration of choice for primary molars of children with high-caries risk, after pulp therapy, for large, multisurface caries and interproximal preparation that extends beyond the line angle (American Academy of Pediatric Dentistry, 2014). The use of SSCs may reduce the need for repeated treatment with general anesthesia (Ohlimoba & Nelson, 2013). SSCs provide a good seal and a durable, reliable restoration (Mahoney *et al.*, 2008).

Some parents/guardians find the appearance of the SSC to be unacceptable, so a SSC should be shown when informed consent is being obtained. With uncooperative behavior, an SSC is preferable to an esthetic crown, as an esthetic crown requires extensive tooth reduction that may create the need for vital pulpotomy and, in general, requires longer chair time. After administering local anesthesia and rubber dam placement, primary molar preparation and crown cementation for an SSC can usually be performed in less than 10 min.

Precontoured SSCs accurately duplicate the anatomy of the primary molars and require no buccal or lingual reduction during crown preparation. They provide a highly retentive “snap” fit. These SSCs are ready for immediate use, and unlike uncountoured SSCs, which must be customized with trimming and contouring for adaption, they significantly reduce chair time (Figure 5.1).

Procedure for SSC

- Administer local anesthesia.
- Place rubber dam with slit technique and reduce occlusal surface 1 mm with size 6 or 8 carbide round bur with high speed (Figure 5.2).
- Perform subgingival interproximal reduction with 169 L or 170 L carbide bur with high speed (Figure 5.3).

When prepping the distal of a second primary molar, use caution to avoid disking the mesial of the adjacent first permanent molar. A wooden wedge, placed between the first permanent molar and the second primary molar, will provide protection for the mesial surface of the first permanent molar. Cut just inside distal marginal ridge and the mesial side of the wooden wedge (Figure 5.4). Remove the wedge and check for a white spot lesion on the mesial of the first permanent molar (Figure 5.5). If decalcification is noted, fluoride varnish may be applied as a courtesy.

- If the first permanent molar is unerupted and the rubber dam clamp must be placed on the second primary molar, a spoon curette may be used to retract the rubber dam from the distal of the second primary molar during distal interproximal preparation (Figure 5.6).
- Check for a ledge on the mesial and distal. Ledges inhibit crown seating (Figure 5.7).
- Selecting a crown:
Size 4 is most commonly used.



Figure 5.1 Precontoured stainless steel crown and uncountoured stainless steel crown.

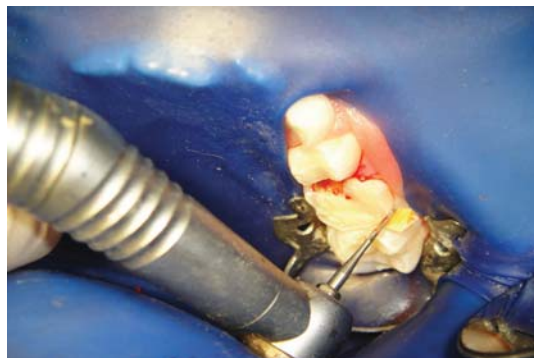

Figure 5.4 Distal reduction of second primary molar with wooden wedge to protect mesial of first permanent molar.

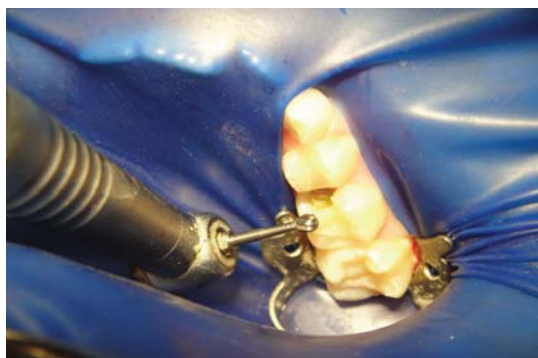

Figure 5.2 Rubber dam with slit technique for 1-mm occlusal reduction with size 8 carbide round bur with high speed.

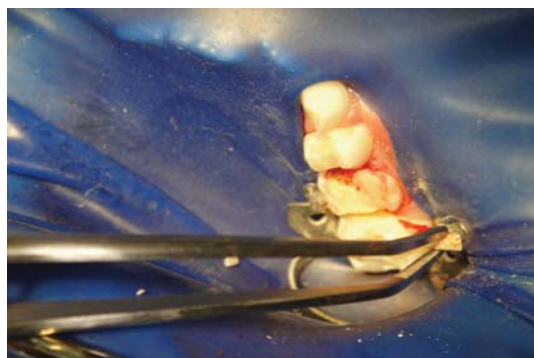


Figure 5.5 Removing wedge and checking mesial of first permanent molar for white spot lesion.

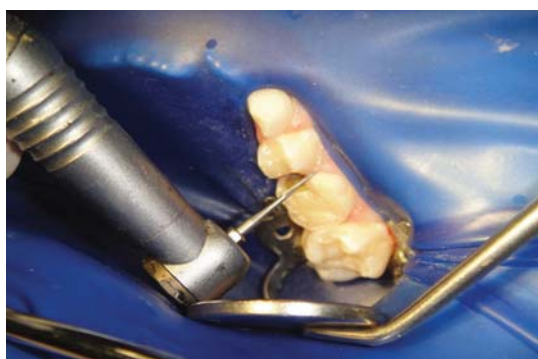

Figure 5.3 Subgingival interproximal reduction with 169L carbide bur with high speed.

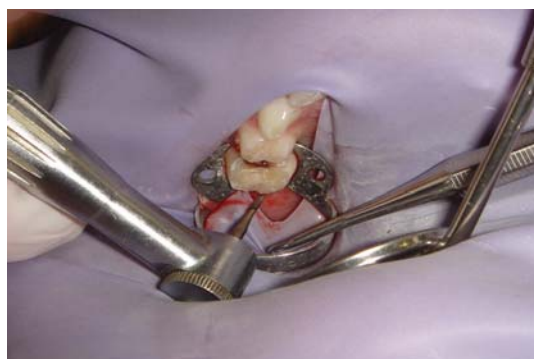

Figure 5.6 Retracting rubber dam with spoon for distal preparation of second primary molar if first permanent molar unerupted.

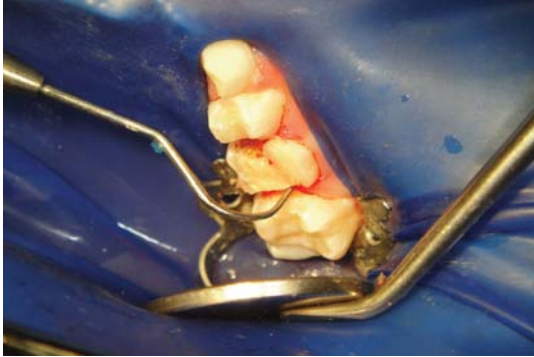

Figure 5.7 Checking for ledge with explorer.

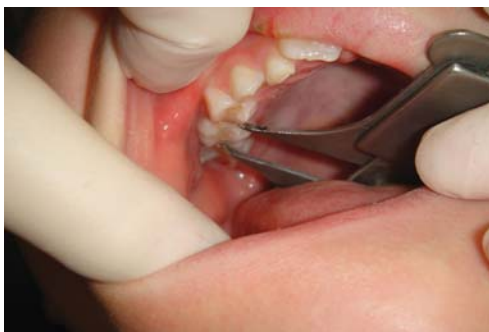Measuring the mesial–distal width of the primary molar before preparation with a boley gauge may be helpful to select the correct size SSC. Using this measurement, an SSC is selected (Figure 5.8a and 5.8b). After performing the SSC procedure a few times, the clinician will be able to visually estimate the size, and measuring for size selection will no longer be necessary.

- Place the SSC on the tooth, but do not fully seat the crown with the try-in. Check that SSC covers the entire crown of the primary molar. If fully seated with “snap” fit, it may be very difficult to remove (Figure 5.9).
- Place the cement of choice inside the crown – carbonylate cement or glass ionomer (GI) is typically used. The wooden end of a cotton-tipped applicator may be used to coat the inside of the crown with the cement (Figure 5.10). Overfilling will result in extrusion of cement and requires more clean-up.

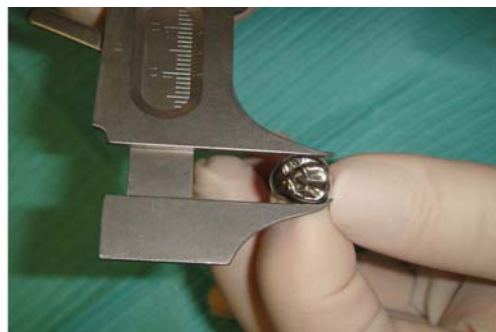
- Initially, the crown is seated by the operator using a bite stick (Figure 5.11). If the crown is not fully seated with a “snap” fit with digital pressure on the bite stick and the child is capable of cooperating, the rubber dam is removed and the child is instructed to bite on the bite stick as hard as possible (Figure 5.12). The bite stick may initially be placed in the center of the occlusal surface of the crown and then moved to the buccal and lingual of the occlusal surface for final seating. Check to be sure that the child’s lip is not trapped under the bite stick.
- Gingival tissue may blanch after seating, but this will resolve.
- Cement is cleaned from the crown and gingival tissues with wet 2 × 2 gauze (Figure 5.13).
- Tie five to seven knots segmentally in a strand of floss and pull through the mesial and distal embrasures to remove any excess cement from that area (Figure 5.14).

With difficulty fitting

If space loss has occurred as a result of caries, it may be necessary to reduce the size of an SSC mesial–distally with a Howe plier (Figure 5.15). Because SSCs are not available in half sizes; crimping may be necessary. Crown collars may be crimped with crown and band contouring pliers or band crimping pliers, which perform equally well (Figure 5.16a and 5.16b). If unable to find a crown to fit a first primary molar, try a crown from the opposite arch and opposite (contralateral) side. For instance, if unable to find a suitable fit for a maxillary right first primary molar, a crown for a mandibular left first primary molar may be a good fit.



(a)



(b)

Figure 5.8 (a) Boley gauge to measure mesial–distal width of primary molar. (b) Boley gauge to measure mesial–distal width of stainless steel crown.

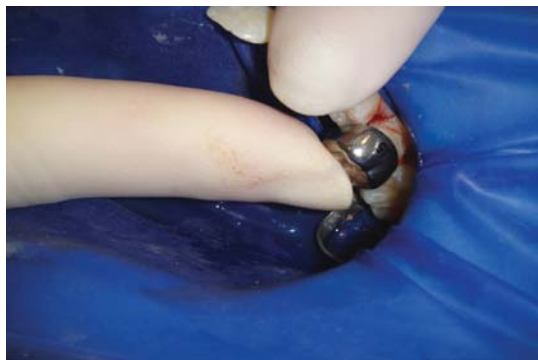

Figure 5.9 Stainless steel crown checked for size before fully seating.

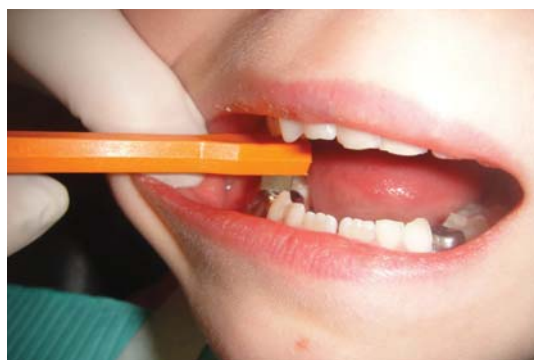

Figure 5.12 Child biting on bite stick to seat stainless steel crown.

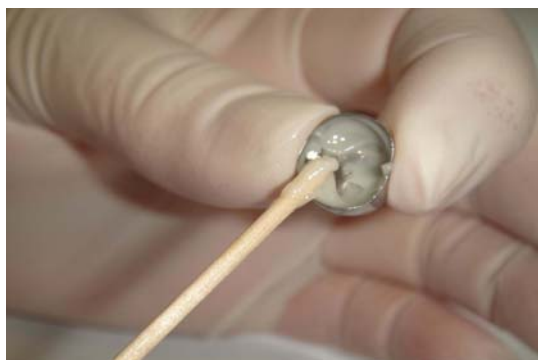

Figure 5.10 Wooden end of cotton-tipped applicator to line inside of stainless steel crown with cement.

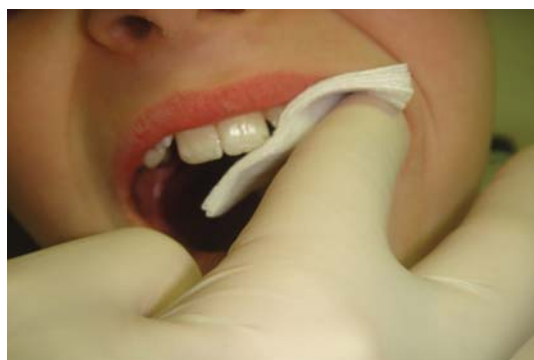


Figure 5.13 Cleaning stainless steel crown and gingiva with wet 2 × 2 gauze.

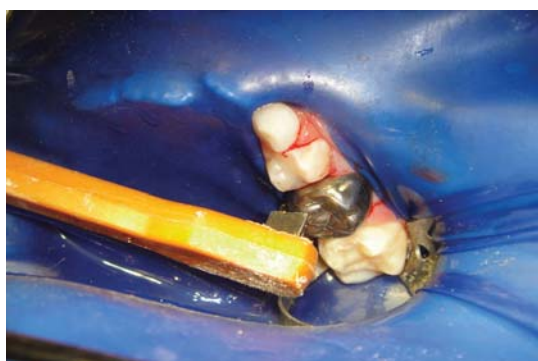

Figure 5.11 Operator seating the stainless steel crown with a bite stick.

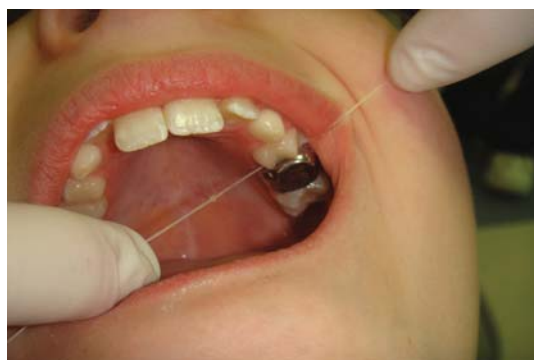

Figure 5.14 Floss with knots tied segmentally to remove interproximal cement.



Figure 5.15 Howe plier to reduce mesial–distal size of stainless steel crown.

Hall Technique

The Hall technique, developed in the United Kingdom, offers a simplified technique for the stainless steel crown procedure without the use of local anesthesia, tooth preparation or caries excavation. In one study, primary molars with caries extending greater than half-way into dentin radiographically were restored with either Hall technique or standard restorations. The study concluded that Hall technique, both statistically and clinically, was more successful. (Innes et al, 2011) Marginal seal significantly influences crown longevity. In another study, using precontoured and pretrimmed stainless steel crowns (3M ESPE), microleakage was significantly higher with the Hall technique than with conventional technique. Regardless of the technique, resin cement showed the lowest microleakage scores followed by conventional glass ionomer and polycarboxylate cements. Buccal margins resulted in higher microleakage

scores than lingual margins for both techniques. (Erdemci, et al, 2014).

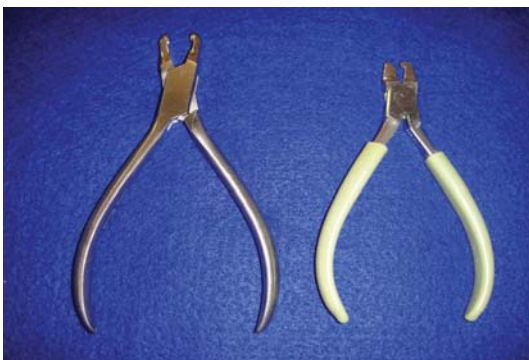Esthetic crowns

When parents/guardians have strong opposition to the appearance of the traditional SSC, preveneered and zirconia crowns offer an esthetic alternative. These crowns are more expensive and require extensive tooth reduction, sometimes creating the need for a vital pulpotomy. Step-by-step clinical instruction may be found on the company's website, laminated cards with step-by-step instruction, or on a DVD from the manufacturer.

Preveneered stainless steel crowns

Preveneered crowns (NuSmile Signature, Kinder Crowns, Cheng Crowns) are SSCs with composite facings. Light (B1) and extra light (bleached) shades may be available (Figure 5.17). Preparation of the tooth is more extensive than with SSCs because the veneer is added on to the SSC. The inside of the preveneered crown may be sand blasted by the manufacturer to enhance bonding (Figure 5.18). The required interproximal reduction may result in a pulp exposure and need for vital pulpotomy. With inadequate tooth reduction, preveneered crowns can appear bulky. Inability to cooperate for the longer procedure, deep bite, and bruxing may prohibit use of the preveneered crown.

Disadvantages include cost, inability to crimp on buccal or modify the crown mesio-distally with marked mesio-distal loss of tooth structure due to caries, and fracture or chipping of facings. Adequate occlusal reduction is mandatory to assure light occlusal contact



(a)



(b)

Figure 5.16 (a) Crown and band contouring and crimping pliers. (b) Crimping a stainless steel crown with pliers.



Figure 5.17 Two shades of preveneered stainless steel crowns (photo courtesy of NuSmile Crowns).

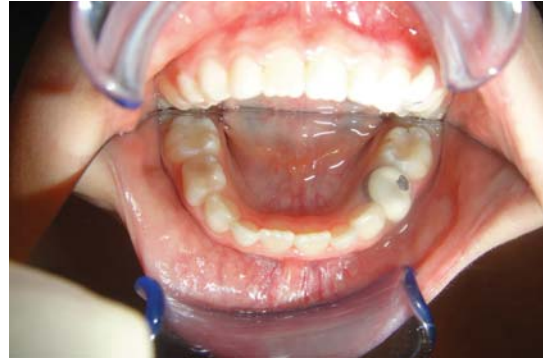

Figure 5.19 Chipped facing on preveneered stainless steel crown.



Figure 5.18 Inside view of sand-blasted preveneered stainless steel crown (photo courtesy of NuSmile Crowns).

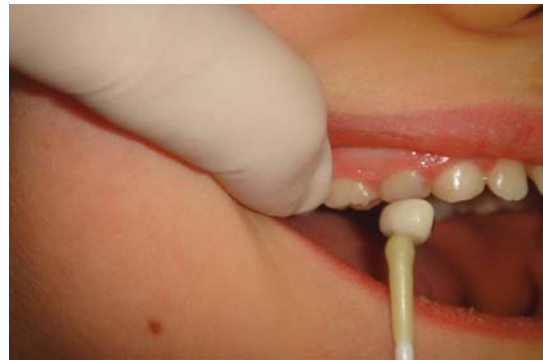

Figure 5.20 Selecting size for preveneered crown.

in centric and excursive movement. With bruxing or excessive deep bite, a stainless steel or zirconia crown may offer a better choice to avoid chipping of the facing.

Heavy occlusal contacts or bruxing can result in fracture of the composite facing. Ram *et al.* (2003) found chipping of facings after 4 years (Figure 5.19). To repair a chipped facing, remove the exposed stainless steel with a high-speed bur, place an opaquer or a resin-modified GI, and follow with light-cured composite resin matching the shade of composite facing.

Informed consent should include possible chipping or loss of facings, longer time required for procedure, and possible addition of a pulpotomy to the treatment plan.

Procedure for preveneered SSC

Select the crown size before beginning the tooth preparation. Use cotton forceps or a Pic-n-Stic (Pulpdent Corporation) to hold a preveneered crown next to

the primary molar to be restored (Figure 5.20). The preveneered crown will be one to two sizes smaller than a traditional SSC for the same tooth in order to accommodate the addition of the composite facing. Choose a size that looks most similar to the child's tooth.

- Administer local anesthesia and place a rubber dam.
- Reduce occlusal 2 mm with a coarse football diamond or donut diamond bur (Figure 5.21a and 5.21b).
- Reduce mesial and distal with fine tapered diamond or 169L carbide bur, opening interproximal contacts, and begin circumferential reduction (Figure 5.21c).
- Reduce buccal and lingual with coarse tapered round end diamond or carbide bur (Figure 5.21d).
- Extend a circumferential feather-edge margin about 2 mm subgingivally with a fine tapered round end diamond bur (Figure 5.21e).

Overall primary molar reduction is about 30%. Be sure to remove the mesial buccal bulge on the first primary

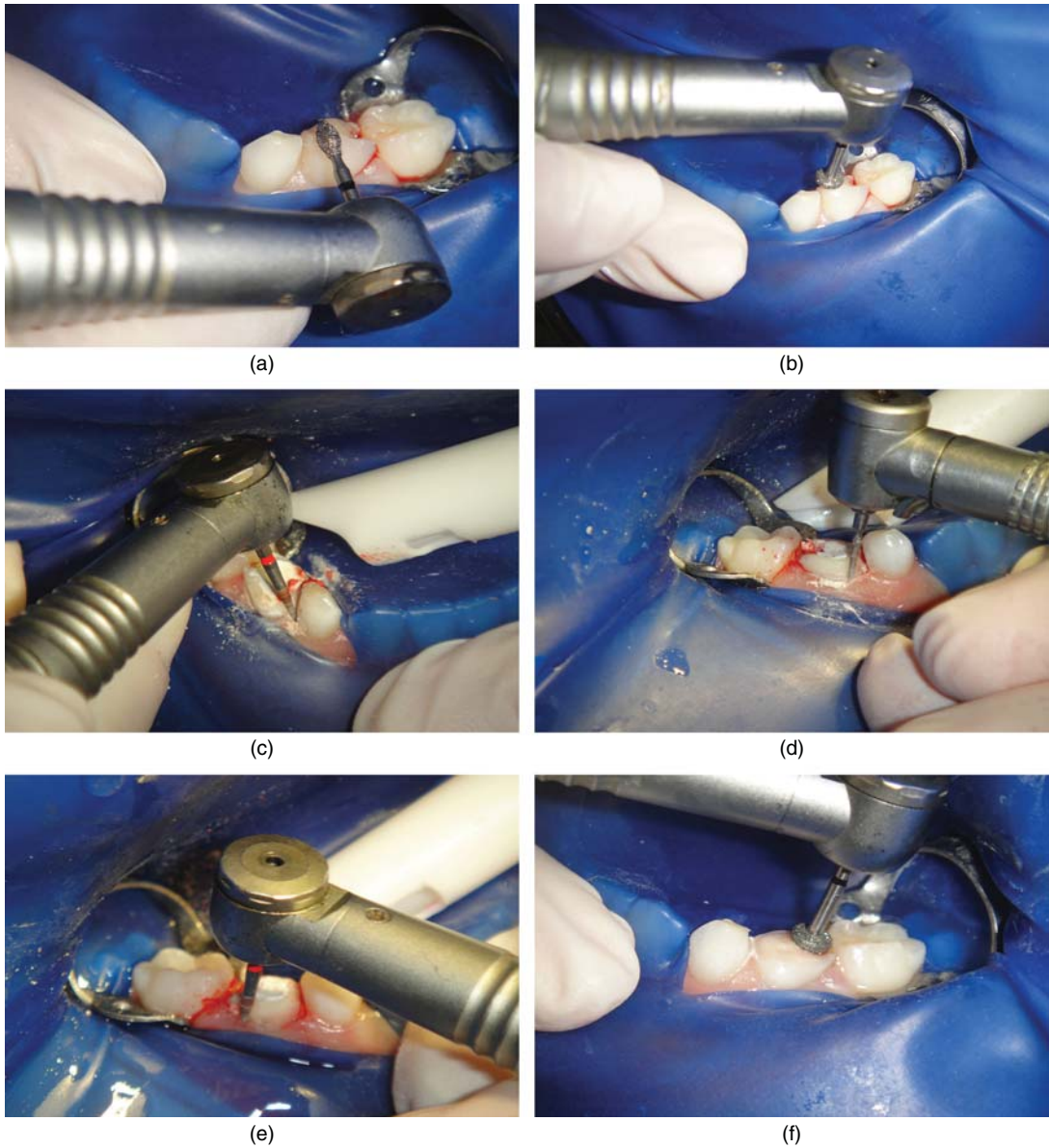


Figure 5.21 (a) Coarse football diamond bur for 2-mm occlusal reduction. (b) Donut diamond bur for 2-mm occlusal reduction. (c) Fine tapered diamond bur for mesial and distal reduction. (d) Coarse tapered round end diamond bur for buccal and lingual reduction. (e) Fine tapered round end diamond bur for circumferential feather-edge 2 mm below gingival margin. (f) Donut diamond bur to check depth of occlusal reduction. (g) Patient biting on cotton roll until cement sets. (h) Checking occlusion with articulating paper. (i) Adjusting occlusion with white stone. (j) Preveneered crown after cementation and checking occlusion with articulating paper.

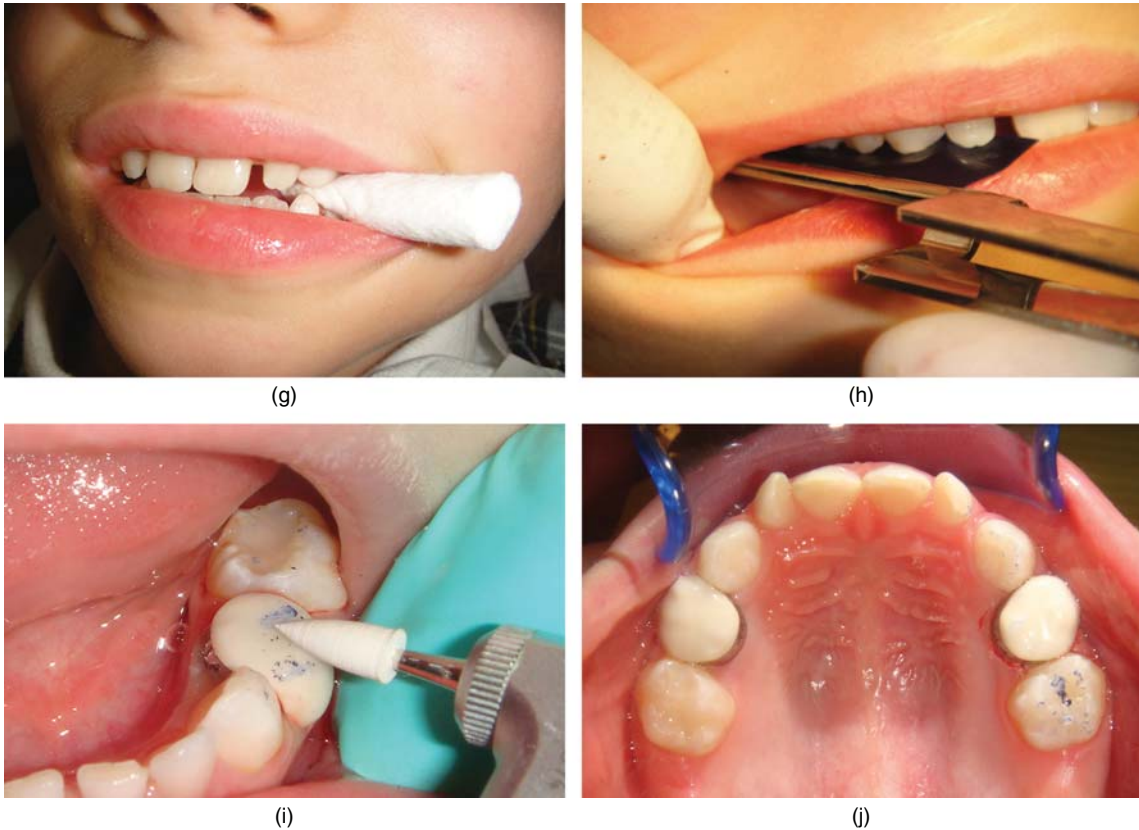


Figure 5.21 (Continued)

molar. This step will create a smaller preparation and better fit with a less bulky appearance.

- Check that occlusal reduction is 2 mm before try-in. A 2-mm-thick donut diamond bur may be used to check the depth of the reduction or the margin of the adjacent primary molar (Figure 5.21f).
- Crowns are passively seated with light digital pressure.
- If doing more than one crown, try-in all crowns at the same time, in case additional mesial–distal reduction is required.
- Clean all blood and saliva from the inside of the crown.
- Fill the crown completely with GI cement, or cement of choice, to prevent voids.
- The crown is seated passively with finger pressure only. There is no “snap” fit as with the traditional SSC, and the collar cannot be crimped. The crown collar should be subgingival.
- The patient bites on a cotton roll or a cotton-tipped applicator to stabilize the crown until cement is set, according to material’s setting time (Figure 5.21g).
- Clean with wet 2 × 2 gauze and floss with segmentally tied knots.
- Check the occlusion in centric and excursive movements with articulating paper (Figure 5.21h).
- Adjust the composite facing with a white stone or composite finishing bur (Figure 5.21i). The crown of the opposing primary molar may also be slightly adjusted.
- Check with articulating paper to assure light or no contact on composite facing (Figure 5.21j).

Common problems

Inadequate buccal reduction will cause the crown to appear bulky. Inadequate preparation below gingival

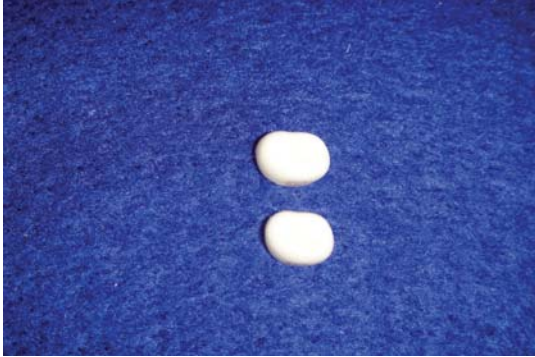

Figure 5.22 Zirconia crown for mesial–distal space loss compared to regular mesial–distal crown width.

margin will impede seating the crown fully and cause occlusion to be high.

Zirconia crowns

Zirconia crowns (NuSmile, EZPedo, Cheng Crowns, Kinder Krowns) are prefabricated, exceptionally strong ceramic and offer the most esthetic, biocompatible full coverage primary molar crown. They are anatomically contoured and metal free. The cervical margin is knife edge to preserve gingival health, and plaque accumulation is reduced with the highly polished finish. Wear is comparable to natural enamel. Depending on the company where purchased, the crowns may be supplied in one universal shade, with additional color added to the cervical and occlusal surfaces or in shades extra light and light. The light shade is closer to an A1 or B1 shade and usually a better match. Both E-Z Pedo and NuSmile offer a narrower crown mesial–distally, with a “squished” design, for first primary molars with space loss due to caries (Figure 5.22). Zirconia crowns cannot be crimped and are not flexible. Passive fit is mandatory. Attempting to seat a zirconia crown with force will result in fracture. Adjustment with a bur will result in microfracture; remove glaze or create weakened areas. Meticulous attention to proper tooth preparation is necessary.

Procedure for zirconia crown

Size selection is done before the preparation. The esthetic advantage may be nullified with a crown that looks too large. Choose the correct size crown for the space and evaluate occlusal relationship. Size selection may be accomplished by holding a zirconia crown next

to the primary molar to be prepped or with a NuSmile pink try-in crown (Figure 5.23a and 5.23b).

The preparation of the tooth for the zirconia crown takes more time, and so this crown would not be recommended for children who are fearful or unable to cooperate for a longer procedure. The preparation is similar to the veneered crown but with more reduction in tooth structure.

- A football or donut (wheel) diamond bur is used for 1–2 mm of occlusal reduction, depending on the manufacturer’s instructions, following the natural occlusal contours. The use of the marginal ridge of adjacent teeth can provide a good reference point. Adequate occlusal reduction will permit sufficient subgingival margin placement and correct occlusal plane.
- A coarse round end tapered diamond bur is used for circumferential reduction, starting at the gingival margin and opening the interproximal contacts.

Interproximal reduction is more extensive than the preparation for a traditional SSC. Mesial and distal line angles should be rounded.

Zirconia crowns do not flex and are slightly thicker than the traditional SSC. If adjacent crowns are being placed, the interproximal reduction will be much more extensive. Consent should include first primary molar pulpotomy, as a pulp exposure will likely occur as a result of greater distal reduction.

The entire clinical crown or axial circumference will be reduced by 20–25% (0.5–1.5 mm), according to the manufacturer’s instruction. The preparation will be parallel, converging slightly to the occlusal. Be sure to completely remove the mesial buccal bulge on the first primary molar. This step will create a smaller preparation collar and an easier fit.

- A fine, thin round end tapered diamond bur is used to refine the preparation margin to a feather-edge 1–2 mm subgingivally to the cemento-enamel junction (important step).
- Round all line angles.
- The completed preparation should appear ovoid when viewed from the occlusal. All line angles should be rounded and blended (Figure 5.24).

Common problems with preparation

- Inadequate subgingival preparation. Margins should be feather edge with no undercuts and no ledges. Adequate subgingival extension of 1–2 mm ensures that the crown margin will not be exposed and

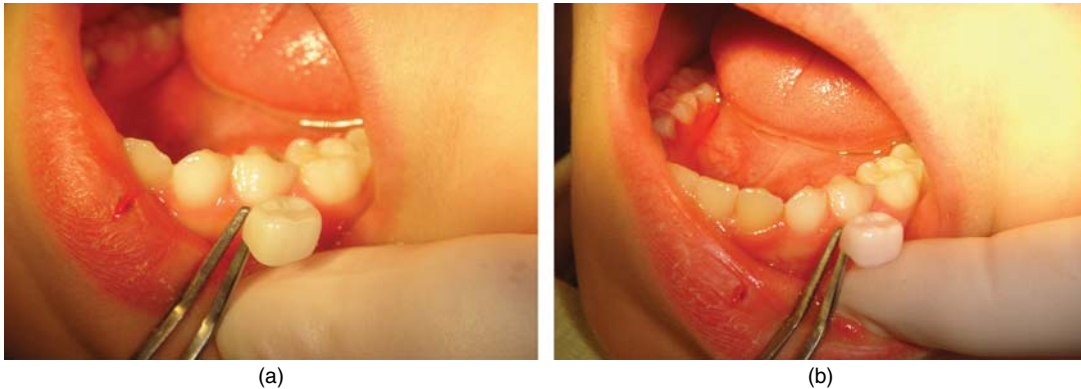

Figure 5.23 (a) Comparing zirconia crown to primary molar for size selection. (b) Pink try-in zirconia crown for size selection.

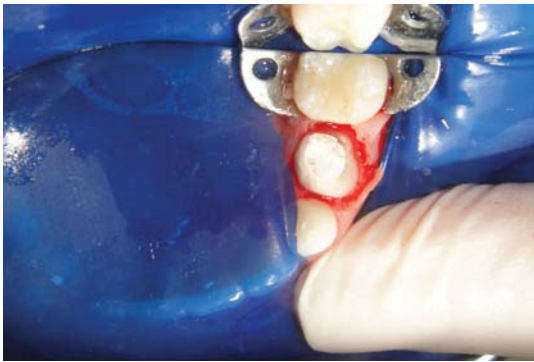

Figure 5.24 Ovoid shape of crown after preparation.

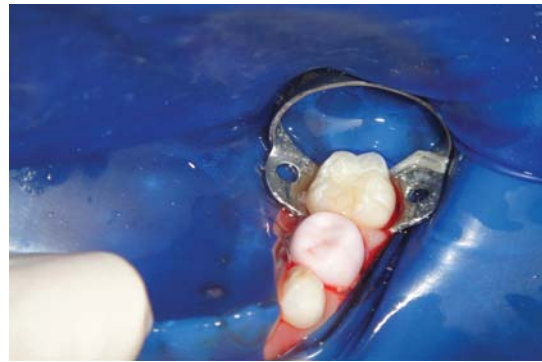

Figure 5.25 Pink try-in zirconia crown on prepared primary molar.

ensures healthy gingival margins and improved retention. Use of a thin, fine grit tapered diamond bur avoids tissue maceration.

- Inadequate preparation around the cervical collar of the tooth. Proper reduction with this step will not only make prep smaller, but also permit the use of a crown closer in size to the original tooth.
- Inadequate removal of mesial buccal bulge.
- Inadequate interproximal reduction. Keep the bur vertical with the long axis of the molar to assure adequate subgingival reduction. Round off line angles and vertical walls as they converge toward the occlusal.
- Slanting bur for preparation. The bur should be vertical at all times during preparation.
- Differing planes of buccal and lingual reduction. Both should converge slightly toward the occlusal.

- Internal binding if vertical walls are not rounded near the occlusal.

Try-in

Zirconia crowns, analogous to veneered crowns, have a passive fit and are placed with digital pressure only. Forceful seating will fracture a zirconia crown. A pink try-in crown will avoid contaminating the zirconia crown to be used with blood and saliva (Figure 5.25). Try-in crowns can be sterilized for repeat use. Occlusion is checked. Occlusal or interproximal adjustment will remove glaze and create weakened areas with thin ceramic. If occlusion is high, the collar may be reduced with a high-speed fine diamond bur with copious water coolant; excessive heat may cause microfracture of zirconia. Additional occlusal reduction of the primary

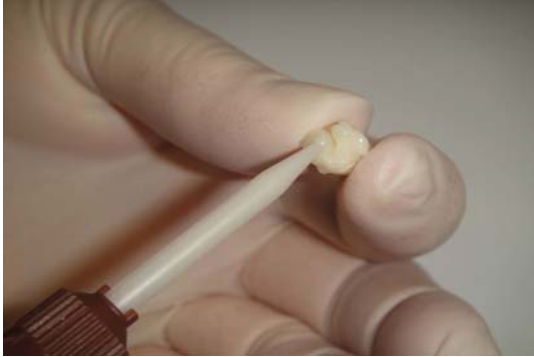

Figure 5.26 Filling the zirconia crown fully with cement to eliminate voids.

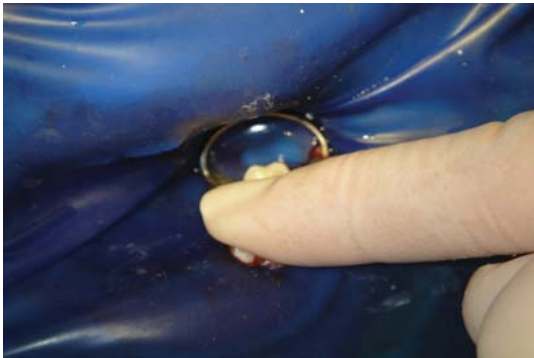


Figure 5.27 Digital pressure holding zirconia crown in place until cement sets.

molar is preferable to attempting to shorten the zirconia crown.

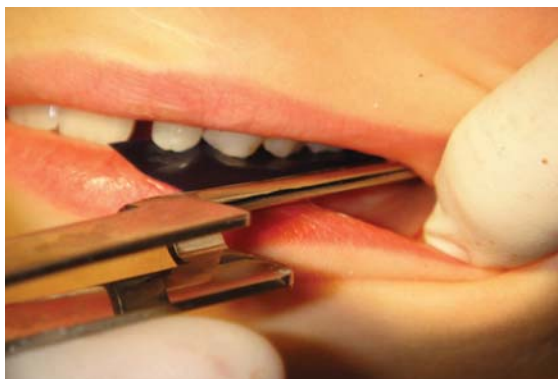
Cementation

Rinse the tooth thoroughly, removing all saliva and blood. Saliva will bind to the internal surface of the zirconia crown and impede the cement bond. Blood may show through zirconia; hemostasis must be achieved before cementation. If a pink try-in crown was not used, clean the inside of crown with alcohol, peroxide, Ivoclean (Vivadent), or sandblast with aluminum oxide before placing cement.

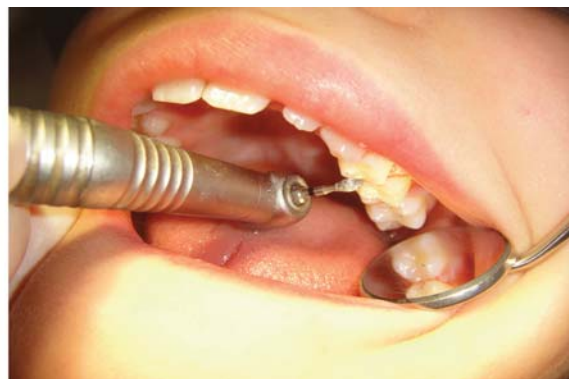Completely fill the crown with a resin-modified glass ionomer (RMGI) or GI cement to eliminate voids (Figure 5.26). Seat the crown subgingivally with digital pressure only. Do not permit the patient to bite the crown down into occlusion. The crown should be stabilized with firm finger pressure during the cement's set; movement will interfere with optimal bonding to the tooth, and hydrostatic forces of the cement may lift the zirconia crown away (Figure 5.27).

Pure GI cement is less expensive than RMGI. However, as the marginal seal of the zirconia crown is not seamless, pure GI cement may degrade more rapidly. Carboxylate cement (3M-ESPE) has also been successfully used.

After cementation, check occlusion with articulating paper (Figure 5.28a). If the occlusion is high, it is preferable to reduce the occlusal contact on in the opposing primary molar (Figure 5.28b).



(a)



(b)

Figure 5.28 (a) Checking occlusion with articulating paper. (b) Adjusting occlusion of the opposing primary molar.

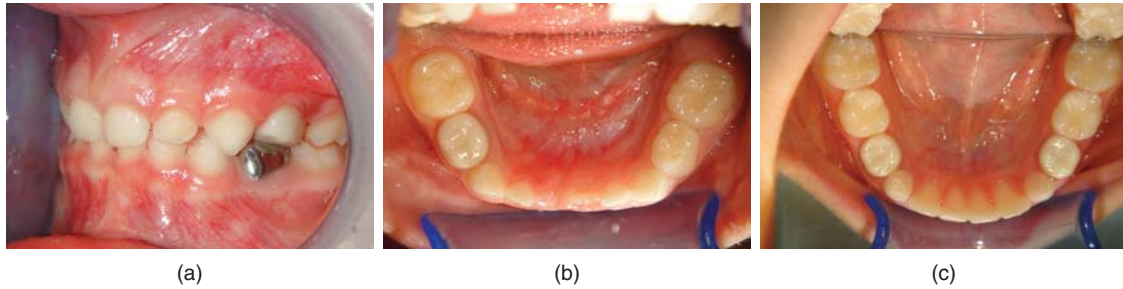


Figure 5.29 (a) Zirconia crown first primary molar in maxilla compared to stainless steel crown first primary molar in mandible. (b) Occlusal view of zirconia crown mandibular right first primary molar. (c) Occlusal view of zirconia crowns mandibular right and left first primary molars.

The crown size, which may be imprinted on the buccal or lingual surface of the crown, may be removed with a spoon or coarse prophylaxis paste. Zirconia crowns may be autoclaved for sterilizing.

With proper preparation and cementation, zirconia crowns offer unparalleled esthetics (Figure 5.29a, 5.29b, and 5.29c).

Preveneered versus zirconia

Bruxing – zirconia

Deep bite with short crowns – zirconia

Unable to control gingival bleeding – veneered

Need a smaller size – can crimp veneered on lingual

Minimal tooth structure remaining – veneered due to smaller crown size (internal dimensions) is usually used for the similar exterior dimensions.

References

American Academy of Pediatric Dentistry. Guideline on pediatric restorative dentistry. *Pediatric Dentistry*, 2014; **36** (special issue), 230–241.

Erdemci, Z.Y., Cehreli, S.B. & Tirali, R.E. (2014) Hall versus conventional stainless steel crown techniques: In vitro investigation of marginal fit and microleakage using three different luting agents. *Pediatric Dentistry*, **36**, 286–290.

Innes, N.P., Evans, D.J. & Stirrups, D.R. (2011) Sealing caries in primary molars: randomized control trial, 5-year results. *Journal of Dental Research*, **90**, 1405–1410.

Mahoney, E., Kilpatrick, N. & Johnston, T. (2008) Restorative paediatric dentistry. In: Cameron, A.C. & Widmer, R.P. (eds), *Handbook of Pediatric Dentistry*, 3rd edn. Mosby, London, pp. 341–377.

Ohlimoba, H.O. & Nelson, L.P. (2013) A performance measurement plan for pediatric dentists: using accuracy of caries diagnosis from intraoral radiographs. *Pediatric Dentistry*, **35**, 27–32.

Ram, D., Fuks, A.B. & Eidelman, E. (2003) Long-term clinical performance of esthetic primary molar crowns. *Pediatric Dentistry*, **25**, 582–584.

6

Vital pulp therapy for primary molars

Jane A. Soxman

The goal of vital pulp therapy is to remove the infected coronal pulp tissue while preserving the healthy radicular pulp. Vital pulp therapy is recommended in primary molars with extensive caries, complaint of unprovoked spontaneous pain, and with carious or mechanical pulp exposure during caries excavation. Vital pulp therapy is contraindicated with radicular pathology, a sinus tract due to abscess, excessive mobility, presence of purulent material or necrosis in the coronal pulp chamber, or inability to obtain complete hemostasis when performing the pulp therapy (American Academy of Pediatric Dentistry, 2014; Winters *et al.*, 2008). The use of a model to describe the pulpotomy procedure to a parent/guardian when obtaining informed consent for the procedure is helpful. Informed consent should include the need for local anesthesia, rubber dam, and a full-coverage crown (Kilgore International) (Figure 6.1a, b).

Radiographic evaluation

A periapical radiograph should be obtained before performing vital pulp therapy to confirm the health of the radicular pulp, internal or external root resorption, and evaluate caries progression if a period has elapsed since the initial treatment plan (Figure 6.2a). Internal resorption is always associated with extensive inflammation in the primary dentition. The roots of the primary molar are very thin; if internal resorption can be seen

on a radiograph, a perforation has usually occurred, and extraction is indicated. The same criteria apply for external resorption (Camp, 2011) (Figure 6.2b).

Local anesthesia

Local anesthesia with infiltration in the maxilla and inferior alveolar nerve (IAN) block in the mandible should be administered. In some cases, buccal infiltration alone may provide adequate anesthesia in the mandible, but if a child is crying from the outset, IAN should be performed. If the child appears to be comfortable, with no complaint of pain until the pulp chamber is uncovered, providing immediate additional local anesthesia is indicated. If the discomfort is minimal, a few drops of 2% xylocaine with 1 : 100,000 epinephrine dispensed into the coronal chamber provides adequate anesthesia to continue the procedure without another injection.

Rubber dam isolation

The rubber dam should be routinely used when performing vital pulp therapy. The rubber dam provides a throat partition and protects the oral tissues from exposure to medicaments or injury with the bur or instruments. Multiple colors, nonlatex, and varying thicknesses in 5 × 5 in.² pediatric size are available. The

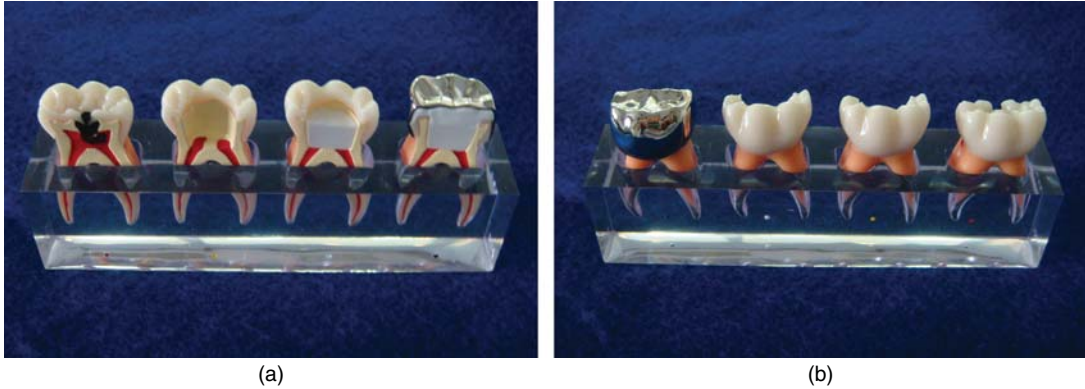

Figure 6.1 (a, b) Pulpotomy and stainless steel crown model viewed from different sides.

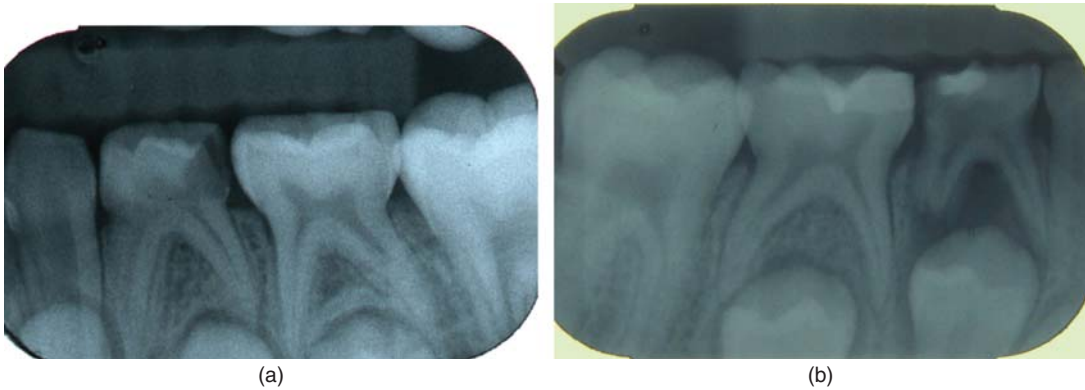


Figure 6.2 (a) Periapical radiograph of mandibular left first primary molar with carious pulpal involvement. (b) Periapical radiograph with internal and external root resorption.

use of a thicker gage rubber dam may provide a better seal around the clamp and improved retraction of the surrounding oral tissues. The rubber dam clamp should be ligated with floss to facilitate retrieval should the clamp become dislodged before or during placement of the rubber dam. The W8A rubber dam clamp is typically an ideal fit for a second primary molar (Figure 6.3). If there is difficulty placing the rubber dam over the clamp intraorally, a winged clamp may be used. The rubber dam is placed on the clamp extraorally and then placed on the molar as a single unit with the rubber dam forceps (Figure 6.4a and 6.4b). The portion of the rubber dam covering the wings of the clamp is slipped off with an instrument and tucked beneath the wings for good moisture control (Figure 6.4c). Because the tooth is anesthetized, the rubber dam may be referred to as a

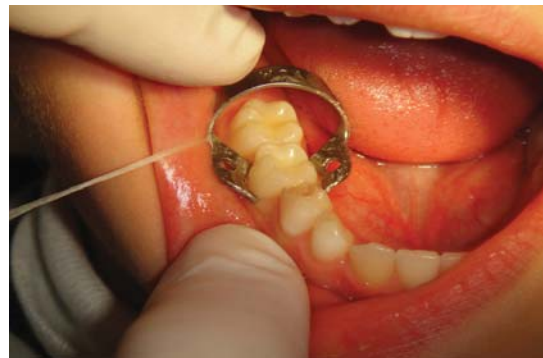

Figure 6.3 W8A rubber dam clamp ligated with floss.

blanket, to cover the sleeping tooth, when performing “Tell–Show–Do” with a young child. The slit technique may be used to restore a quadrant (Figure 6.5).




Figure 6.4 (a) Rubber dam placed on winged clamp extraorally. (b) Rubber dam and winged clamp placed intraorally as a unit. (c) Removing rubber dam from wings of clamp.

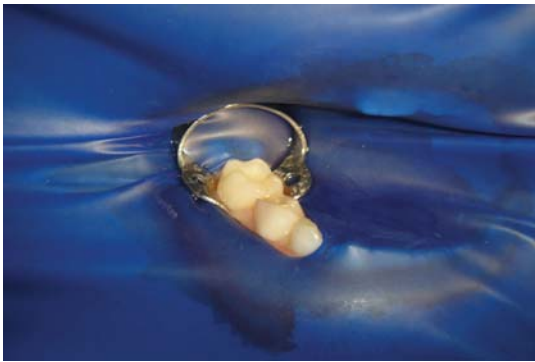


Figure 6.5 Slit technique for rubber dam with floss ligated to clamp under rubber dam.

Procedure

Complete caries removal is recommended before entering the coronal pulp. By removing the peripheral caries and prepping from the periphery toward the

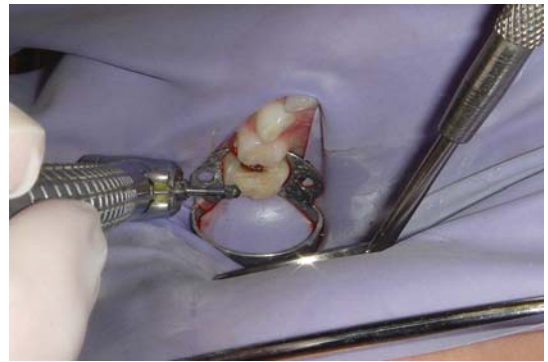


Figure 6.6 Occlusal reduction with large round bur.

pulp chamber, the infected tissues will not further contaminate the coronal pulp (Winters *et al.*, 2008).

A full-coverage crown is the restoration of choice. Occlusal reduction recommended for the type of crown selected (stainless steel, zirconia, or preveneered) is performed before unroofing the coronal pulp (Figure 6.6).

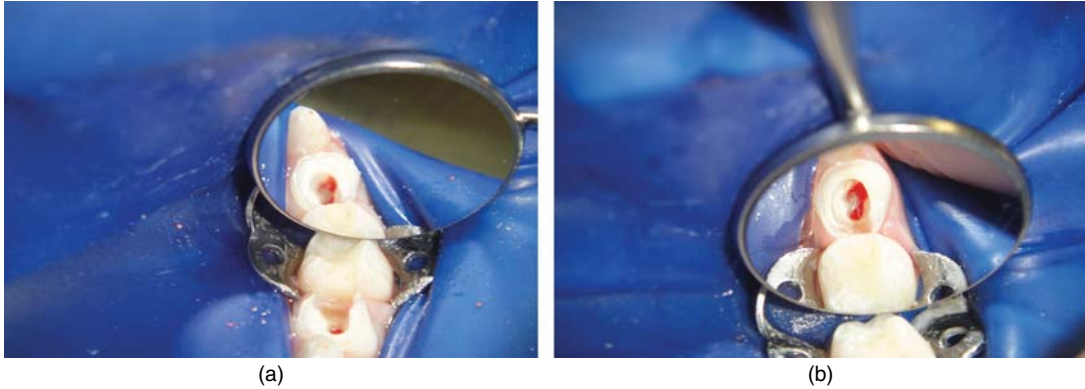


Figure 6.7 (a) Access opening inadequate to visualize all canal orifices. (b) Enlarged access opening.

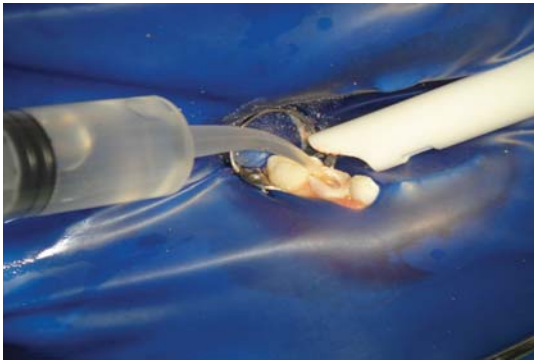

Figure 6.8 Irrigation with monoject syringe.

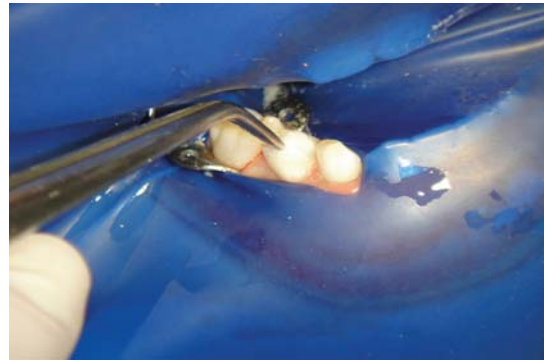

Figure 6.9 Application of sterile cotton pellets.

After entering the coronal pulp chamber, the pulp tissue is carefully removed to the root canal orifices. Create a large access opening to permit visualization of all canal orifices and remove ledges that could hide tissue tags (Figure 6.7a and 6.7b).

A monoject syringe is used for irrigation with sterile saline, sodium hypochlorite, chlorhexidine, or an irrigant of choice. Using water from the dental unit air-water syringe is discouraged unless that water is sterile (Figure 6.8).

Sterile cotton pellets are used to apply pressure and dry the pulp chamber. Size 3 cotton pellets provide more pressure for heme control and are more absorbent (Figure 6.9).

A sterile curette may be used to excavate tissue tags causing continued bleeding (Figure 6.10). Follow with irrigation and application of sterile cotton pellets.

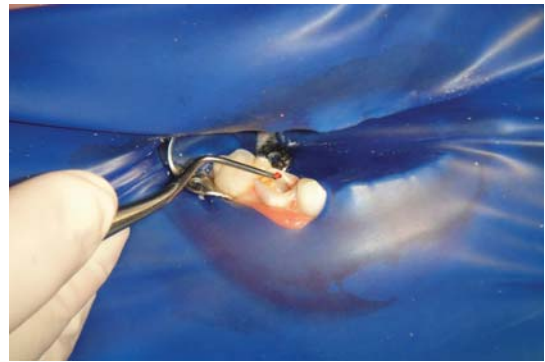

Figure 6.10 Curette to remove tissue tag.

Complete hemostasis must be obtained before the medicament of choice is applied. Extensive bleeding indicates degenerative changes; vital pulp therapy is contraindicated. Pulpectomy or extraction should be performed (Winters *et al.*, 2008) (Figure 6.11).

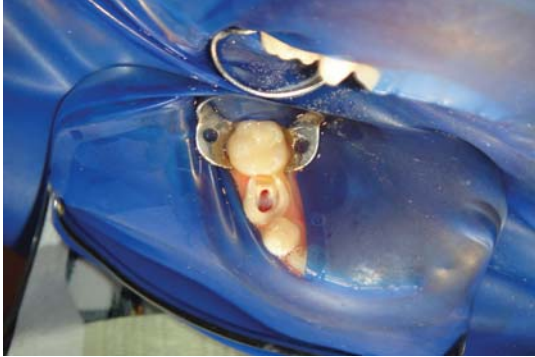


Figure 6.11 Complete hemostasis.

Medicaments

Primary molar pulpotomy requires a vital radicular pulp, no matter what medicament is used. If the pulp chamber is dry, has an odor, or contains purulent material, extraction is indicated (Seale & Coll, 2010). Various medicaments, along with electrosurgery and laser, have been evaluated with numerous clinical trials. A bioactive cement, Biodentine (Septodont) similar to mineral trioxide aggregate (MTA), has recently been introduced as a medicament. Sodium hypochlorite is an effective hemostatic and bacteriocidal agent that selectively dissolves superficial necrotic tissue without harming deeper tissue. Shabzendedar *et al.* (2013) found that a solution of 3% sodium hypochlorite resulted in the same clinical and radiographic outcomes as diluted formocresol. Another recent study reported that if pulpal hemostasis can be obtained within 60 s with a dry cotton pellet, the use of any medicament may not be necessary (Hui-Derksen *et al.*, 2013).

The two agents most studied with clinical trials are formocresol and ferric sulfate. Eighty-two percent of residency programs still teach the use of formocresol for pulpotomy. Ferric sulfate and MTA ranked next in use (Walker *et al.*, 2013).

Ferric sulfate

Ferric sulfate is a hemostatic agent that agglutinates blood proteins. The blood reacts with both ferric and sulfate ions, and the agglutinated protein forms plugs that occlude the capillaries. It provides similar outcomes to formocresol but offers a nonaldehyde option for those who are concerned about controversy with the use of formocresol. The solution is 15.5% in an aqueous base

with a pH of 1 (Fuks, 2012). Ferric sulfate is burnished onto the pulp stumps for 10–15 s, rinsed away and dried with cotton pellets. With decomposition, ferric sulfate becomes sulfuric acid, which can cause severe burns with contact of oral tissues outside of the coronal pulp chamber (Winters *et al.*, 2008).

MTA

MTA is a mixture of tricalcium silicate, tricalcium aluminate, tricalcium oxide, bismuth oxide, dicalcium silicate, and calcium sulfate. It is highly alkaline with a pH of 12.5 (Fuks, 2012). It is packaged in a powder form and mixed with sterile water to form a paste. MTA has shown clinical success rates similar to formocresol and ferric sulfate (Winters *et al.*, 2008). Erdem *et al.* (2011) found that MTA resulted in higher radiographic success at 2 years than ferric sulfate or formocresol. The primary advantage of MTA is an excellent seal provided against bacterial migration, but expense and setting time of about 3 h are drawbacks. MTA is covered with a base material such as intermediate restorative material (IRM) before final restoration. MTA dust may cause ocular damage and irritation of respiratory passages. Chemical burns may occur with contact of wet or dry MTA to soft tissues (Winters *et al.*, 2008). More clinical trials to determine the long-term effectiveness of MTA as a pulpotomy medicament have been recommended due to the limited number of clinical outcomes and the inconsistent quality of results and methodology (Anthonappa *et al.*, 2013). A recent study conducted a systematic review of randomized clinical trials that included 1585 patients. The authors reported that MTA pulpotomy was significantly more successful than formocresol pulpotomy and that restoration with a stainless steel crown proved to be more successful than that with amalgam (Shirvani & Asgary, 2014).

Formocresol

Formocresol has been used for vital pulp therapy for over 80 years, with reported success rates of 62–100%. The formaldehyde component of formocresol provides bactericidal properties and reversible inhibition of numerous enzymes present with the inflammatory process. A superficial layer of fixation, with preservation of the deeper radicular tissues, results with appropriate use of formocresol (Winters *et al.*, 2008; Fuks, 2012).

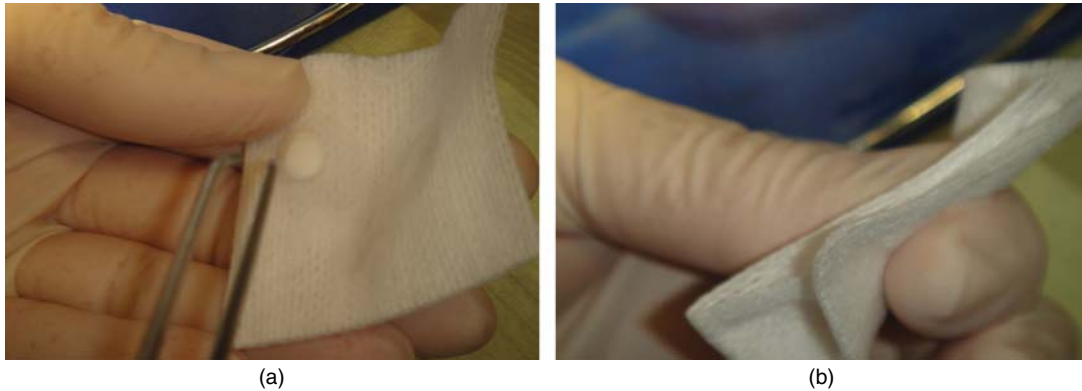


Figure 6.12 (a) Saturated formocresol cotton pellet. (b) Compressing formocresol cotton pellet in 2 × 2.

Rapid metabolism of formocresol to formate and carbon dioxide, with a half-life of 1–2 min, occurs with any systemic absorption (Winters *et al.*, 2008).

The liquid formocresol is squeezed from the saturated cotton pellet in a 2×2 gauze before snugly placing over the pulpal stumps in the pulp chamber for 1 min (Figure 6.12a and 6.12b). A 1-min application of full-strength Buckley's formocresol with a medicated cotton pellet showed comparable success rates to a 5-min application of the previously recommended one-to-five dilution of full-strength Buckley's formocresol (Kurji *et al.*, 2011). Only fumes from the pellet are necessary to provide adequate fixation of the superficial pulp tissues. The pulpal floor is very porous in infected primary molars. If the pellet is saturated with formocresol, the agent can penetrate through the accessory canals in the furcation and cause a severe reaction in the furcation tissue. Formocresol cotton pellets are never left in the pulp chamber until a second visit, and formocresol is never mixed with IRM because of concern with systemic uptake via the radicular blood supply. Soft tissue burns may occur from contact with formocresol.

The coronal pulp chamber is filled with IRM, a mixture of reinforced zinc oxide, and eugenol with polymer fibers (Dentsply Caulk). IRM liquid and powder can be mixed chair side, but capsules triturated at use save time and clean-up. The mix should be thick enough to form a ball of IRM that is carried to the tooth (Figure 6.13). The IRM is placed in the chamber and compressed with a wet cotton-tipped applicator (Figure 6.14a and 6.14b).



Figure 6.13 Thick mix of IRM.

Restoration

Full-coverage crowns are recommended for the final restoration to insure a good seal, protecting against bacterial infiltration with microleakage. Stainless steel crowns are typically the restoration of choice, but concerns with esthetics may prompt an alternative restoration. Primary molars may be restored with amalgam or composite resin if they are expected to exfoliate within 2 years (American Academy of Pediatric Dentistry, 2014). In a study by Hutcheson *et al.*, primary pulpotomies were treated with white MTA and restored with composite and stainless steel crowns. More marginal changes were found with composites. After 1 year, 94% of the primary molars restored with composite turned gray (Hutcheson *et al.*, 2012). Preveneered stainless steel crowns and zirconia crowns offer a more esthetic alternative.

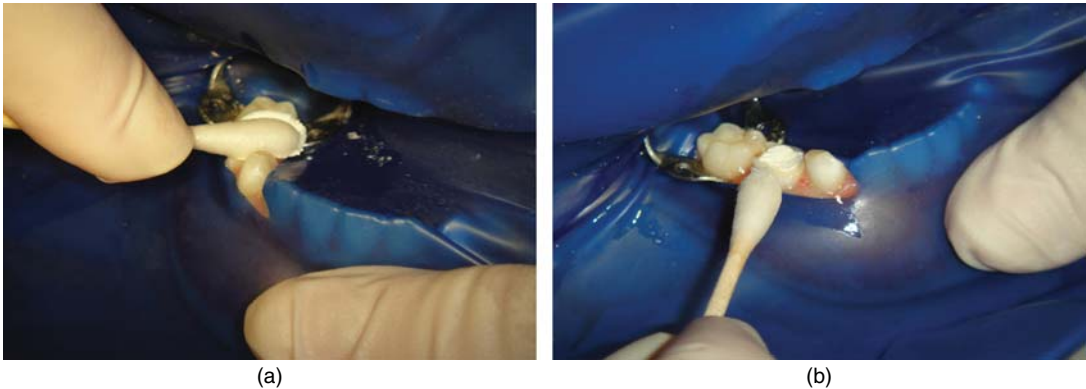


Figure 6.14 (a) IRM placed with wet cotton-tipped applicator. (b) IRM packed with wet cotton-tipped applicator.

References

- American Academy of Pediatric Dentistry. (2014) Guideline on pulp therapy for primary and immature permanent teeth. *Pediatric Dentistry*, **36** (special issue), 242–250.
- Anthonappa, R.P., King, N.M. & Martens, L.C. (2013) Is there sufficient evidence to support the long-term efficacy of mineral trioxide aggregate (MTA) for endodontic therapy in primary teeth? *International Endodontic Journal*, **46**, 198–204.
- Camp, J. (2011) Diagnosis dilemmas in vital pulp therapy. *Pediatric Dentistry*, **30**, 197–205.
- Erdem, A.P., Guven, Y., Balli, B. *et al.* (2011) Success rates of mineral trioxide aggregate, ferric sulfate, and formocresol pulpotomies: a 24-month study. *Pediatric Dentistry*, **33**, 165–170.
- Fuks, A.B. (2012) Complex pulp therapy. In: Moursi, A.M. (ed), *Clinical Cases in Pediatric Dentistry*. Wiley-Blackwell, Oxford, UK, pp. 89–136.
- Hui-Derksen, E.K., Chen, C.-F., Majewski, R. *et al.* (2013) Reinforced zinc oxide-eugenol pulpotomy: a retrospective study. *Pediatric Dentistry*, **35**, 43–46.
- Hutcheson, C., Seale, N.S., McWhorter, A. *et al.* (2012) Multi-surface composite vs stainless steel crown restorations after mineral trioxide aggregate pulpotomy: a randomized controlled trial. *Pediatric Dentistry*, **34**, 460–467.
- Kurji, Z.A., Sigal, M.J., Andrews, P. *et al.* (2011) A retrospective study of a modified 1-minute formocresol pulpotomy technique. Part I: clinical and radiographic findings. *Pediatric Dentistry*, **33**, 131–138.
- Seale, N.S. & Coll, J.A. (2010) Vital pulp therapy for the primary dentition. *General Dentistry*, **58**, 194–200.
- Shabzendedar, M.S., Mazhari, F., Alami, M. *et al.* (2013) Sodium hypochlorite vs formocresol as pulpotomy medicaments in primary molars. *Pediatric Dentistry*, **35**, 329–332.
- Shirvani, A. & Asgary, S. (2014) Mineral trioxide aggregate pulpotomy: a systematic review and meta-analysis of randomized clinical trials. *Clinical Oral Investigations*, **18**, 1023–1030 (January 23); epub ahead of print
- Walker, L.A., Sanders, B.J., Jones, J.E. *et al.* (2013) Current trends in pulp therapy: a survey analyzing pulpotomy techniques taught in pediatric dental residency programs. *Journal of Dentistry for Children*, **80**, 31–35.
- Winters, J., Cameron, A. & Widmer, R. (2008) Pulp therapy for primary and immature permanent teeth. In: Cameron, A.C. & Widmer, R.P. (eds), *Handbook of Pediatric Dentistry*, 3rd edn. Mosby, London, pp. 95–113.

کتاب پزشکی کام

تامین منابع علمی تخصصی پزشکی



کتاب پزشکی دات کام

www.ketabpezeshki.com

+98 21 6648 5438

+98 21 6648 5457

Diagnostic concerns

Clinical diagnosis

The American Academy of Pediatric Dentistry (AAPD; AAPD Reference Manual, 2013–14) Guideline on Pulp Therapy states that the type of pulpal treatment depends on whether the pulp is vital or nonvital. Pulpal vitality assessment is based on reaching one of four clinical diagnostic assessments: normal pulp (i.e., a tooth with shallow caries but is symptom free and would respond normally to pulp tests); reversible pulpitis (a tooth with an inflamed pulp that is capable of healing); symptomatic or asymptomatic irreversible pulpitis (an inflamed pulp incapable of healing); or necrotic pulp. The clinical diagnosis of irreversible pulpitis and/or necrosis is a primary tooth with any one or more of the following:

1. sinus tract or gingival swelling not associated with periodontal disease;
2. history of spontaneous unprovoked toothache;
3. excessive tooth mobility not associated with exfoliation;
4. furcation/apical radiolucency;
5. internal/external root resorption.

Pain evaluation

Teeth having no signs or symptoms of irreversible pulpitis or necrosis but exhibiting provoked pain of short duration relieved by brushing or analgesics or removing the stimulus are assessed as having reversible pulpitis and are capable of healing. There is evidence in primary molars (Farooq *et al.*, 2000) that pain can last up to 20 min and still be reversible pulpitis because a child may complain while a piece of candy or food is lodged

in the cavitated or interproximal lesion. According to Camp (2008), spontaneous pain is a persistent or throbbing pain that occurs without provocation or persists long after the causative factor has been removed. In a histologic study of deep carious lesions in primary teeth (Guthrie *et al.*, 1965), it was demonstrated that a history of spontaneous toothache is associated with extensive histologic pulpal degenerative changes that can extend into the root canals. A child with a history of spontaneous pain in a primary tooth should not receive a vital pulp treatment because they are candidates for pulpectomy or extraction (Camp, 2008). A normal pulp is a symptom-free tooth with normal response to appropriate pulp tests. For primary teeth, the appropriate clinical tests are palpation, percussion, and mobility, as thermal and electric pulp tests are unreliable (Camp, 2008). The Pulp Therapy Guideline (AAPD Reference Manual, 2013–14) states that teeth diagnosed as having a “normal pulp” or “reversible pulpitis” are classified as having vital pulps and treated with vital pulp therapy. Teeth diagnosed as having “irreversible pulpitis or necrosis” are treated with extraction or pulpectomy for primary teeth.

Any planned pulpectomy treatment must include consideration of the restorability of the tooth, the patient’s medical history, whether to extract, how long is the likely exfoliation of the tooth in question, and the importance of the tooth to prevent space loss (especially second primary molars before the first permanent molar has erupted).

Interim therapeutic restorations for diagnosis

The diagnosis of the primary tooth’s vitality is not always straightforward. A primary molar with deep distal caries

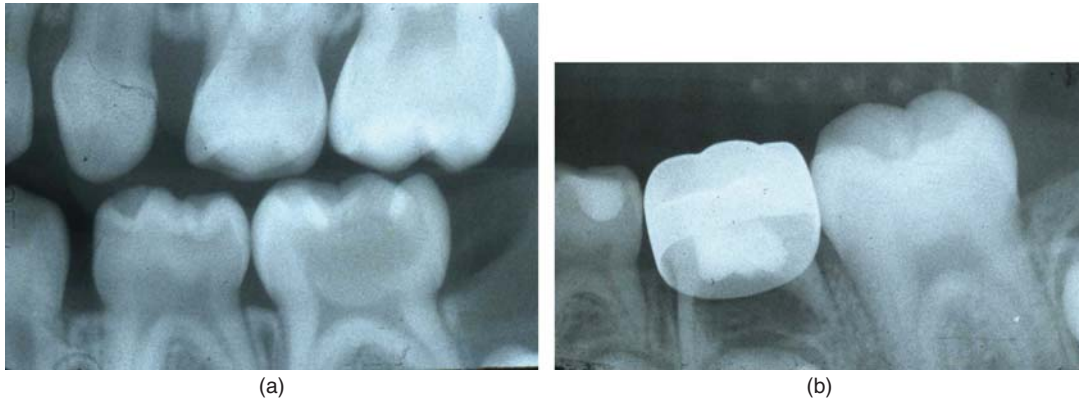


Figure 7.1 (a) Diagnosis is not always straightforward as seen in this second primary molar with deep caries and pain of short duration. A vital pulpotomy was planned because the tooth's pulp was judged as vital. (b) Same tooth 11 months after formocresol pulpotomy showing failure from misdiagnosis.

near the pulp without gingival swelling, but has pain of a short duration when the child chews a candy, can be easily misdiagnosed as vital. Performing vital pulp treatment with a pulpotomy on such a tooth can fail because of misdiagnosis (Figure 7.1).

The only way to accurately diagnose the degree of the pulp's inflammation is histologically. There is almost no correlation between the clinical symptoms the child presents with and the histopathologic condition of the tooth, which complicates diagnosis of pulpal health in children (Mass *et al.*, 1995). A patient may present with signs and symptoms that indicate reversible pulpitis, while if the pulp was histologically examined would demonstrate changes equivalent to chronic total pulpitis and need a pulpectomy or extraction (Seltzer *et al.*, 1963).

A new clinical adjunct to help the clinician reliably determine the pulp's vitality was recently published. Coll *et al.* (2013) studied 117 primary molars with deep carious lesions that were planned to have vital pulp therapy treatment. It was found that by using a glass ionomer interim therapeutic restoration (ITR) before treatment for 1–3 months accurately diagnosed the primary molar's pulp vitality in 94% of the cases compared to 78% of the teeth when no ITR was used. For teeth with pain, there were 18 patients who presented with pain as the chief complaint, which was not reported by Coll *et al.* (2013). In these 18 patients, the dentist was not sure if the pain was reversible or irreversible pulpitis. All received ITRs, and 17 of the 18 (94%) were correctly diagnosed with either

reversible or irreversible pulpitis. Using a glass ionomer ITR for 1–3 months will reliably diagnose the vitality of those molars with deep caries. If the tooth's pulp is irreversibly inflamed or necrotic after ITR, it will show either a fistula, obvious radiographic signs, or pain (Figure 7.2).

One unpublished radiographic finding concerns distal caries in lower primary first molars. If the bitewing shows the caries radiographically into the pulp, it appears from my experience that the pulps of these teeth are irreversibly inflamed, as pulpotomies appear to fail in these situations. From my clinical experience and research I conducted (Coll *et al.* 2013), distal radiographic decay into the pulp on a bitewing radiograph in mandibular primary first molars is usually irreversibly inflamed or necrotic (Figure 7.3).

Clinical evaluation and history

The clinical evaluation involves assessing the child for signs and symptoms of irreversible pulpitis or necrosis clinically or by history. This will include an extraoral examination asking about and looking for facial swelling or tenderness. Question the caregiver as to a history of fever, and if needed, use a thermometer to check for any elevation in temperature. Questioning the child in most cases will not always yield reliable information as to the history of pain. Ask the parent or caregiver "Has your child awakened in the middle of the night like at two AM with pain"? Do not simply say "Has

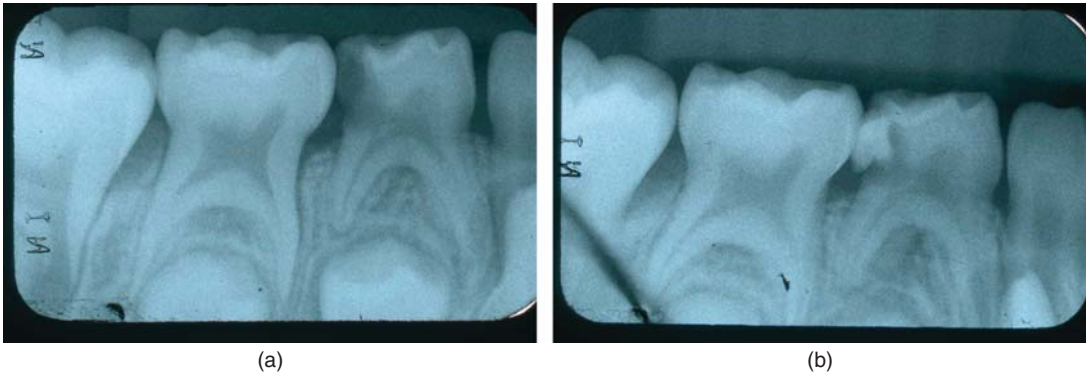


Figure 7.2 (a) Pretreatment radiograph of a mandibular first primary molar without soft tissue swelling but an unclear history of pain that made the dentist unsure of the diagnosis. An interim therapeutic restoration using glass ionomer cement was placed. (b) One week later, the patient had a gingival swelling without pain, finalizing the diagnosis as irreversible pulpitis.

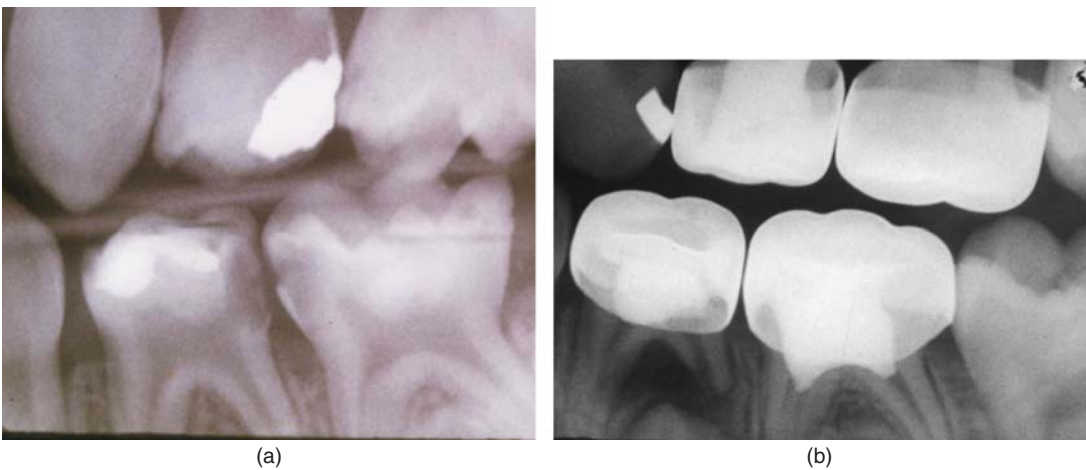

Figure 7.3 (a) Pretreatment radiograph of a mandibular first primary molar with distal caries radiographically into the pulp patient age 4.5 years. No interim therapeutic restoration was placed, and a vital formocresol pulpotomy was performed because pulpal bleeding was controlled with a cotton pellet. (b) Same first primary molar showing formocresol pulpotomy failure 24 months later. The tooth's pulp had irreversible pulpitis, which was not clinically apparent and is a contraindication for vital pulp treatment.

your child awakened with pain at night"? A cavitated lesion in a primary molar may cause pain at bedtime but not irreversible pulpitis. The child can have a snack at bedtime and go to bed without brushing the teeth. A reversibly inflamed pulp can then cause the child to complain of "pain at night," which is not spontaneous pain. As stated previously, the duration of pain in a primary tooth is not a critical assessment as to the degree of pulpal inflammation (Farooq *et al.*, 2000). A large cavitated lesion in a primary molar can get a gummy candy or food lodged in it and cause pain for an extended duration in a child, but the pulp

may not be irreversibly inflamed. The history of the present toothache in my opinion is the most important information the dentist can obtain to determine the vitality of the tooth.

Percussion, mobility, and pulp tests

After completing the history, perform an intraoral examination of the area of concern. Be aware that a parent can claim that pain is in the lower right because they see a carious lesion in their child's lower right first primary molar. The child may have held his or her hand on the right side of the face and said his or her tooth

hurt. The parent may mistakenly assume that the pain is from the lower right first primary molar. However, the pain is actually from a maxillary right molar the parent never looked at. Look for teeth with caries that show a missing filling, soft tissue redness, fluctuance, or a draining fistula. Percussion can be a valuable aid in diagnosing whether the tooth has irreversible pulpitis due to the infection, causing pressure in the periodontal ligament (PDL). However, the reliability of the child's response has to be assessed due to apprehension and the child's maturity. I recommend using a finger to press on a nonsuspicious tooth first. Then, press on the suspicious tooth and look for any sign of discomfort in the child's expression. Do not use an instrument handle to tap on the tooth because this can be misunderstood in a child as pain. Tooth mobility in an infected primary incisor may be the only clinical sign of dental infection, especially if diagnostic radiographs are unable to be taken. Maxillary primary incisors in children younger than 4 years that are mobile with large caries are likely infected. The dentist must be aware of physiologic root resorption, but a slightly mobile primary molar in a child aged 6 years or younger would indicate an abscess. However, many infected primary molars do not exhibit mobility. Other pulp tests for primary teeth such as cold, hot, and electric pulp tests are of little use in children due to the unreliable responses (Camp, 2000; Flores *et al.*, 2007).

Tooth color change

A tooth color change occurring in primary incisors after trauma in many cases does not indicate necrosis. Holan (2004) studied 97 primary incisors that exhibited dark discoloration after trauma. In 52% of the dark incisors, the color became yellowish, while 48% remained dark. Clinical signs of infection were associated with the incisors that remained dark. The teeth that lightened in color showed pulp canal narrowing or obliteration, but in most cases no infection. In addition, of the incisors that retained their dark color, Holan (2004) reported that 50% remained clinically asymptomatic and exfoliated even if they showed accelerated root resorption. I did a study on primary incisor trauma that I never published. It was a retrospective analysis of 45 teeth, with concussion blows followed a mean of 47 months. The parents brought most of the children 7–14 days after trauma because most presented with a gray color within 1 month after trauma. After their

final examination or a minimum of 24 months, 86% was a normal or light yellow color and radiographically showed narrowing or obliteration of their root canals. So, in diagnosing traumatized primary incisors for pulp treatment, watchful waiting is a good rule, and if a fistula or other sign of pulp infection is seen, then perform treatment. Be aware, a pulpectomy in a dark primary incisor does not lighten the tooth's color. An avulsed primary teeth should not be reimplanted and have a pulpectomy performed (Flores *et al.*, 2007).

Pulpal bleeding

When opening into the pulp from a carious exposure, the larger the exposure, it likely means the pulpal inflammation is extensive and/or necrotic, and so a pulpectomy or extraction is needed (Camp, 2008). It is problematic to assess the color of the pulpal bleeding and correlate the color to the degree of inflammation. The AAPD Guideline (AAPD Reference Manual, 2013–14) states that a tooth whose pulpal hemorrhage is not controlled with a damp cotton pellet after several minutes is indicated for pulpectomy/extraction and not pulpotomy (Camp, 2008).

Radiographic assessment

Radiographic evaluation with good quality films is essential to help obtain the proper diagnosis of primary tooth suspected to have irreversible pulpitis or necrosis. In primary molars, the initial irreversible pulpitis radiographic sign is furcation radiolucency (Camp, 2008). Lugliè *et al.* (2012) found that 77% of the primary molars studied had accessory canals in the furcation area, explaining why the radiolucency appears there first. In permanent molars, the radiolucency appears at the apex because it is where most accessory canals are located. The size of the furcation radiolucency in a primary molar is not a contraindication to pulpectomy (Coll, 1996; Figure 7.4).

As the furcation area in primary molars is critical to evaluate for signs of radiolucency, both a bitewing and periapical radiograph should be exposed. The bitewing will always be taken with a parallel technique giving the best undistorted view of the furcation. Secondly, if there is a proximal or occlusal carious lesion, the bitewing gives a reliable assessment of the depth of decay. The periapical film will help determine any apical root resorption and together with the bitewing allows the

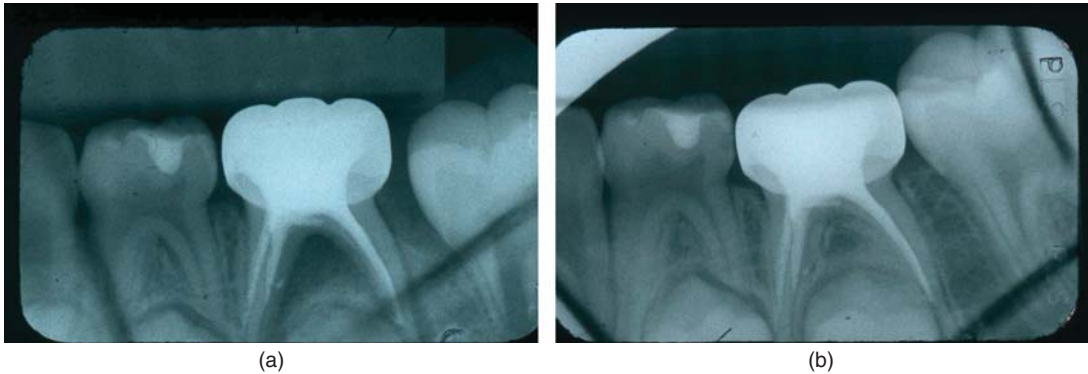

Figure 7.4 (a) Immediate post zinc oxide and eugenol pulpectomy radiograph of a mandibular second primary molar showing large radiolucency. Size of radiolucency or gingival swelling is not a contraindication for a pulpectomy. (b) Sixteen months post-treatment radiograph of same second molar that was asymptomatic. It exhibits bone fill and shows that the size of the pretreatment radiolucency is not a contraindication for pulpectomy.

proper assessment of the succedaneous tooth's eruption status.

Root resorption

Owing to the depth of decay and the succedaneous tooth's follicle, radiographic interpretation can be a problem. Proximal lesions in primary molars fail the most often with vital pulp treatments compared to nonproximal lesions (Coll *et al.*, 2013). In maxillary primary molars, the superimposition of the follicle over the primary root makes assessment of root resorption at times difficult. From the study of Coll and Sadrian (1996), the one factor radiographically that predicted primary tooth pulpectomy success was preoperative root resorption. From 81 primary teeth receiving zinc oxide eugenol (ZOE) pulpectomy and followed over 7 years, it was found that teeth having greater than 1 mm of root resorption had only 23% pulpectomy success ($p=0.001$) (Coll, 1996). Therefore, examine a primary tooth carefully for any internal or external root resorption. If root resorption is seen as in the distal root in Figure 7.3b, or a failed pulpotomy, extraction of the primary tooth is indicated.

The exception to this rule is a second primary molar one wishes to try and maintain with a pulpectomy until the first permanent molar erupts, and a fixed space maintainer can be made. If root resorption is found and one wishes to try and maintain a second primary molar for 12 months or so, I would recommend using

an iodoform pulpectomy filler because it resorbs easily compared to ZOE.

Pulpectomy research and filler resorbability

What are the recommended pulpectomy fillers for primary teeth from the AAPD Guidelines? The Guideline recommends "...a resorbable filler material such as non-reinforced ZOE, iodoform-based paste (KRI), or a combination paste of iodoform and calcium hydroxide (Vitapex® or Endoflas®) is used to fill the canals" (AAPD Reference Manual, 2013–14).

ZOE is the most commonly used pulpectomy filler for primary teeth in the United States (Dunston & Coll, 2008). Eugenol is said to have antiinflammatory and analgesic properties, and ZOE has antibacterial properties, but the disadvantages of ZOE in primary tooth pulpectomy are irritation to the periapical tissues (Praveen *et al.*, 2011), slow and incomplete resorption (Sadrian, 1993), and alteration to the path of eruption of succedaneous tooth (Figure 7.5; Coll, 1996).

Kri paste is a highly resorbable bactericidal compound that allows healthy tissue growth at the apex. It is composed of an 80% iodoform compound and also contains parachlorophenol 2%, camphor 5%, and menthol 1% (Praveen *et al.*, 2011). Any iodoform is an organic halogen compound that contains iodine that has disinfecting properties. When iodoform pastes such as Kri paste were

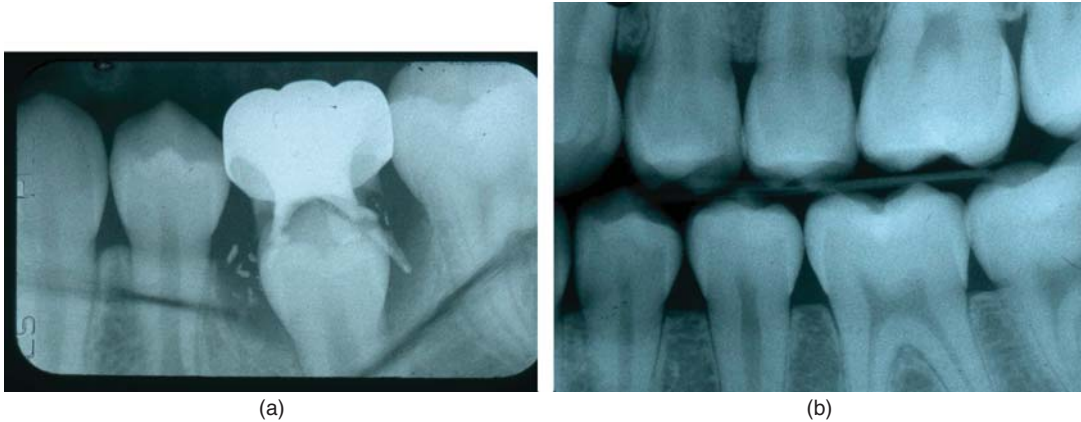


Figure 7.5 (a) Same mandibular second primary molar as seen in Figure 7.4(a) and (b) starting to exfoliate 54 months after successful zinc oxide and eugenol (ZOE) pulpctomy. Note small ZOE particles breaking apart around the erupting premolar. (b) Example of ZOE pulpctomy's slow and incomplete resorption 4.11 years later. Note one small ZOE particle between the first and second mandibular premolars still present.

extruded out the apex of primary teeth, it was resorbed quickly, and none of the succedaneous teeth exhibited enamel defects (Nurko *et al.*, 2000).

Vitapex is also an iodoform so that it easily resorbs when extruded out the apex or into the furcal area (Figure 7.6; Nurko *et al.*, 2000).

It will also resorb inside the root canal so that a Vitapex pulpctomy will always resorb and at times look analogous to a pulpotomy with time (Howley *et al.*, 2012; Trairatvorakul & Chunlasikaiwan, 2008). Vitapex

combines 30% calcium hydroxide with 40.4% iodoform and 22.4% silicone and other oil-type additives in a yellow paste (Praveen *et al.*, 2011). It is supplied in a syringe with disposable plastic tips (Nurko *et al.*, 2000). Vitapex along with other iodoform pulpctomy pastes has shown bactericidal activity and has no detrimental effect on the succedaneous tooth (Praveen *et al.*, 2011). It never hardens and so it stays as a soluble material.

Endoflas F. S. is an endodontic paste composed of zinc oxide (56.5%), barium sulfate (1.63%), iodoform

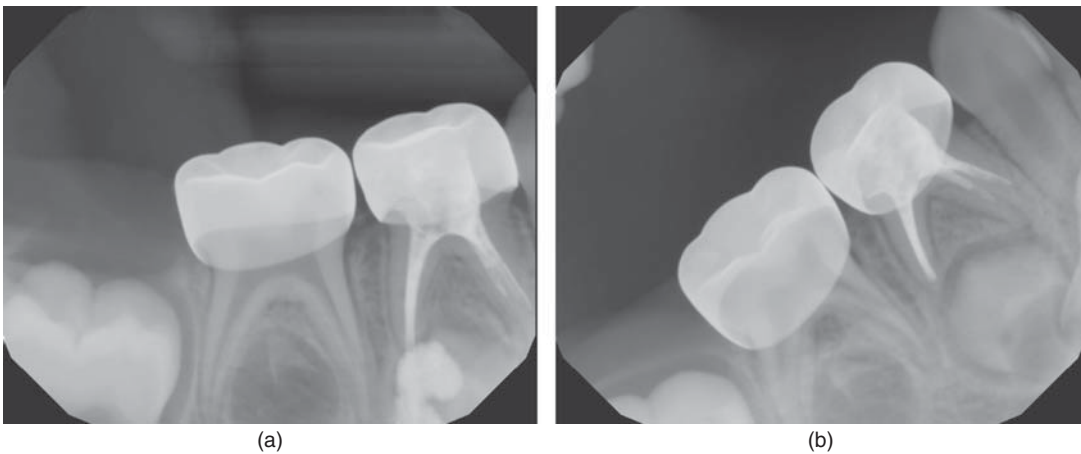


Figure 7.6 (a) Example of an immediate postpulpctomy radiograph showing Vitapex being inadvertently extruded out the distal canal of this first primary molar. (b) Radiograph of the same fist primary molar 6 months later showing the Vitapex filler that was extruded has resorbed, and tooth was asymptomatic without soft tissue pathology from the day of pulpctomy.

(40.6%), calcium hydroxide (1.07%), eugenol, and pentachlorophenol. Some describe it as Vitapex with ZOE (accessed at <http://www.endoflas.com/>).

The research on ZOE pulpectomy shows that it is a reliable filler, with success about 80% with some clinical complications (Casas *et al.*, 2004; Coll, 1996). ZOE is pure ZOE, while Intermediate Restorative Material (IRM) should not be used because the later resorbs poorly. Coll and Sadrian (1996) retrospectively studied 81 ZOE pulpectomies (51 molars and 30 incisors) followed for a mean of 90.8 months. Overall success was 77.7%, with no difference between molars and incisors. Enamel defects occurred in 18.7% of succedaneous teeth, but they were related to excess pretreatment root resorption of greater than 1 mm. ZOE pulpectomy caused 20% of permanent incisors and premolars to erupt into cross bite or ectopically. One other concern with ZOE filler is its slow resorption. Sadrian and Coll (1993) found that 27% of ZOE pulpectomies had retained filler a mean time of 40.2 months after pulpectomy tooth loss. Retained filler was related to filler extruded outside the root canal.

Kri paste is not currently approved by the U.S. Food and Drug Administration (FDA) for use in the United States. Its use and resorbability are similar to Vitapex. Holan and Fuks (1993) found Kri paste pulpectomy success of 84% after 12–48 months. Two prospective studies found no statistical difference between pulpectomy success comparing Vitapex and ZOE fillers (Ozalp *et al.*, 2005; Trairatvorakul & Chunlasikawan, 2008). There are no reports of Kri paste or Vitapex filler being over-retained or causing ectopic eruption of the succedaneous tooth.

Endoflas in a short-term study of 9 months showed a 95% success rate (Ramar & Mungara, 2010). An 18-month prospective Endoflas study found success of 93%, which was the same as ZOE (Subramaniam & Gilhotra, 2011). Moskovitz *et al.* (2005) has shown long term that Endoflas is a viable alternative to ZOE for use as a pulpectomy filler. Endoflas has no published articles indicating its particles are over-retained after the primary tooth exfoliates and is not implicated in causing ectopic eruption.

From the aforementioned evidence, as all four AAPD-recommended pulpectomy fillers show comparable success, the decision as to which to use is up to the dentist. As Kri paste is not FDA approved, the other FDA-approved iodoform (Vitapex) would be available.

As ZOE has been associated with ectopic eruption of the succedaneous tooth and tends to cause over-retained filler particles, Endoflas would be the other alternative.

Pulpectomy technique

This section describes only primary molar pulpectomy because of space limitations. Primary incisors can also be successfully treated with iodoform pulpectomy fillers in a method similar to what is described for molars. The main difference is that the incisor canal is filed to a larger size file such as size #50–60.

After determining that the primary tooth is a candidate for a pulpectomy, recheck that the tooth is restorable. Space loss as a result of large interproximal or excessively deep proximal lesions can make a primary molar difficult to restore. Obtain local anesthesia even if the tooth is necrotic. The soft tissue needs anesthesia, and so the child is not uncomfortable for the pulpectomy. Plan to perform the final restoration at the same visit as the pulpectomy. I recommend using a rubber dam. The child does not want to taste the hypochlorite that is used, and a rubber dam prevents that from occurring. I have used cotton roll and Isodry® isolation techniques for operative dentistry but would still recommend a rubber dam for the pulpectomy.

After placement of the rubber dam, when doing a steel crown, perform the occlusal reduction first, proximal reduction second, caries removal third, and then enter into the pulp chamber. I will use a 330 high-speed bur to enter into the pulp chamber and expose the occlusal part of the pulp chamber. Change to a slow speed round bur #4 or #6 depending on the size of the tooth, to remove the overhanging tooth structure. For a first primary molar, I use a #4, but for a second primary molar, I use a #6 slow-speed round bur. One needs to have a good visualization of all the root canal orifices (Figure 7.7).

A mandibular first primary molar will likely have two root canals but possibly a third canal in the mesial. A mandibular second primary molar will likely have three canals (mesial buccal, mesial lingual, and one distal canal), but at times, there will be two distal canals. A maxillary first primary molar will normally have two canals but may have a third mesial canal. A maxillary second primary molar will likely have three canals (a mesial lingual, mesial buccal, and a large lingual canal).

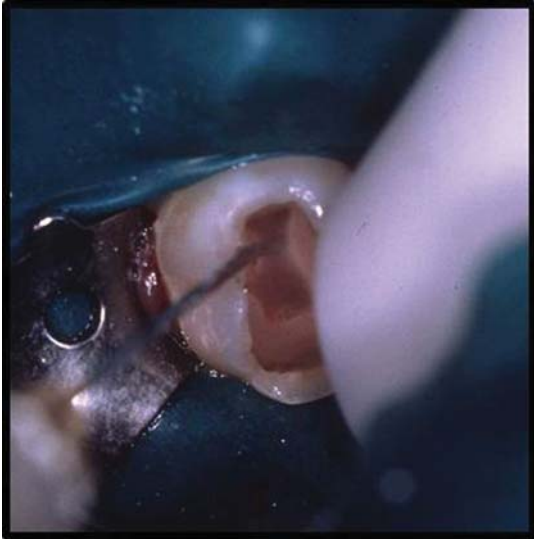

Figure 7.7 Occlusal access of a mandibular second primary molar showing all the root canal orifices without any overhanging tooth structure to hamper visualizing the canals.

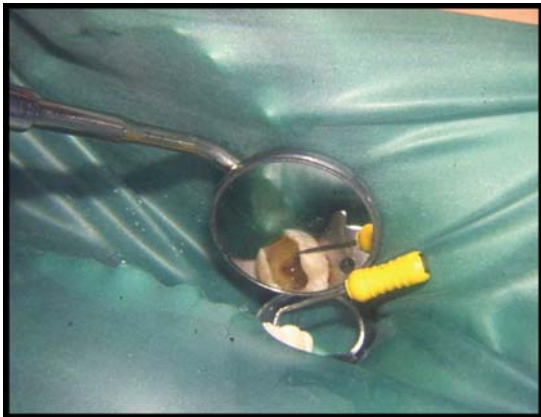


Figure 7.8 A mandibular second primary molar with the initial file inserted using a size #20. It was bent 90° in order to access the mesial buccal canal, which at times is hard to find. The file is rotate 90–180° and withdrawn two to three times in each root canal.

Identify the canal orifices using a small-sized file using #20 or smaller if needed (Figure 7.8).

Flush the pulp chamber with 5% hypochlorite or dilute the hypochlorite to 2.5% to flush the pulp chamber (Figure 7.9).

I use the #20 file initially to enter each root canal. If the #20 file does not enter the canal very far (<5–8 mm), I

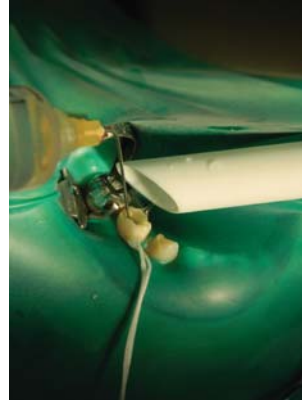


Figure 7.9 Mandibular first primary molar showing liberal use of sodium hypochlorite flushing the canals after each file was used.

will use a #15 or #10 file to negotiate the canal. Usually, a #20 file will negotiate the canal till I can feel an apical resistance point. I use that distance as the working length.

Some advocate using an apex locator or the working length from the digital image, but no research has been published showing the correct determination of working length of a primary tooth critical to improving the pulpectomy success. For most children, performing the pulpectomy without delay to minimize behavior problems appears to be a good procedure.

I recommend filing each canal by inserting it into the canal to till I feel an apical resistance point. Then, I rotate the file 90–180° and withdraw it two or three times. If I feel no resistance point with a size #20, I will go up to a size #25 and then #30. If no resistance point is felt at size #30 (size #40 for large incisors), I assume the tooth has root resorption that was not evident from the preoperative radiograph. At that point, I recommend extraction, rather than a pulpectomy. Assuming there was a resistance point in each canal, I sequentially go through the file sizes up to size #30–35 if I started with a size #20 file. If I started with a smaller file, I end at size #25–30. Flush the canals with 5 mL or more of hypochlorite after each file. Then, dry the canals with fine-sized paper points. The paper points should come out clean but may show a slight amount of blood at the tip (Figure 7.10).

The patient's tooth may exhibit excessive bleeding even after filing to size #30–35. If this occurs, either refile the canals or place into the pulp chamber a slightly moistened full strength formocresol pellet covered with

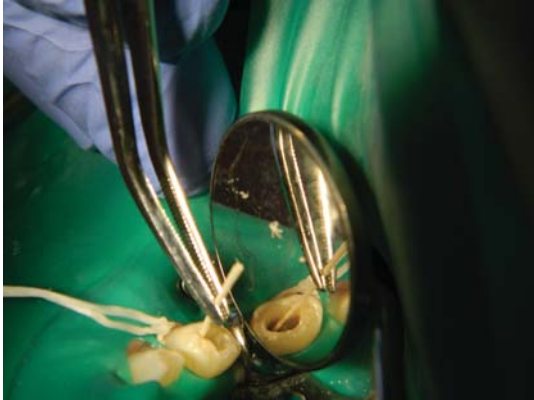

Figure 7.10 Mandibular first primary molar showing the first of multiple fine paper points being used to completely dry the canals. A small amount of blood on the apical tip of the paper point is fine. If there is excessive bleeding, refill the canals.

a temporary filling. After 1–2 weeks, the canals will no longer have excessive bleeding. Or the patient may have a “hot” tooth that will not be adequately anesthetized when one enters the pulp. If the tooth is too painful when one starts to access the chamber, create a small

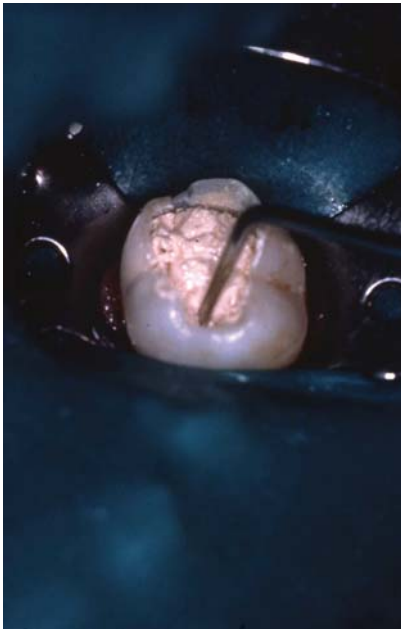

Figure 7.11 Mandibular second primary molar showing zinc oxide and eugenol filler being inserted into the root canals using a root canal plunger. After inserting the ZOE, a slightly moistened cotton pellet is used to compress the ZOE apically.

opening into the pulp chamber. Then, seal in a slightly moistened full strength formocresol cotton pellet over the small pulpal opening and cover it with IRM or glass ionomer cement. Leave the pellet for 1–2 weeks. The formocresol cotton pellet will denature the vital tissue so that the pulpectomy can be finished without the tooth being painful.

After all the root canal filing is completed and the paper points have been used to dry the canals, it is time to fill the canals. Use pure zinc oxide and eugenol and insert the ZOE with root canal pluggers or with a lentulo (Figure 7.11).

I would recommend using Vitapex if one is doing a pulpectomy for the first time. Vitapex resorbs if it is extruded beyond the apex; its success is equal to ZOE, and it will not deflect the succedaneous permanent tooth from its path of eruption. Vitapex is supplied with disposable plastic tips. Place a plastic tip on the Vitapex syringe. Press the syringe plunger till some Vitapex is extruded from the tip. Then, insert the plastic tip as far as possible into the first canal. Press on the syringe plunger and start withdrawing the tip at the same time out of the root canal. This is a tricky technique. Do the same for each canal. Deposit some of the Vitapex into the floor of the pulp chamber. Use a very slightly moistened cotton pellet to press on the Vitapex that is in the pulp chamber to force it into the root canals (Figure 7.12).

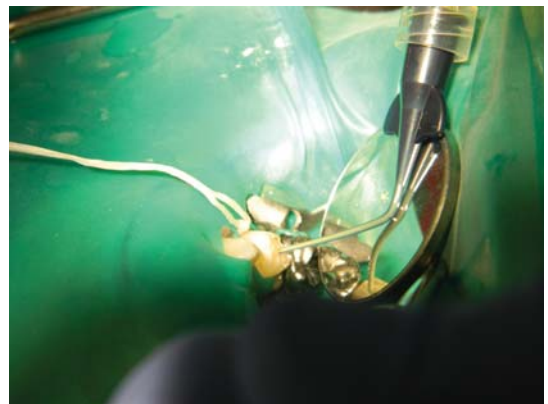


Figure 7.12 Mandibular first primary molar showing the Vitapex syringe with disposable plastic tip being inserted into the distal canal orifice. Press on the syringe plunger with the plastic tip as far into the canal as possible. Begin to slowly remove the plastic tip only when Vitapex filler is seen coming out the canal opening.

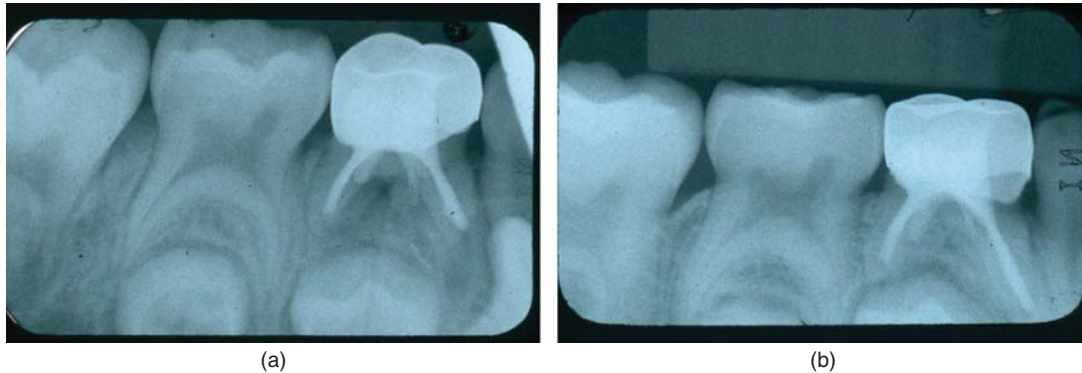


Figure 7.13 (a) Mandibular first primary molar with a zinc oxide and eugenol pulpectomy showing the day of treatment radiograph used as a reference film with a small furcation radiolucency. (b) Same mandibular first primary molar 1 year after treatment showing bone fill in the furcation compared to the immediate post-treatment film.

After the Vitapex has been placed, mix a self-setting glass ionomer (Ketac Molar or Fugii IX) into the pulp chamber. Use a slightly moistened cotton pellet to apically press the glass ionomer to insure the glass ionomer is tightly placed over the Vitapex. Then, place the final restoration, which will be a steel crown in most cases. Take a postoperative radiograph for future reference of treatment outcome (Figure 7.13).

Severe postoperative swelling and pain should not occur similarly to what is expected after performing a pulpotomy or indirect pulp cap. One can recommend over-the-counter analgesics for any mild discomfort the child may have. Any preoperative gingival swelling or fistula will resolve on its own without any antibiotic or further surgical treatment within a week or two. If one diagnosed the tooth correctly without any root resorption, one should expect long-term pulpectomy success with Vitapex or zinc oxide and eugenol to be 80–90%. The Vitapex-filled pulpectomy will likely look analogous to a pulpotomy after a year, but that is not a sign of failure. The signs of pulpectomy failure clinically are pain and/or swelling. Radiographically, failure will show abnormal root resorption or the initial radiolucency is enlarging or no bone fill after 6–12 months.

The whole pulpectomy procedure from rubber dam placement to when the filler is placed but not including the final restoration has been placed takes less than 30 min for most teeth. This chapter was intended to give a background on primary tooth pulpectomy and aid the clinician on the step-by-step techniques to successfully perform the procedure.

References

- AAPD Reference Manual (2013–14) Guideline on pulp therapy for primary and immature permanent teeth. *Pediatric Dentistry*, **35** (6), 235–242.
- Camp, J.H. (2008) Diagnosis dilemmas in vital pulp therapy: treatment for the toothache is changing, especially in young, immature teeth. *Pediatric Dentistry*, **30** (3), 197–205.
- Casas, M.J., Kenny, D.J., Johnston, D.H. *et al.* (2004) Long-term outcomes of primary molar ferric sulfate pulpotomy and root canal therapy. *Pediatric Dentistry*, **26** (1), 44–48.
- Coll, J.A., Campbell, A. & Chalmers, N. (2013) Effects of glass ionomer temporary restorations on pulpal diagnosis and treatment outcomes in primary molars. *Pediatric Dentistry*, **35** (5), 416–421.
- Coll, J.A. & Sadrian, R. (1996) Predicting pulpectomy success and its relationship to exfoliation and succedaneous dentition. *Pediatric Dentistry*, **18** (1), 57–63.
- Dunston, B. & Coll, J.A. (2008) A survey of primary tooth pulp therapy as taught in US dental schools and practiced by diplomates of the American Board Of Pediatric Dentistry. *Pediatric Dentistry*, **30** (1), 42–48.
- Flores, M.T., Holan, G., Borum, M. & Andreasen, J.O. (2007) Injuries to the primary dentition. In: Andreasen, J.O., Andreasen, F. & Andersson, L. (eds), *Textbook and Color Atlas of Traumatic Injuries to the Teeth*, 4th edn. Blackwell Munksgaard, Oxford, UK.
- Farooq, N.S., Coll, J.A., Kuwabara, A. *et al.* (2000) Success rates of formocresol pulpotomy and indirect pulp therapy in the treatment of deep dentinal caries in primary teeth. *Pediatric Dentistry*, **22** (4), 278–286.
- Guthrie, T.J., McDonald, R.E. & Mitchell, D.F. (1965) Dental hemogram. *Journal of Dental Research*, **44**, 678–682.
- Holan, G. (2004) Development of clinical and radiographic signs associated with dark discolored primary incisors following

- traumatic injuries: a prospective controlled study. *Dental Traumatology*, **20** (5), 276–287.
- Holan, G. & Fuks, A.B. (1993) A comparison of pulpectomies using ZOE and KRI paste in primary molars: a retrospective study. *Pediatric Dentistry*, **15** (6), 403–407.
- Howley, B., Seale, N.S., McWhorter, A.G. *et al.* (2012) Pulpotomy versus pulpectomy for carious vital primary incisors: randomized controlled trial. *Pediatric Dentistry*, **34** (5), 112–119.
- Lugliè, P.F., Grabesu, V., Spano, G. & Lumbau, A. (2012) Accessory foramina in the furcation area of primary molars. A SEM investigation. *European Journal of Paediatric Dentistry*, **13** (4), 329–332.
- Mass, E., Zilberman, U. & Fuks, A.B. (1995) Partial pulpotomy: another treatment option for cariously exposed permanent molars. *ASDC Journal of Dentistry for Children*, **62** (5), 342–345.
- Moskovitz, M., Sammara, E. & Holan, G. (2005) Success rate of root canal treatment in primary molars. *Journal of Dentistry*, **33** (1), 41–47.
- Nurko, C., Ranley, D.M., Garcia-Godoy, F. *et al.* (2000) Resorption of a calcium hydroxide/iodoform paste (Vitapex) in root canal therapy for primary teeth: a case report. *Pediatric Dentistry*, **22** (6), 517–520.
- Ozalp, N., Saroğlu, I. & Sönmez, H. (2005) Evaluation of various root canal filling materials in primary molar pulpectomies: an in vivo study. *American Journal of Dentistry*, **18** (6), 347–350.
- Praveen, P., Anantharaj, A., Venkataragahavan, K. *et al.* (2011) A review of obturating materials for primary teeth. *Streamdent*, **20** (20), 1–3.
- Ramar, K. & Mungara, J. (2010) Clinical and radiographic evaluation of pulpectomies using three root canal filling materials: an in-vivo study. *Journal of the Indian Society of Pedodontics and Preventive Dentistry*, **28** (1), 25–29.
- Sadrian, R. & Coll, J.A. (1993) A long-term follow up on the retention rate of zinc oxide eugenol filler after primary tooth pulpectomy. *Pediatric Dentistry*, **15** (4), 249–253.
- Seltzer, S., Bender, I.B. & Ziontz, M. (1963) The dynamics of pulp inflammation: correlations between diagnostic data and actual histologic findings in the pulp. *Oral Surgery, Oral Medicine, Oral Pathology*, **16**, 969–977.
- Subramaniam, P. & Gilhotra, K. (2011) Endoflas, zinc oxide eugenol and metapex as root canal filling materials in primary molars—a comparative clinical study. *Journal of Clinical Pediatric Dentistry*, **35** (4), 365–369.
- Trairatvorakul, C. & Chunlasikaiwan, S. (2008) Success of pulpectomy with zinc oxide-eugenol vs calcium hydroxide/iodoform paste in primary molars: a clinical study. *Pediatric Dentistry*, **30** (4), 303–308.

8

Extraction of primary dentition

Jane A. Soxman

A periapical radiograph to evaluate the location, presence, or absence of the permanent successor and informed consent should be obtained before extraction. The length of unresorbed roots after a primary tooth's extraction may surprise the parent/guardian. The use of the pre-extraction radiograph and/or the use of a mixed dentition typodont (Kilgore International) are good methods to show root length before an extraction (Figure 8.1).

Curette

After administration of local anesthesia, a sterile curette may be used to sever the gingival attachment (Figure 8.2). This first step of the procedure may predict the behavior for the remainder of the procedure, as a very anxious child will respond negatively to even slight pressure with the curette. Anxiety is the biggest predictor of poor pain control (Nakai *et al.*, 2000).

Luxation

Luxation (loosening) is the most important step to facilitate extraction and avoid root fracture of a primary molar. The interproximal contacts of primary molars are broad, flat and without cervical constriction. The tip of the instrument for luxation should be narrow enough to be placed through the embrasures of the primary molars (Figure 8.3a and 8.3b). This step may not be necessary for primary incisors and canines with conical, single roots but may be helpful in some cases.

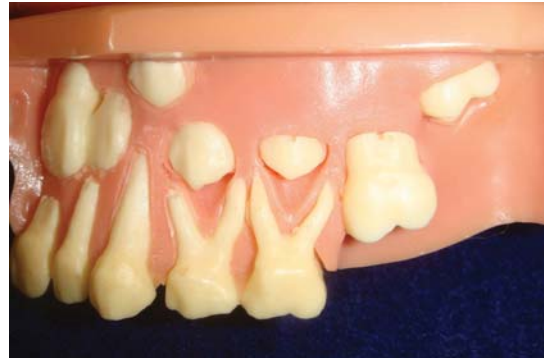

Figure 8.1 Mixed dentition typodont to show root length of primary dentition.

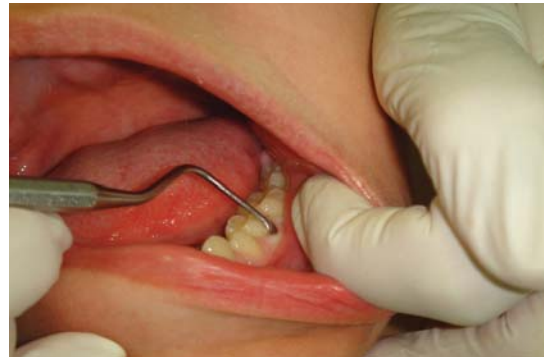

Figure 8.2 Curette severing the gingival attachment.

Primary incisors may be luxated using straight forceps with a labiolingual movement. During luxation, use caution not to include adjacent teeth, causing mobility. If an adjacent tooth is mobile before the extraction, the

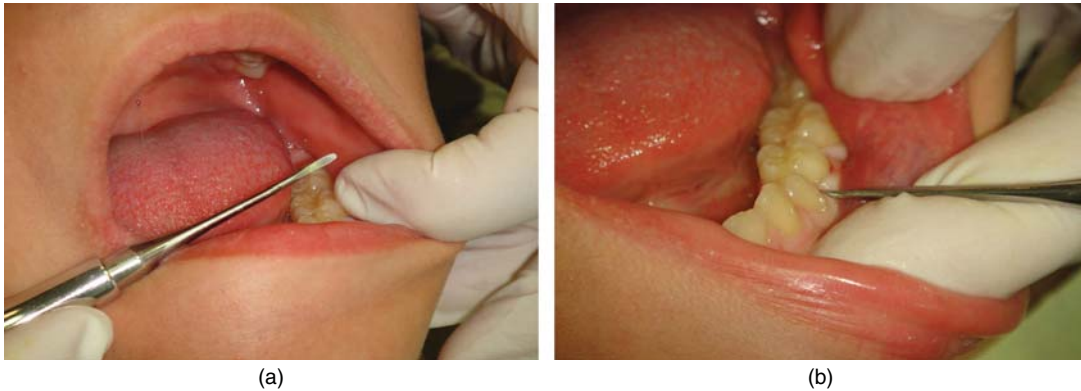

Figure 8.3 (a) Luxation instrument. (b) Luxation of primary molar.

parent/guardian should be informed of the possibility of an unintentional extraction.

The feeling of pressure during the luxation and extraction should be explained. Pushing on the child's shoulder may demonstrate this sensation. If a previously cooperative child begins to cry, exhibiting pain during luxation, administration of additional local anesthesia is indicated. Injections through the mesial and distal papilla from buccal to lingual, along with injection into the gingival sulcus, are very effective. Palatal injection using the DentalVibe significantly reduces injection discomfort (Figures 8.4a, 8.4b, 8.4c, and 8.5).

Extraction

Primary incisors' roots are conical in shape. Place a straight beak pediatric forceps, designed for primary incisor and canine extractions, vertically on the long axis of the tooth (Figure 8.6a and 8.6b). Luxation may not be necessary. A rotational movement is used for extraction. Primary molars present more of a challenge because their roots are thin and diverge beyond the crown. Root fracture may occur during extraction of a primary molar if too much pressure is placed during luxation with the forceps. Luxation, achieving class III mobility of the primary molar before use of the forceps, will significantly reduce the incidence of root fracture. After adequate luxation, minimal buccal/lingual (palatal) force is applied with the forceps to expand

the alveolar bone and lift the tooth out of the socket. Serrated beak pediatric forceps provide a firmer grasp than the traditional smooth beak forceps to retain the short crown of a primary molar (Figure 8.7).

The premolars develop in the furcation between the roots of the primary molars. If the roots of the primary molar encircle the crown of the permanent successor, the primary molar should be sectioned before extraction to avoid inadvertent extraction of the permanent successor. A slice through the center of the primary molar with a cross-cut fissure bur from buccal to lingual is performed (Figure 8.8a and 8.8b). A luxation instrument may be used to place pressure on the segments to separate the coronal portion into two parts, and the two halves are lifted out of the socket (Figure 8.8c, 8.8d, 8.8e, 8.8f, 8.8g). If inadvertent extraction of the developing premolar should occur, the tooth bud should be replaced in the socket, and the gingiva over the socket is sutured closed.

Damage to the developing succedaneous tooth is the primary concern regarding retrieval of a fractured root. A periapical radiograph may be obtained to determine the presence or location of the root or root tip. Removal may be performed with a root tip pick or a surgical suction tip. If retrieval cannot be achieved after a few attempts, the root or root tip should be left for resorption. The parent/guardian should be informed along with documentation in the patient's chart (American Academy of Pediatric Dentistry, 2014b AAPD Reference Manual p. 278).

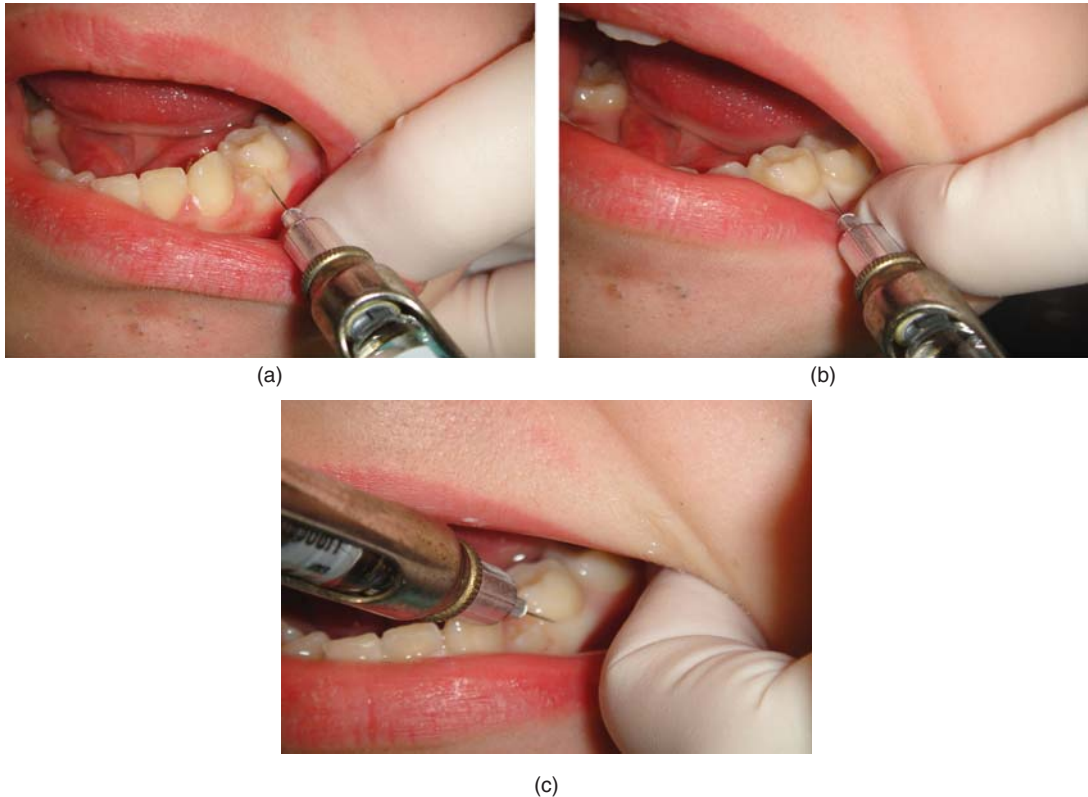


Figure 8.4 (a) Injection in mesial papilla. (b) Injection in distal papilla. (c) Injection into sulcus.

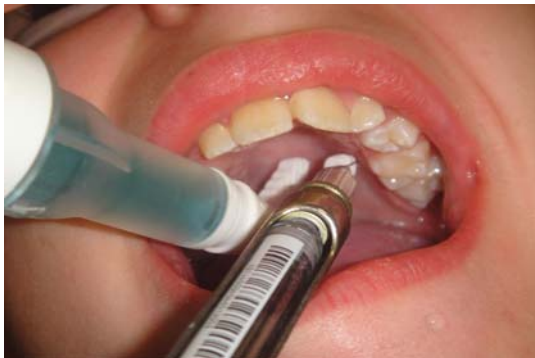

Figure 8.5 Palatal injection with DentalVibe.

Considerations with abscess

With localized infection, antibiotic coverage, before or after extraction, is not necessary for an asymptomatic,

healthy child. (American Academy of Pediatric Dentistry, 2014c; AAPD Reference Manual pp. 285). Any purulent material is gently curetted from the socket after the extraction. The source of infection has been removed, and so antibiotic coverage would not be prescribed after the extraction.

With concomitant temperature of 102 degrees Fahrenheit to 104 degrees Fahrenheit, facial swelling indicating spreading infection, or induration of the surrounding mucosa, an antibiotic should be prescribed. This coverage should begin several days prior to the extraction to provide immediate control and stop the spread of the infection. Antibiotic therapy should continue for a minimum of 5 days after significant resolution. Follow-up in 48 h to ensure improvement is recommended. If there is no improvement at that time, the child should be seen and a different antibiotic prescribed. Adequate local anesthesia may be delayed or unobtainable due to the lower pH of the tissues with

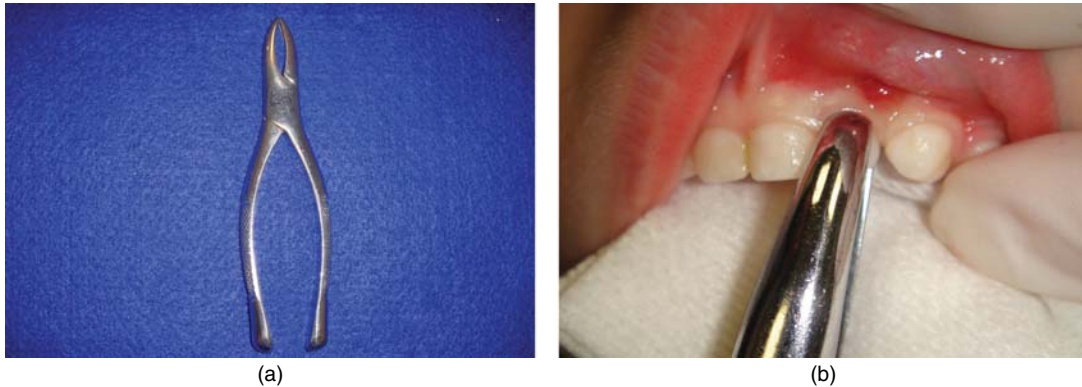


Figure 8.6 (a) Straight forceps for primary incisors. (b) Straight forceps extracting abscessed primary lateral incisor.

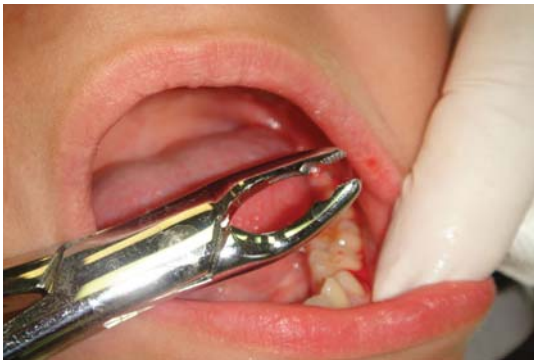

Figure 8.7 Serrated split beak forceps for primary molar extraction.

an acute infection. Physiologic pH is 7.4, but pH may be 5 or lower with infection and the inflammatory process, inhibiting uptake of the local anesthetic across the nerve sheath. In addition, injecting into infected tissue may spread the infection (American Academy of Pediatric Dentistry, 2014a; AAPD Reference Manual pp. 197–203). Intramuscular injection or hospitalization for intravenous antibiotic therapy may be necessary for spreading infection or for medically compromised children (American Academy of Pediatric Dentistry, 2014b; AAPD Reference Manual pp. 276–283).

After extraction

Prepare the parent/guardian for more bleeding with an abscess. One drop of blood mixed with copious saliva appears to be much more blood than in actuality. This

is important for both the parent/guardian and the child to understand. Sterile 2×2 folded gauze should remain in place, with teeth firmly held together for 15–20 min. Remind the parent/guardian and child that the gauze should not be repeatedly taken in and out of the mouth, interrupting blood clotting, during that period. Extra gauze may be provided for use as needed along with a plastic sandwich bag to discard saturated gauze after leaving the office.

For a very young child, a “ghost” can be made using 2×2 sterile gauze (Figure 8.9). A long strand of floss, attached to the gauze, will facilitate retrieval if necessary. The gauze should always be visible in the child’s mouth. The extracted tooth is placed in a plastic treasure chest selected by the child before the extraction. Without the child present, sparkles in a small envelope may be given to the parent/guardian. These sparkles are said to be from the tooth fairy’s wings and are sprinkled on the floor by the child’s bed that night.

If bleeding continues beyond 20 min, advise rinsing vigorously with room temperature water and biting on a wet tea bag. The tannic acid in tea aids in hemostasis. Plain tea is preferable to herbal tea. Tylenol may be recommended after extractions that required more forceful luxation. Nonsteroidal anti-inflammatories may also be suggested, but caution with asthmatics (Debley *et al.*, 2005).

A follow-up phone call from the dentist or a staff member the following day to check on the child is always appreciated by the parent/guardian.

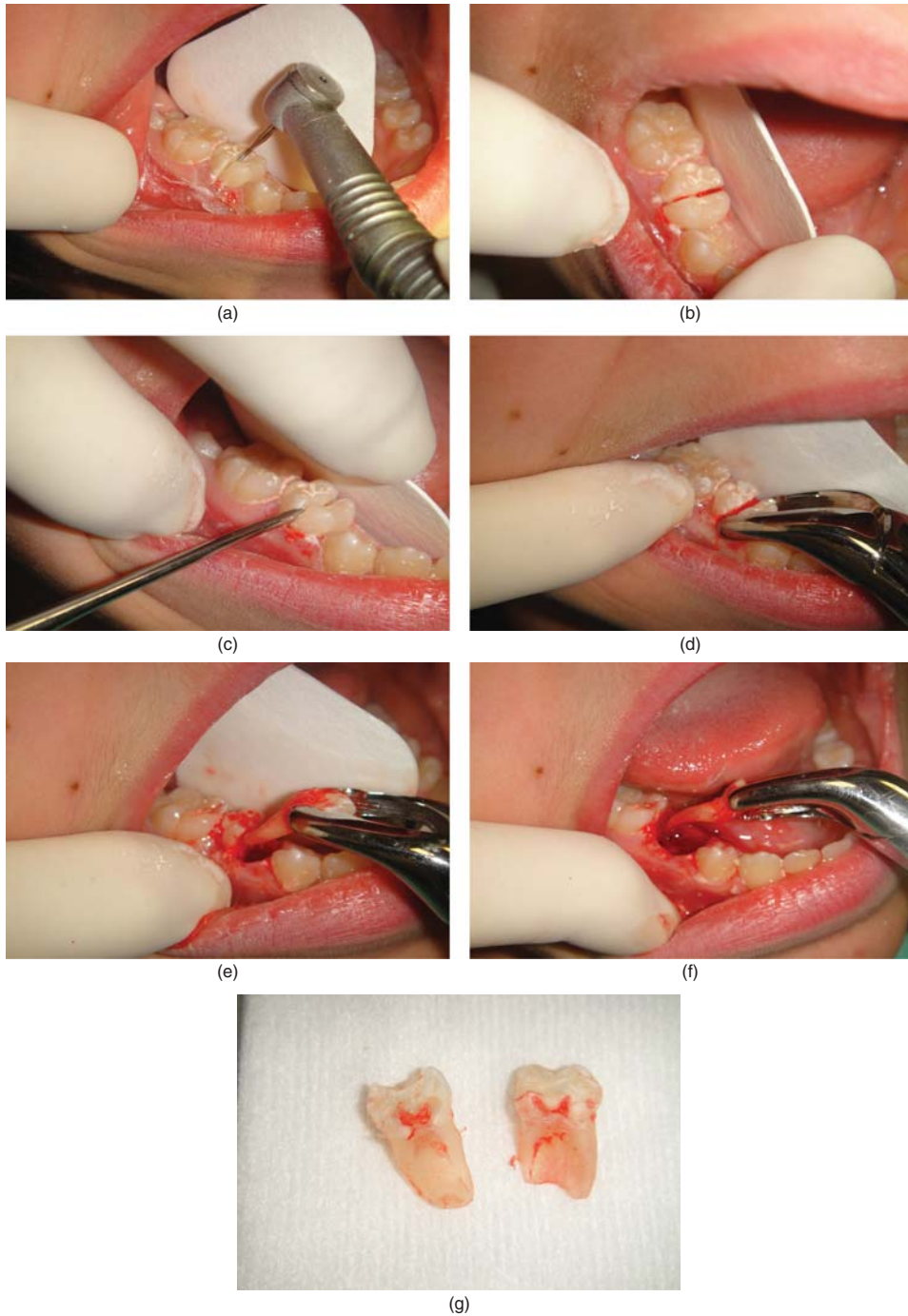


Figure 8.8 (a) 169L carbide bur to split primary molar from buccal to lingual. (b) Sectioned primary molar. (c) Luxation instrument to separate primary molar at furcation. (d) Extraction of mesial root of primary molar. (e) Extracting mesial root of primary molar from socket. (f) Extracting distal root of primary molar from socket. (g) Extracted, sectioned primary molar.



Figure 8.9 Ghost for young child.

References

- American Academy of Pediatric Dentistry. (2014a) Guideline on use of local anesthesia for pediatric dental patients. *Pediatric Dentistry*, **36** (special issue), 197–203.
- American Academy of Pediatric Dentistry. (2014b) Guideline on pediatric oral surgery. *Pediatric Dentistry*, **36** (special issue), 276–283.
- American Academy of Pediatric Dentistry. (2014c) Guideline on use of antibiotic therapy for pediatric dental patients. *Pediatric Dentistry*, **36** (special issue), 284–286.
- Debley, J.S., Carter, E.R., Gibson, R.L. *et al.* (2005) The prevalence of ibuprofen-sensitive asthma in children: a randomized controlled bronchoprovocation challenge study. *Journal of Pediatrics*, **147** (2), 233–238.
- Nakai, Y., Milgrom, P., Mancl, L. *et al.* (2000) Effectiveness of local anesthesia in pediatric dental practice. *Journal of the American Dental Association*, **131** (12), 1699–1705.

9

Sealants

Jane A. Soxman and Patrice B. Wunsch

According to the 2014 AAPD Guidelines, pit and fissure caries account for 80 to 90 percent of all caries in the permanent teeth and of 44 percent of all caries in the primary teeth. (American Academy of Pediatric Dentistry, 2014). The teeth at highest risk by far are the permanent first and second molars where fluoride has its least preventive effect on the pits and fissures. In children aged 5–17 years, 67–90% of caries occurs on occlusal surface of molars. The eruption time for first and second permanent molars is 1.5 years, but premolars take only 1–2 months (Antonson *et al.*, 2012). With consideration of all of these factors, sealants provide the best method to prevent occlusal caries in young permanent molars. Sealants on the occlusal surfaces of primary molars are retained at a rate of 74.0–96.3% at 1 year and 70.6–76.5% at 2.8 years (Table 9.1; Beauchamp *et al.*, 2008).

Permanent molars are highly porous at eruption and susceptible to caries. Complete maturation of the enamel does not occur until 62 months after eruption. Placing a sealant as soon as the tooth can be adequately isolated is highly efficacious in reducing the incidence of pit and fissure caries (Kataoka *et al.*, 2007). The risk for caries is the highest during the first few years after eruption.

When restoring the primary dentition, consideration may be given to sealing the occlusal surfaces of the primary molars in the high-caries risk child. This may be a good-will gesture, as insurance may not cover this procedure, but reduces and protects the occlusal surfaces for future colonization of mutans streptococcus.

Table 9.1 AAPD recommendations for sealant placement (American Academy of Pediatric Dentistry, 2014).

-
- Sealants should be placed into pits and fissures of teeth based on the patient's caries risk and not the patient's age or time elapsed since tooth eruption
 - Sealants should be placed on surfaces judged to be at high risk or surfaces that already exhibit incipient carious lesions to inhibit lesion progression. Follow-up care, as with all dental treatment, is recommended
 - Sealant placement methods should include careful cleaning of the pits and fissures without removal of any appreciable enamel. Some circumstances may indicate use of a minimal enameloplasty
 - A low-viscosity hydrophilic material bonding layer, as part of or under the actual sealant, is recommended for long-term retention and effectiveness
 - Glass ionomer materials could be used as transitional sealants
-

Source: American Academy of Pediatric Dentistry (2014). Reproduced with permission of American Academy of Pediatric Dentistry.

Caries detection

Forceful probing of occlusal surfaces with an explorer pierces immature, porous enamel, creating enamel defects and possibly converting incipient caries to frank cavitation (Kuhnisch *et al.*, 2007). An explorer may be gently run through the fissures to check for any changes or breaks in the enamel surface followed by forcefully rinsing with water to remove plaque and debris. Sealant

integrity and retention can also be evaluated with the explorer (Margherita *et al.*, 2010). Strassler *et al.* (2005) found laser fluorescence to be 90% accurate for caries detection. Laser fluorescence caries detection devices use a laser light to scan below the enamel surface detecting demineralized tooth structure. Prophylaxis pastes with blue or green dye produce an inaccurate reading. Staff can be taught to use the device, saving time for the dentist.

Moisture control

Inadequate moisture control is the primary reason for sealant loss. Resin-based sealants are hydrophobic and require isolation that assures no salivary contamination. Isolation may be accomplished with a rubber dam, cotton rolls ligated with dental floss, dri-aides/dry angles, Parkell dry-field mouth prop, the Isolite or Isodry, or the Blue Boa (Figures 9.1–9.4a, and 9.4b). With difficulty in moisture control, the Adper Prompt L-Pop (3M-ESPE), a self-etch adhesive, provides improved bonding. Fluoride varnish may also offer a moisture-tolerant alternative for a patient with a strong gag reflex or inability to cooperate for placement of glass ionomer or sealant but requires more frequent application.

Etching/primer

The occlusal surface should have a chaulky-white, opaque appearance after adequate etching and thoroughly air-drying. Salivary contamination will eradicate

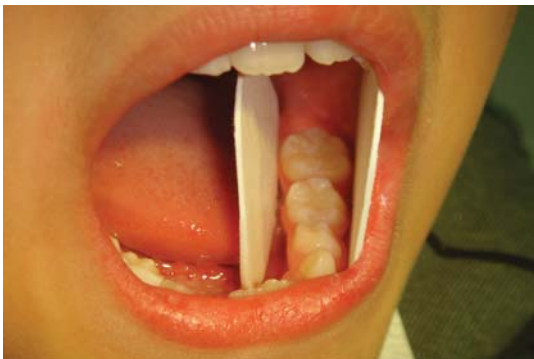

Figure 9.1 Dri-angles.

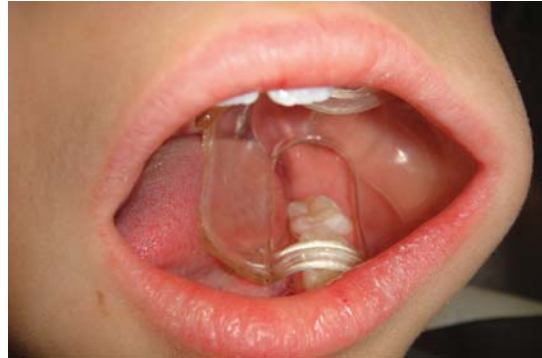

Figure 9.2 Parkell dry-field mouth prop.

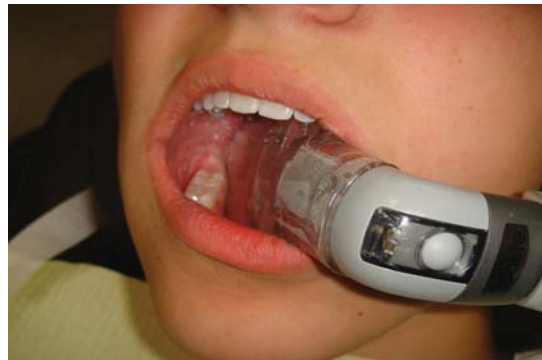

Figure 9.3 Isolite.

the etched enamel (Figure 9.5). An ethyl alcohol primer may be applied to insure dry enamel before placing the sealant.

Bonding agent

The use of a dentin bonding agent has been suggested if there is difficulty maintaining a dry field. If the enamel is contaminated with saliva, the intermediate bonding agent layer and the resin sealant may be light cured individually or simultaneously. If the tooth is dry, the bonding agent layer should be light cured separately from the resin sealant (Torres *et al.*, 2005).

For added retention, some advocate the use of a bonding agent between the sealant and the etched enamel. After enameloplasty is complete, etchant is placed, rinsed, and dried. A thin layer of bonding agent is then applied and lightly air-dried followed by a light

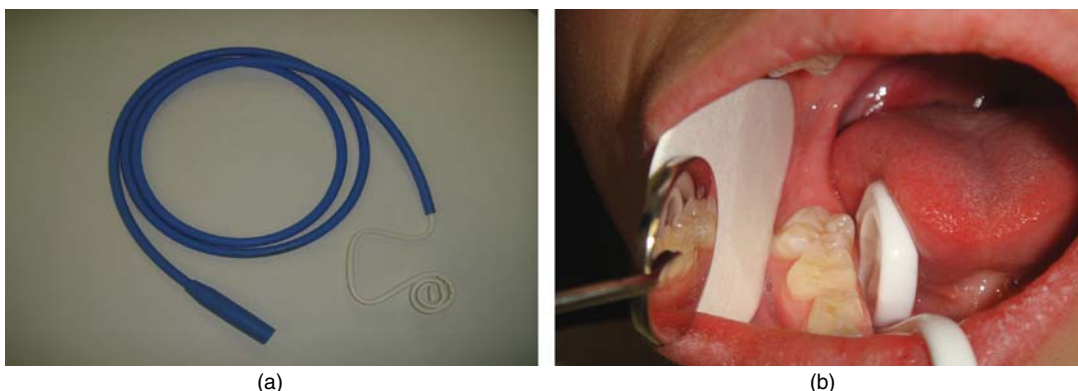


Figure 9.4 (a) Blue Boa. (b) Blue Boa.

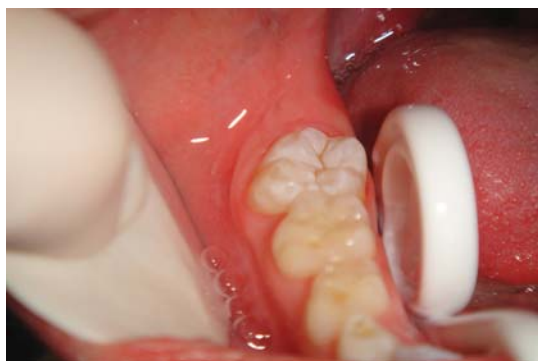

Figure 9.5 Chalky white appearance of adequately dried enamel.

layer of sealant. The two are cured together so that the bonding agent and sealant are one.

Etch and bonding agent may contribute to antimicrobial activity below the sealant, and their application may aid in preventing the survival of any viable bacteria left deep in the grooves (Paddick *et al.*, 2005).

A number of bonding agents work well in providing additional retentiveness for the sealant. Some are based on ease of use and provider preference.

1. OptiBond Solo Plus (www.kerrdental.com) comes in either bottle or unit dose.
2. Excite (<http://www.ivoclarvivadent.us/variolink/faqs.php>) comes in an easy-to-use click and bond dispenser tip.

Partially erupted teeth

Sealant placement in partially erupted teeth is difficult due to isolation challenges; therefore, it is recommended to use a material that is hydrophilic such as a glass ionomer type of sealant or glass ionomer cement. Something as easy as the placement of a glass ionomer liner cement (Vitrebond) in the grooves on an erupting permanent molar can help to prevent bacterial invasion in the depths of the grooves. The tooth is then monitored until it is fully erupted, at which time the glass ionomer cement is removed and replaced with either a resin-based sealant or glass-ionomer-based sealant. A low-viscosity, flowable, high-fluoride-releasing glass ionomer sealant (GC Fugii Triage White, GC America) provides another option for partially erupted molars in high-caries risk patient (Antonson *et al.*, 2012).

Surface preparation

Enameloplasty with a size 2 round diamond bur to open fissures before placing a sealant is sometimes recommended to identify or remove incipient caries and increase the bonding surface (Figure 9.6). Feigal and Donly (2006) found that marginal leakage was less in prepared fissures, but minimal application of sealant material rather than overfilling the fissure is probably more beneficial than enameloplasty. Sealant loss may predispose a tooth to caries, particularly if enameloplasty was performed before sealant placement (Dhar & Chen, 2012). Handpiece pumice prophylaxis

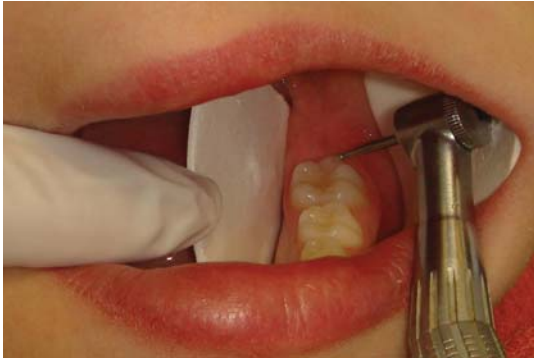

Figure 9.6 Enameloplasty with small round diamond bur.

does not increase sealant bond strength or retention. Retention was as high with a toothbrush prophylaxis as with a handpiece (Farsai *et al.*, 2010). In-office topical fluoride treatment does not interfere with the etching pattern and sealant retention (Feigal & Donly, 2006). This study was performed before the use of fluoride varnish for in-office topical fluoride treatment.

Light curing

Insufficient curing affects sealant retention. Clear sealant cures deeper than opaque (Yu *et al.*, 2009). Cusp tips place more distance between the polymerization light and the sealant. The curing depth should be 1.5 mm due to tags within the fissures. The curing light should touch the cusp tips to assure a deep enough cure (Figure 9.7).

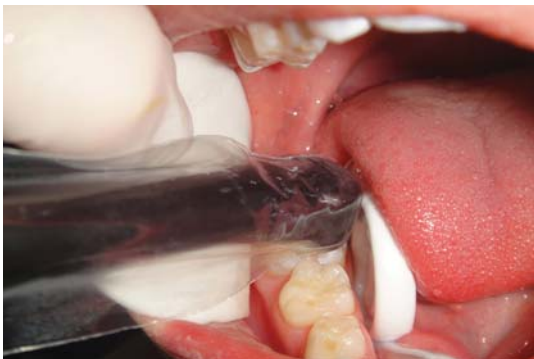

Figure 9.7 Curing light on cusp tips of molar.

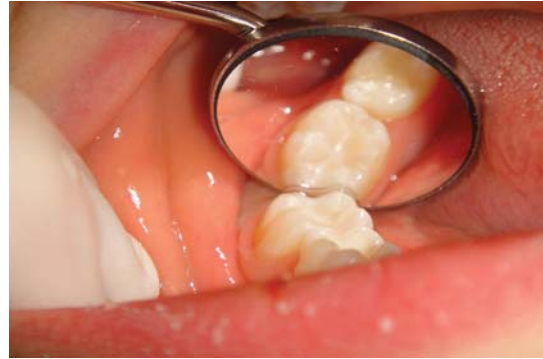

Figure 9.8 Sealant limited to fissures.

The curing light is routinely checked for light intensity with a curing radiometer. The tip of the light should be checked for material buildup and should fit the radiometer (Maghaireh *et al.*, 2013). Each material will include information on the recommended wavelength range for activation.

Retention and follow-up

Parents/guardians are informed of the various factors that influence sealant retention. Even under proper application conditions, 5–10% of sealants can be expected to fail annually (Yazici *et al.*, 2006). Sealant retention may be compromised due to behavior, poor oral hygiene, hypoplastic or hypocalcified enamel, severe bruxing, chewing hard candy, and caries susceptibility. Limiting sealant application to the fissures, avoiding the cuspal planes, will enhance retention (Figure 9.8). Compromised marginal integrity can result in caries developing beneath the sealant. Evaluation should include not only carefully checking margins, but also viewing from various angles with a good light source to detect the presence of a shadow, which is typically an evidence of caries below the sealant. Sealants require maintenance. The importance of preventive care follow-up visits to monitor marginal leakage, caries beneath the sealant, or sealant loss must be stressed.

References

American Academy of Pediatric Dentistry. (2014) Guideline on pediatric restorative dentistry. *Pediatric Dentistry*, **36** (special issue), 230–241.

- Antonson, S.A., Antonson, D.E., Brener, S. *et al.* (2012) Twenty-four month clinical evaluation of fissure sealants on partially erupted permanent first molars. *Journal of the American Dental Association*, **143**, 115–122.
- Beauchamp, J., Caufield, P.W., Crall, J. *et al.* (2008) Evidence-based clinical recommendations for the use of pit-and-fissure sealants. *Journal of the American Dental Association*, **139**, 257–267.
- Dhar, V. & Chen, H. (2012) Evaluation of resin-based and glass ionomer based sealants placed with or without tooth preparation—a two year clinical trial. *Pediatric Dentistry*, **34**, 46–50.
- Farsai, P.S., Uribe, S., Vig, K.W.L. *et al.* (2010) How to clean the tooth surface before sealant application. *Journal of the American Dental Association*, **141**, 696–698.
- Feigal, R.J. & Donly, K.J. (2006) The use of pit and fissure sealants. *Pediatric Dentistry*, **28**, 143–150.
- Kataoka, S.S., Wang, J., Yoshihara, A. *et al.* (2007) Changes of electrical resistance in sound fissure enamel in first permanent molars for 66 months from eruption. *Caries Research*, **41**, 161–164.
- Kuhnisch, J., Dietz, W., Stosser, L. *et al.* (2007) Effects of dental probing on occlusal surfaces: a scanning electron microscopy evaluation. *Caries Research*, **41**, 43–48.
- Margherita, F., Zero, D.T., Beltran-Aguilar, E.D. *et al.* (2010) Techniques for assessing tooth surfaces in school-based sealant programs. *Journal of the American Dental Association*, **141**, 854–860.
- Maghaireh, G.A., Alzraikat, H. & Taha, N.A. (2013) Assessing the irradiance delivered from light-curing units in private dental offices in Jordan. *Journal of the American Dental Association*, **144**, 922–927.
- Paddick, J.S., Brailsford, S.R. & Kidd, E.A.M. (2005) Phenotypic & genotype selection of microbiota surviving under dental restorations. *Appl Environ Microbiol*, **71**, 2467–2472.
- Strassler, H.E., Grebosky, M., Porter, J. *et al.* (2005) Success with pit and fissure sealants. *Dentistry Today*, **24**, 124–133.
- Torres, C.P., Balbo, P., Gomes-Silva, J.M. *et al.* (2005) Effect of individual or simultaneous curing on sealant bond strength. *Journal of Dentistry for Children*, **72**, 31–35.
- Yazici, A.R., Kiremitci, A., Celik, C. *et al.* (2006) A two-year clinical evaluation of pit and fissure sealants placed with and without air abrasion pretreatment in teenagers. *Journal of the American Dental Association*, **137**, 1401–1405.
- Yu, C., Tantbirojn, D., Grothe, R.L. *et al.* (2009) The depth of cure of clear vs opaque sealants as influenced by curing regime. *Journal of the American Dental Association*, **140**, 331–338.

10

Indirect pulp therapy for young permanent molars

Patrice B. Wunsch

Introduction

Young permanent teeth differ from mature permanent teeth in that the roots of young permanent teeth are not fully formed. The duration for root completion in the permanent molars is 3 years after full eruption of the tooth (American Academy of Pediatric Dentistry, 2011). This may vary between patients; therefore, obtaining a diagnostic radiograph to include the roots of the teeth is recommended before initiating any type of pulp therapy to not only rule out the possibility of periapical pathology, but also determine the apical development of the tooth (Figure 10.1).

There are certain advantages of treating young permanent teeth with immature roots. The pulp biology varies in that permanent teeth with immature roots have a more viable pulp that will respond more favorably to insult and treatment therapies than permanent teeth with fully formed roots (Trope, 2008). This is discussed in greater detail under the treatment modalities section of this chapter.

Background

As the permanent molars erupt into the oral cavity, there is a likelihood that the pits and fissures of the occlusal surface are composed of uncoalesced enamel, meaning that the enamel surface is not intact and the potential for bacterial invasion of the dentinal subsurface is high. This in itself will predispose the tooth to develop a large carious lesion before the tooth has fully erupted into the oral cavity. In addition, the position of the partially

erupted permanent molars places the tooth at risk for plaque accumulation. Sometimes, the molar is not in contact with the opposing teeth, thereby not allowing the self-cleansing action of the occlusal surfaces coming in contact. Also, young patients are not as efficient at brushing the posterior teeth compared to their ability to clean the teeth positioned more anteriorly (Antowson *et al.*, 2012).

Indications for indirect pulp therapy on young permanent molars

In the event of deep caries in a young permanent tooth, the practitioner is faced with numerous factors that will affect the success of treatment.

1. Patient behavior and level of cooperation.
2. Preoperative symptoms.
3. Apical development of the tooth.

In a patient who has minimal coping skills, indirect pulp therapy (IPT) is a viable option in that it allows one to atraumatically arrest the caries process until trust and cooperation are achieved or some other means of behavior management are successful in order to provide care. There is a two-step (stepwise) method of IPT that would lend itself well for the patient who has poor coping skills. The provider will initially use a spoon excavator to remove gross caries and food debris followed by the placement of a glass ionomer (GI) temporary restoration. This has been extremely helpful because not only does this treatment relieve the symptoms associated with the open lesion, but also affords the dentist time to schedule more definitive care

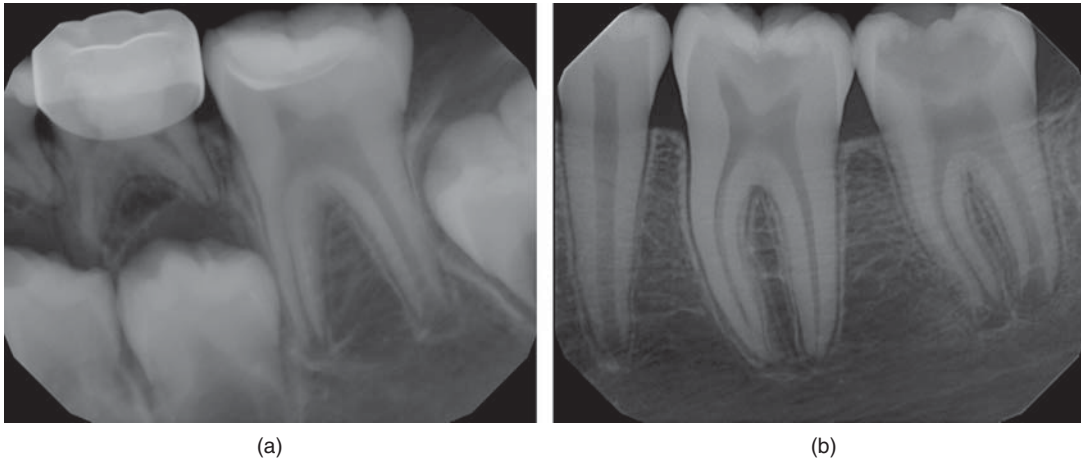


Figure 10.1 (a and b) Young immature permanent molars, note incomplete closure of the root apices (contributed by Dr. Claudia Colorado, VCU Department of Endodontics).

at a later date. The medicament placed on the remaining caries changes the characteristic of the carious tooth structure that is left behind after initial excavation (Maltz *et al.*, 2007; Orhan *et al.*, 2008). The stepwise IPT technique is described later in this chapter under technique.

Diagnosis

A comprehensive review of the patient's medical and dental history must be initially completed. The clinical examination includes an intraoral and extraoral examination of the hard and soft tissues associated with the area of the patient's chief complaint. Radiographic examination to include a bitewing and periapical radiographs should be taken. The bitewing is used to evaluate the extent of the caries and its proximity to the pulp. The periapical radiograph is used to look for signs of periapical pathology. The tooth in question should have clinical tests such as percussion and palpation to assess for periapical pathology or mobility. Electric pulp testing and cold tests can be unreliable in young immature teeth with developing roots (Camp, 2008).

However, cold tests can be useful when the caries as noted on a radiograph approximates the pulp or when pathosis is noted on the periapical radiograph.

To differentiate between reversible and irreversible pulpitis, initial cold tests can be used to provide a

baseline on which the tooth can be monitored for pulpal changes.

Indirect pulp therapy is indicated for teeth with signs of reversible pulpitis

Symptoms consistent with the diagnosis of reversible pulpitis include pain brought on by a stimulus (usually sweets or cold). The pain will subside after the stimulus is removed. Radiographically, the periapical film shows no signs of periapical pathology, and the bitewing film shows caries encroaching on the pulp but not into the pulp. Similarly to primary teeth, young immature permanent teeth do not respond reliably to electric pulp testing or cold tests. Therefore, the most reliable indicator for treatment is the history of symptoms and the clinical/radiographic examination.

Signs and symptoms consistent with a diagnosis of irreversible pulpitis are spontaneous pain, sensitivity to cold liquids or cold air, and radiographic signs of a widened periodontal ligament.

Signs and symptoms consistent with a diagnosis of necrotic pulp are spontaneous pain (patient wakes often at night in pain), swelling associated with the tooth, presence of a parulis, and often signs of a radiolucent lesion (periapical pathology).

Teeth that have a diagnosis consistent with irreversible pulpitis or a necrotic pulp are not candidates for IPT or other vital pulp therapies.

Young immature permanent teeth, due to their highly vascular pulp, have the potential to heal and withstand carious insult better than mature permanent teeth with fully formed roots (Ward, 2002).

As early as the 1960s, a comprehensive study was performed by the Eastman Dental Center. Investigators found “after histological evaluation of the teeth selected for IPT that had all caries been removed, pulpal exposure would have occurred. In addition, only 3% of 475 teeth treated with IPT resulted in frank clinical failure.” This study has demonstrated that clinicians should not aggressively remove all carious dentin in an effort to leave none behind and risk exposing the pulp (Ranly & Garcia-Godoy, 2000).

What is indirect pulp therapy (IPT)?

Indirect pulp therapy involves the incomplete removal of carious dentin. Cariously involved dentin is divided into two layers. The layer that is more coronal to the pulp is described as the infected layer or infected dentin. Contained within this layer are viable cariogenic bacteria. This layer is “dead tissue with both organic and inorganic components irreversibly deteriorated that is deemed infected and nonremineralizable.” During the IPT procedure, this layer is removed. The remaining layer that is in close proximity to the pulp is called the affected layer or affected dentin. Within the affected layer lay the “organic and inorganic components present with sound structure and character but are slightly and reversibly degenerated, uninfected, and physiologically remineralizable” (Orhan *et al.*, 2010). It is this layer on which a biocompatible material is placed to aid in remineralization. In order for the procedure to be successful, the tooth must be sealed from bacterial invasion. It is recommended that the final restoration be one that would not allow for any leakage around the margins. With this in mind, sealing the final restoration has been shown to decrease or prevent marginal leakage, thereby improving treatment success (Mertz-Fairhurst, 1998).

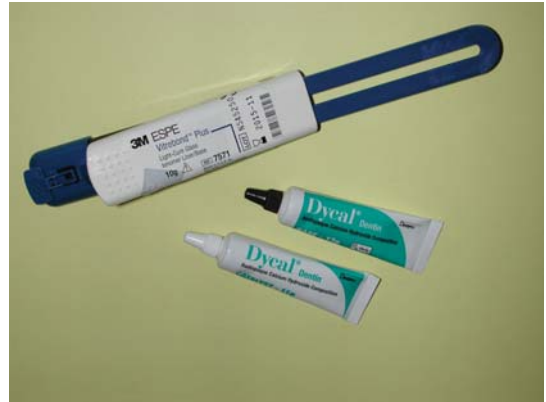

Figure 10.2 Vitrebond and Dycal (contributed by Dr. Claudia Colorado, VCU Department of Endodontics).

Medicaments: glass ionomer (Vitrebond) and calcium hydroxide (Dycal) (Figure 10.2)

Dycal is available in hard-setting and light-cured forms. The high pH of the calcium hydroxide in Dycal has a bactericidal effect, and calcium hydroxide is able to induce mineralization (Foreman & Barnes, 1990).

GI is available as a liner or a restorative type. The most popular GI type is Vitrebond (3M ESPE). This lining material can be placed in close proximity to the pulp where its anticariogenic ability (due to fluoride release) is most effective.

GI restorative materials include Fugii II/IX (GC America), Ketac Molar (3M ESPE), and Photac Fil (3M ESPE). The GI restorative materials can be used as temporary restorations (stepwise technique) or as a base over the IPT as added protection for the pulp before the final restoration.

In general, GIs have been shown to inhibit the growth of cariogenic bacteria due to their ability to release fluoride.

How does fluoride affect certain oral bacteria *in vivo*?

Fluoride indirectly affects mutans streptococci (MS) by limiting their ability to produce acid and thereby preventing a decrease in pH (Hamilton, 1990).

Chronic exposure to fluoride may decrease the population of MS while increasing the number of more alkaline species (Hamilton, 1990).

GI releases a high concentration of fluoride after its initial application. Over time, the concentration of fluoride decreases, and therefore more importance is placed on the ability of the final restoration to create an adequate seal.

Both Dycal and Vitrebond are considered good lining materials for IPT in young immature permanent teeth. Marchi *et al.* have studied IPT in primary teeth. The authors believe that IPT is not a material-dependent treatment and that a good marginal seal of the final restoration and controlling the caries-inducing activities of the patient will ensure success (Marchi *et al.*, 2006).

Indirect pulp therapy technique

After careful assessment of the radiographs (Figure 10.3) and preoperative symptoms, the tooth is anesthetized, and a rubber dam is used to isolate the tooth.

A number 14A clamp is recommended for the first and second permanent molars. Depending on the age of the child and the presence or absence of the second permanent molar, the clamp is placed on the tooth receiving treatment or on the tooth behind it. For example, if deep caries exists on tooth #19 and the child is aged 8 years, the clamp is placed on tooth #19 because the second permanent molar does not usually erupt until the age

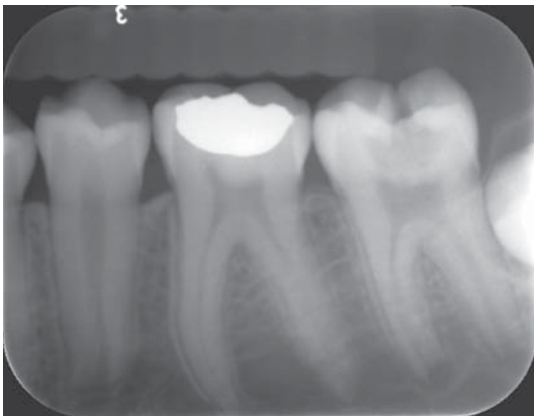


Figure 10.3 Preoperative radiograph of tooth #18 with deep caries and incomplete closure of root apex (contributed by Dr. Patrice Wunsch, VCU Department of Pediatric Dentistry).

12 years (Figure 10.4). If the child is aged 13 years and the first permanent molar requires treatment, the clamp can be placed on the second permanent molar and extended into the premolar region.

Once isolation is obtained and the patient is anesthetized, a 557 or 330 bur is used to gain coronal access to the lesion. After initial preparation, the caries is carefully removed with a #8 round bur (Figure 10.5).

The larger diameter round bur decreases the chance of exposure as compared to using a #4 round bur. Avoid using a spoon excavator, as using this instrument can result in removing chunks of decay resulting in a pulp exposure. If hand instruments are used, they should be used only to remove caries at the dentin–enamel junction, taking care not to produce a pulp exposure (Hargreaves & Cohen, 2011).

As the excavation deepens, care must be taken not to place apical pressure on the handpiece in order to avoid pulpal exposure. Rather, the round bur is used in a more peripheral manner to remove all of the caries from the preparation walls and then carefully move the bur in a circular motion toward the area of deepest caries on the cavity floor (Figure 10.6).

At this point, caries will be evident on the cavity floor, right above the pulp chamber. Once the operator has reached the point where he or she feels that further apical excavation would result in a pulpal exposure and the cavity walls are clean, the handpiece is no longer used, and careful examination of the remaining caries is made (Figure 10.7).

According to the literature, if the remaining caries is hard and dry, either medicament (calcium hydroxide or GI) is placed followed by the final restoration (Figure 10.8).

If the remaining caries is soft and wet, the operator can make the decision to place calcium hydroxide or GI and temporize the tooth to allow the medicaments to change the characteristics of the caries and reenter the tooth later to complete caries removal. This technique allows for a change in the cultivable flora deep in the carious lesion where before placement of the medicament, the soft wet caries contains a high bacterial count, whereas afterward, the bacterial count is greatly reduced and the caries becomes more dry and hard (Vij *et al.*, 2004; Bjorndal & Larsen, 2000). However, some researchers have found that when the tooth is reentered, the pulp is exposed in an effort to remove the remaining caries (Leksell *et al.*, 1996). Research




Figure 10.4 (a) Rubber dam placement, #18 is isolated with #14A rubber dam clamp (contributed by Dr. Patrice Wunsch, VCU Department of Pediatric Dentistry). b. Preoperative photo of tooth #18 (contributed by Dr. Patrice Wunsch, VCU Department of Pediatric Dentistry).



Figure 10.5 Slow-speed handpiece with the #8 round bur (contributed by Dr. Patrice Wunsch, VCU Department of Pediatric Dentistry).

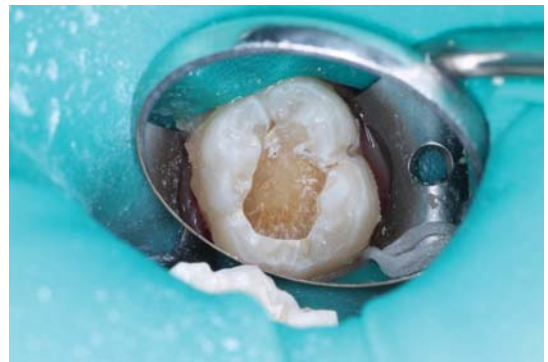

Figure 10.7 Caries excavation nearly completed (contributed by Dr. Patrice Wunsch, VCU Department of Pediatric Dentistry).

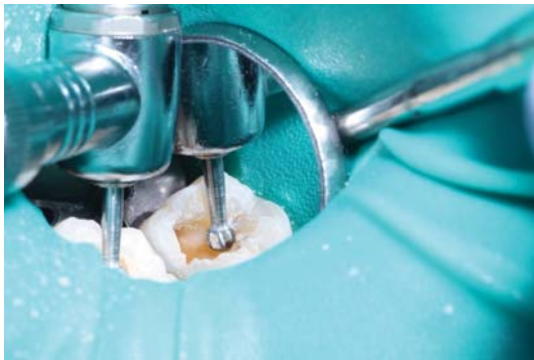

Figure 10.6 Initial excavation with #8 round bur (contributed by Dr. Patrice Wunsch, VCU Department of Pediatric Dentistry).

has found that there is no difference in the successful outcome between the two-step (stepwise) and the one-step techniques (Oliveira *et al.*, 2006; Orhan *et al.*, 2010). In the one-step technique, caries is removed as explained previously, and whether the remaining caries is wet or dry, the medicaments are placed followed by the final restoration. It is felt that as long as a sealed restoration is placed the remaining bacteria whether the count is high or low cannot survive and the young immature tooth is allowed to heal and continue to develop (Figure 10.9; Bjorndal & Larsen, 2000).

If the operator is not comfortable in leaving wet soft caries and does not feel that patient would tolerate having the tooth temporized and then reentered (stepwise technique), one can continue to remove the caries until

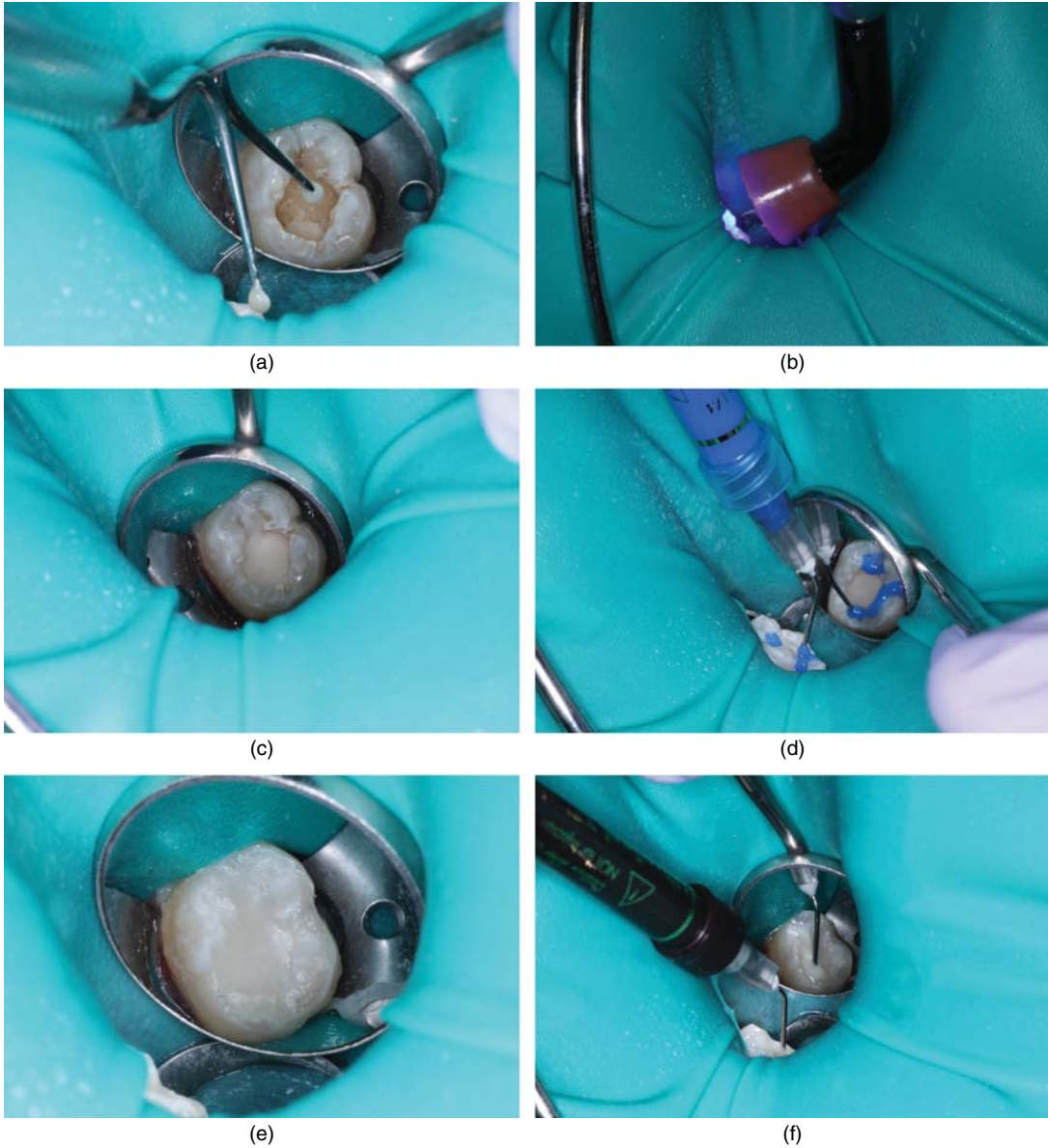


Figure 10.8 (a) Placement of Vitrebond over the remaining caries (contributed by Dr. Patrice Wunsch, VCU Department of Pediatric Dentistry). (b) Light cure of the Vitrebond (contributed by Dr. Patrice Wunsch, VCU Department of Pediatric Dentistry). (c) Glass ionomer liner (Vitrebond) is cured (contributed by Dr. Patrice Wunsch, VCU Department of Pediatric Dentistry). (d) Following the placement of the glass ionomer base, the tooth is etched in preparation for the final restoration (contributed by Dr. Patrice Wunsch, VCU Department of Pediatric Dentistry). (e) Final restoration is placed and cured (contributed by Dr. Patrice Wunsch, VCU Department of Pediatric Dentistry). (f) Sealant is placed over the composite (contributed by Dr. Patrice Wunsch, VCU Department of Pediatric Dentistry).

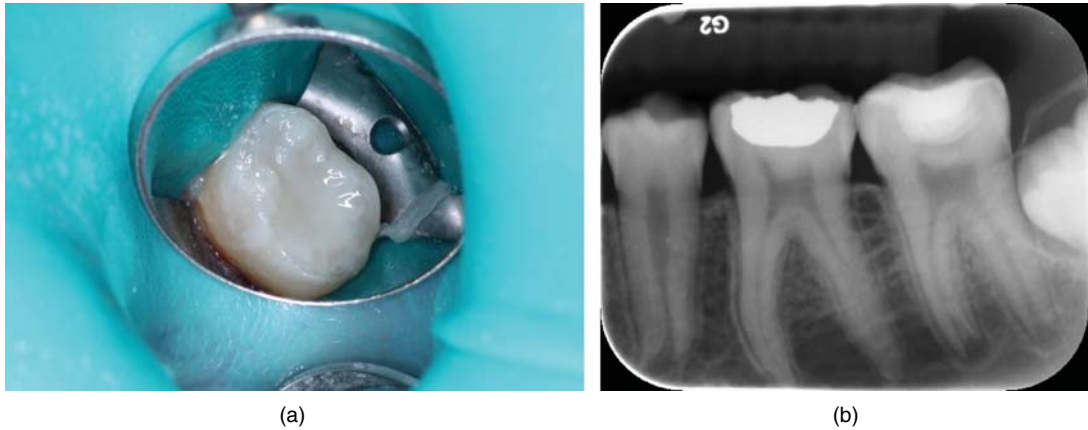


Figure 10.9 (a) Tooth #18 with completed restoration (contributed by Dr. Patrice Wunsch, VCU Department of Pediatric Dentistry). (b) Tooth #18 postoperative radiograph of completed treatment (contributed by Dr. Patrice Wunsch, VCU Department of Pediatric Dentistry).

the dryer caries is reached. This poses a risk for exposure, and depending on how deep the caries is, it brings great comfort to know that as long as a sealed final restoration is placed, there is no need to risk exposure, and the operator should stop excavation at the point where the risk of exposing the pulp is evident.

IPT is completed after the bulk of carious-involved tooth structure is removed and only a small amount of carious material is left behind to avoid exposing the pulp. Calcium hydroxide or GI (Table 10.1) is placed over the remaining caries followed by a reinforced or

nonreinforced GI base such as 3M's Ketac molar, Photac Fil, Fugii II, or Fugii IX (Table 10.2).

The two-paste system for calcium hydroxide (Dycal) is also available for the GI (Vitrebond). These two-paste systems are more favorable to the powder liquid systems because there is less chance of incorporating too much liquid or too much powder, thereby altering the intended properties of the material.

Once the IPT is complete, the liner should be covered with a GI base for added protection to the pulp. Any of the materials listed in Table 10.2 will serve this purpose well.

Table 10.1 Frequently used cavity liner products.

Material	Composition	Radiopaque	Self-/light cure	Manufacturer
Vitrebond	Resin-modified glass ionomer	Yes	Light cure	ESPE 3M
Dycal	Calcium hydroxide	Yes	Self-cure	Dentsply

Table 10.2 Frequently used glass-ionomer-based interim restorative materials.

Material	Composition	Radiopaque	Self-/light cure	Manufacturer
Ketac Molar	Conventional glass ionomer	No	Self-cure	ESPE 3M
Photac Fil	Resin-modified glass ionomer	Yes	Dual cure	ESPE 3M
Fugii II LC	Resin-modified glass ionomer	Yes	Light cure	GC America
Fugii IX	Conventional glass ionomer	No	Self-cure	GC America

Follow-up

The patient is rescheduled for a follow-up after 6 months when the treatment is examined both clinically and radiographically. If the treatment is successful, routine recalls are scheduled every 6 months with radiographs planned at 1-year intervals.

Criteria for indirect pulp therapy success

1. Vitality is preserved.
2. No pain, sensitivity, or swelling.
3. No radiographic evidence of internal or external resorption or other periradicular pathology.
4. Continued apexogenesis.

Success rate

One study has found that there is a high success rate for IPT on permanent teeth with deep carious lesions. In the study, 94 teeth were treated with the stepwise excavation process. Only five teeth experienced pulpal exposure on the final excavation; the remaining teeth were successful after a 1-year observation period. The authors concluded from this study that it is possible for general dentists to manage deep caries with IPT and thus prolong the vitality of the tooth (Bjorndal & Thylstrup, 1998).

In 2010, Gruythuysen *et al.* published a study on the long-term survival of IPT in primary and permanent teeth with diagnosed deep carious lesions. The patient's age ranged from 4 to 18 years. The lesion depth was greater than two-thirds of the dentin thickness. There were 125 primary molars and 45 permanent molars included in the study. One-step IPT was performed (gross caries removed leaving small amount of affected dentin on which Vitrebond was placed followed by the final restoration). The survival rate for IPT on the primary molars was 96% with a mean survival time of 145.6 weeks (2.8 years) and for the permanent teeth the mean survival rate was 93% with a mean survival time of 178.1 weeks (3.4 years) (Gruythuysen *et al.*, 2010).

Final restoration

The type of restoration depends on the size of the preparation and the condition of the remaining tooth structure. If the access preparation is small and the surrounding tooth structure is healthy, either a sealed composite or amalgam is suitable. This can include a conservative class one or two restoration. If, however, the preparation is large and the supporting tooth structure is weak (demineralized or hypoplastic enamel), the restoration of choice is the stainless steel crown (SSC) in the young patient with the understanding that this is a successful interim restoration that is designed to last until the patient has completed his or her growth and at which time a permanent full cast restoration can be completed.

Composite

After IPT is completed and a therapeutic base material has been placed, the cavity walls should be refreshed by running a bur along them to clean any residual GI material in preparation for the acid etch. Next, the cavity walls are etched for 15–20 s and then rinsed and dried. The bonding agent is placed and lightly dried with air to create a thin layer; it is then cured for 10 s. Packable composite is placed, the occlusion is checked, and the surface is reetched; bond is placed and thinned with air followed by a thin application of sealant (they are cured together for 20 s). The composite is now sealed to help prevent marginal leakage that can lead to bacterial invasion and possible failure of the IPT procedure (Mertz-Fairhurst, 1998).

Amalgam

After IPT and base material placement, the cavity walls are freshened. An amalgam-bonding agent such as Amalgambond Plus (Parkell) can be used to reduce the chance of marginal leakage. Another way to reduce the chance of marginal leakage is to repeat the steps mentioned previously in sealing the composite. Research has shown that a sealed composite or amalgam greatly decreases the chance of marginal leakage resulting in bacterial invasion (Mertz-Fairhurst, 1998).

Permanent stainless steel crown

In the event of a three or more surface restoration, or enamel/dentinal defects, the SSC is the restoration of choice in a growing child. It will provide an adequate seal to ensure therapy success while providing the strength to resist proximal breakdown that can result in the loss of arch space over time.

Permanent SSCs must be adapted to the tooth with care because an oversized SSC on a first or second permanent molar can result in creating an ectopic eruption of the permanent molar distal to it, as it can become trapped under a large distal overhang of the SSC on eruption.

After IPT and base material placement, the tooth is prepped for the SSC. Keep in mind the basic principles of preparation design taught by our prosthodontic colleagues. The concept of parallel walls is just as important while prepping a permanent tooth for the SSC as they are for the full cast crown. Firstly, a football-shaped diamond bur works well for the occlusal reduction. One can use either the 169L or flame-shaped diamond bur for both the occlusal reduction and then also used for the interproximal or axial wall reduction. The SSC is an interim restoration that will one day require a full cast crown; therefore, aggressive overpreparation of the tooth should be avoided.

Once ideal preparation has been completed, selection of the SSC is made. There are two types of basic SSC forms available. There is the precontoured type and the uncountoured type. The uncountoured SSC is sometimes referred to as a tin can because the walls of the crown are straight and lack contour. The advantage of the precontoured SSC is that it is designed to resemble the first permanent molar in its cervical adaptation to the tooth. However, teeth do vary in size and shape, and

the cervical constriction of these crowns can make them somewhat difficult to fit.

The advantage of the uncountoured SSC is its disadvantage as well. They require manipulation to create a good fit resulting in more chair time but allowing the crown to have a more customized fit.

Steps for fitting an uncountoured SSC are as follows.

1. After tooth preparation is complete, an uncountoured SSC is selected that best fits the tooth.
2. Some brands will be pretrimmed to optimum length to save time, but if that is not the case, after the initial placement of the crown, the crown is marked using an explorer to etch a line along the cervical area where the gingival tissue meets the crown.
3. The crown is then trimmed with a curved crown scissors or a heatless stone to 1 mm below (cervical) the etched line.
4. The crown is then tried on the tooth to check the fit. If the fit is loose (which should be the case – if not, the crown may be too small), the crown will need to be contoured. This is accomplished by using a contouring pliers or crown crimping pliers, ones similarly used by pediatric dentists.
5. Once a tight fit is accomplished, the SSC is ready for cementation.

Stainless steel crown cements

GI cements have gained popularity and are widely used by pediatric dentists for cementation of primary tooth and permanent tooth SSCs. Some of the more popular cements are listed in Table 10.3.

After the cement has reached its initial set, care must be taken to floss the interproximal areas and clear the sulcus of excess cement. Residual cement left in these

Table 10.3 Glass ionomer cements.

Material	Composition	Self-/light cure	Set time*	Manufacturer
FujiCem	Resin-reinforced glass ionomer	Self-cure	4.5 min	GC America
Ketac cement	Glass ionomer	Self-cure	7 min	3M ESPE
RelyX Luting cement	Resin-reinforced glass ionomer	Self-cure	10 min	3M ESPE
RelyX Luting Plus cement	Resin-reinforced glass ionomer	Self-cure	2 min	3M ESPE

*Manufacturers set time descriptions vary. Some list the actual hard-set time, and others list the amount of time necessary to set before the clinician is able to manipulate the restoration.

areas can make it more difficult to floss and result in gingival inflammation.

References

- American Academy of Pediatric Dentistry (2011) Growth and development. In: *Handbook of Pediatric Dentistry*, 4th. Chapter 2 edn, pp. 35.
- Antowson, S.A., Antonson, D.E., Brener, S. *et al.* (2012) Twenty-four month clinical evaluation of fissure sealants of partially erupted permanent first molars. *Journal of the American Dental Association*, **143**, 115–122.
- Bjorndal, L. & Larsen, T. (2000) Changes in the cultivable flora in deep carious lesions following a stepwise excavation procedure. *Caries Research*, **34**, 502–508.
- Bjorndal, L. & Thylstrup, A. (1998) A practice-based study on stepwise excavation of deep carious lesions in permanent teeth: a 1-year follow-up study. *Community Dental Oral Epidemiology*, **26**, 112–118.
- Camp, J. (2008) Diagnostic dilemmas in vital pulp therapy: treatment for the toothache is changing, especially in young, immature teeth. *Pediatric Dentistry*, **30** (3), 197–205.
- Foreman, P.C. & Barnes, I.E. (1990) A review of calcium hydroxide. *International Endodontic Journal*, **23**, 283–297.
- Gruythuysen, R., van Stijp, G. & Wu, M. (2010) Long-term survival of indirect pulp treatment performed in primary and permanent teeth with clinically diagnosed deep carious lesions. *Journal of Endodontics*, **36** (9), 1490–1493.
- Hamilton, I.R. (1990) Biochemical effects of fluoride on oral bacteria. *Journal of Dental Research*, **69** (Special Issue), 660–667.
- Leksell, E., Ridell, K., Cvek, M. & Mejare, I. (1996) Pulp exposure after stepwise versus direct complete excavation of deep carious lesions in young posterior permanent teeth. *Endodontics & Dental Traumatology*, **12**, 192–196.
- Maltz, M., Oliveira, E.F., Fontanella, V. & Carminative, G. (2007) Deep caries lesions after incomplete dentine caries removal: 40-month follow-up study. *Caries Research*, **41**, 493–496.
- Marchi, J.J., de Araujo, F.B., Froner, A.M., Straffon, L.H. & Nor, J.E. (2006) Indirect pulp capping in the primary dentition: a 4 year follow-up study. *Journal of Pediatric Dentistry*, **31** (2), 68–71.
- Mertz-Fairhurst (1998) Ultraconservative and cariostatic sealed restorations: results at year 10. *Journal of the American Dental Association*, **129**, 55–66.
- Oliveira, E.F., Carminatti, G., Fontanella, V. & Maltz, M. (2006) The monitoring of deep caries lesions after incomplete dentine caries removal: results after 14–18 months. *Clinical Oral Investigations*, **10**, 134–139.
- Orhan, A.I., Oz, F.T., Ozcelik, B. & Orhan, K. (2008) A clinical and microbiological comparative study of deep carious lesion treatment in deciduous and young permanent molars. *Clinical Oral Investigations*, **12**, 369–378.
- Orhan, A.I., Oz, F.T. & Orhan, K. (2010) Pulp exposure occurrence and outcomes after 1- or 2-visit indirect pulp therapy vs complete caries removal in primary and permanent molars. *Pediatric Dentistry*, **32** (4), 347–355.
- Hargreaves, K. & Cohen, S. (2011 Chapter 23) Related clinical topics. In: *Pathways to the Pulp*, 10th edn, pp. 822.
- Ranly, D.M. & Garcia-Godoy (2000) Current and potential pulp therapies for primary and young permanent teeth. *Journal of Dentistry*, **28**, 153–161.
- Trope, M. (2008) Regenerative potential of dental pulp. *Journal of Endodontics*, **34** (7S), S13–S17.
- Vij, R., Coll, J., Shelton, P., & Farooq, N. (2004) Caries Control and Other Variables Associated With Success of Primary Pulp Therapy. *Pediatric Dentistry*, **26** (3), 214–220.
- Ward, J. (2002) Vital pulp therapy in cariously exposed permanent teeth and Its limitations. *Australian Endodontic Journal*, **28** (1), 29–37.

Direct pulp therapy for young permanent molars

Patrice B. Wunsch

Introduction

As previously discussed in Chapter 10, young immature permanent teeth respond more favorably to insult and treatment therapies. The same principle holds true when considering direct pulp therapy in young immature permanent teeth. Young permanent teeth have immature pulps and incomplete root formation. Not only are the root ends not fully closed, but the root canal walls are thin and fragile. In the event of pulp exposure, if the tooth exhibits signs of reversible pulpitis, every effort should be made to maintain pulp vitality and allow the tooth to continue to develop naturally (apexogenesis). If direct pulp therapy is not possible and nonsurgical root canal treatment is indicated before the tooth has fully developed, an apexification procedure would be performed in an effort to obtain root end closure and an adequate apical stop. However, the apexification procedure does not allow for continued development of the root. A tooth that is not able to fully develop will result in having thin root canal walls and is at risk for fracture (Ward, 2002).

Background

Direct vital pulp therapy in cariously involved teeth is diagnostically and technique dependent. The following are critical for success (Ward, 2002):

- An accurate diagnosis of reversible pulpitis
- Caries removal to include the infected pulp tissue
- Use of aseptic technique (rubber dam isolation, irrigation)

- Prevention of bacterial leakage with a permanent restoration

As early as 1993, Mejare and Cvek wrote a paper reviewing the partial pulpotomy in carious teeth. They surmised that bacteria are able to gain access to the pulp lumen only after some portion of the coronal pulp has become necrotic (Mejare & Cvek, 1993). In order to preserve the remaining pulp, the infected dentin and inflamed pulp must be removed and a biocompatible material which promotes the reparative process is placed over the pulp. In the past calcium hydroxide ($\text{Ca}(\text{OH})_2$) has been the material of choice for direct pulp therapy. Long-term follow-up of cariously involved permanent molars that received $\text{Ca}(\text{OH})_2$ pulpotomy treatments resulted in a 44.5% failure rate at 5 years and 79.7% failure rate at 10 years (Witherspoon *et al.*, 2006). Recently, mineral trioxide aggregate (MTA) has proven to be successful in vital pulp therapy. Analogous to $\text{Ca}(\text{OH})_2$ (pH of 12), MTA is highly basic (pH of 12.5) and is biocompatible. The goals of a successful pulp capping material are as follows:

- the ability to kill bacteria
- the ability to promote mineralization
- the ability to withstand bacterial invasion (bacterial tight seal).

MTA to a great extent fulfills the desired goals of a pulp capping/pulpotomy material. It has the ability promote mineralization and a dentinal bridge faster and more effectively than $\text{Ca}(\text{OH})_2$. It does however have a weak antibacterial effect; in fact it is less antibacterial than $\text{Ca}(\text{OH})_2$. Regardless, MTA does have the advantage of providing an enhanced nonresorbable seal over the vital pulp. Its ability to seal out bacteria is to a great extent

why the material has been so successful. According to El Meligy and Avery (2006), $\text{Ca}(\text{OH})_2$ does not provide any protection from microleakage.

MTA has many advantages but it does have the disadvantage of being rather expensive; it costs \$425 for one system (approximately \$300 for five packets of the MTA powder alone).

Another disadvantage, one of great concern if treating an anterior tooth, is that MTA (even white MTA) can result in tooth discoloration (Hutcheson *et al.*, 2012). This discoloration is amenable to internal bleaching (Table 11.1 and Figure 11.1).

Permanent tooth pulp capping

In the event of a small mechanical or traumatic exposure, the direct application of $\text{Ca}(\text{OH})_2$ on the nonbleeding pulp has proven to be very successful in young immature teeth (direct pulp cap or Cvek pulpotomy). Some believe that while using $\text{Ca}(\text{OH})_2$ for

Table 11.1 MTA system contents and ingredients (Pro Root MTA).

One MTA system contains	MTA ingredients
Five 1-g treatments of MTA material	Tricalcium silicate
Six water ampules	Tricalcium aluminate
Four carriers	Dicalcium silicate
Six mixing sticks	Calcium sulfate dihydrate
Ten dispensing sleeves	Bismuth oxide



Figure 11.1 Gray and white MTA by Proroot (always mixed on a glass slab) (contributed by Dr. Patrice Wunsch, VCU Department of Pediatric Dentistry).

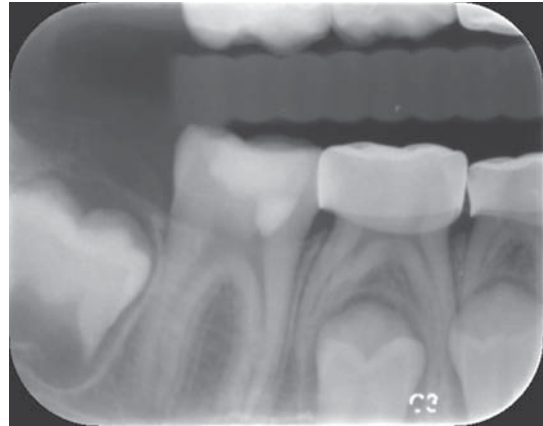


Figure 11.2 MTA direct pulp cap on tooth #30 (contributed by Dr. Claudia Colorado, VCU Department of Endodontics).

direct pulp capping is an option, over time, it washes out or disintegrates where MTA does not (Farsi *et al.*, 2006). Some now advocate the use of MTA for direct pulp capping over the use of $\text{Ca}(\text{OH})_2$ (Figure 11.2).

Permanent tooth pulpotomy

When the carious exposure is large, as discussed earlier, it is important to remove the infected, necrotic pulp by performing a pulpotomy. $\text{Ca}(\text{OH})_2$ has been used to preserve the apical vitality of a carious exposed pulp. But it has been shown that once root end closure has been obtained, the root canals would require obturation in order to prevent dystrophic calcification in the canals, a condition that would later prevent successful root canal therapy (Ranly & Garcia-Godoy, 2000).

It is important to recall the patient every 6 months and obtain a periapical radiograph on a yearly basis. Once root end closure has been obtained and the tooth remains clinically and radiographically within normal limits, it is then determined that nonsurgical root canal treatment is not indicated.

Some studies have shown that the control of pulpal bleeding plays a significant role in the success of the pulpotomy treatment. If a clot is allowed to form, this can result in treatment failure and thus irrigation is an important part of the treatment therapy. Use of either sterile saline or sodium hypochlorite is recommended. However, sodium hypochlorite has the added advantage of being able to provide hemostasis, disinfection and

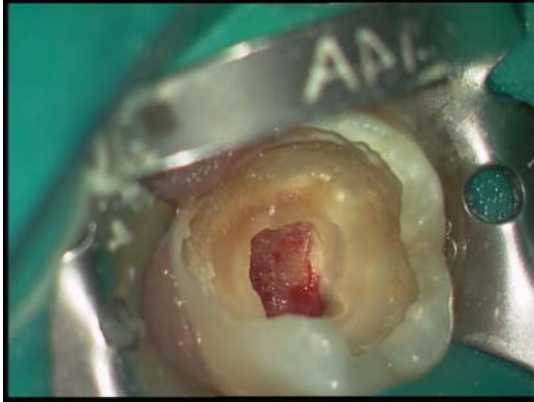

Figure 11.3 Healthy pulp tissue (contributed by Dr. Claudia Colorado, VCU Department of Endodontics).

removal of dentinal chips that remain after excavation (Farsi *et al.*, 2006)

If the pulp is not inflamed, it will not continue to bleed. At this point, MTA is placed onto the pulp. The setting ability of MTA is not affected by blood or water. In fact, it is recommended to place a damp cotton pellet over the MTA to enhance the setting process (Figure 11.3; El Meligy & Avery, 2006).

Indications for direct pulp therapy in young permanent molars

In the event of deep caries in a young permanent tooth that results in a carious exposure, the practitioner must consider the following:

- Patient behavior and level of cooperation
 - Is the patient able to cooperate for an endodontic procedure such as multiple visit apexification and root canal therapy?
 - If not, direct pulp therapy *may* be an option.
- Preoperative symptoms
 - Are the signs and symptoms consistent with a diagnosis of reversible pulpitis?
 - If so, direct pulp therapy *is* an option.
- Apical development of the tooth
 - Is the root wall thickness and root end closure complete (has the tooth completed development)?
 - If not, direct pulp therapy *is recommended* in a tooth with the signs and symptoms consistent with a diagnosis of reversible pulpitis in order to maintain the vitality of the tooth and allow continued development.

What is direct pulp therapy (DPT)?

Direct pulp therapy in teeth with deep carious lesions involves the removal of the carious insult as well as the most superficial pulp which may be characterized by inflammation and bacterial invasion (Horsted-Bindslev & Lovschi, 2002). What is left behind is deemed to be healthy pulp, capable of healing. Placement of $\text{Ca}(\text{OH})_2$ (not discussed in the treatment section of this chapter due to its being less successful than MTA) or MTA promotes the formation of a dentinal bridge between the pulp and the material. A sealed restoration will not allow for bacterial invasion and thus allows for the young healthy pulp to heal and for the young immature tooth to continue to mature and develop.

Diagnosis

As discussed in the Chapter 10, a comprehensive review of the patient's medical and dental history must be initially completed. The clinical examination includes an intraoral and extraoral examination of the hard and soft tissues associated with the area of the patient's chief complaint. Radiographic examination to include a bitewing radiograph and periapical radiograph are obtained to adequately assess the extent of caries in the dentin and the periradicular area of the tooth. The periapical radiograph is used to look for signs of periapical pathology. The tooth in question should have clinical tests such as percussion and palpation to assess for periapical pathology or mobility. Electric pulp testing and cold tests are unreliable in teeth with developing root structure (Camp, 2008). However, cold testing performed before the initiation of treatment can be used to provide a baseline from which one can monitor the vitality of the pulp after treatment.

Medicament

Mineral trioxide aggregate (MTA)

MTA is a powder consisting 75% Portland cement, 20% bismuth oxide and 5% gypsum. The major component (Portland cement) is responsible for the setting and biologic properties. Bismuth oxide provides radiopacity and gypsum is an important determinant of the setting time. The major components of Portland cement are

a mixture of dicalcium silicate, tricalcium silicate, tricalcium aluminate, and tetracalcium alluminoferrite. The tetracalcium alluminoferrite contributes to the dark color. Lower amounts of iron are present in white MTA compared to the gray MTA (Camilleri, 2008; Steffen & van Waes, 2009).

Working time is 5 min.

Setting time is 3–6 h.

Technique

As stated in an article by Hilton (2009), after a review of the literature on vital pulp therapy, the following are techniques that are recommended for treatment success:

- Teeth are isolated with a rubber dam
- After isolation, teeth can be cleaned and disinfected
- A sterile bur is used to initiate cavity preparation and pulp exposure is initiated as atraumatically as possible
- Hemorrhaging is controlled with sterile materials

MTA pulpotomy, steps to successful treatment:

1. Local anesthetic is administered and rubber dam placement is completed (Figure 11.4).
2. Removal of caries in the enamel and dentin is initiated with a 330, 245, or 557 in a high-speed handpiece with irrigation (sterile water preferred).
3. A sterile number 6 or 8 round bur in a slow-speed handpiece is used to remove the pulp in the pulp chamber. A spoon excavator can be used at this point

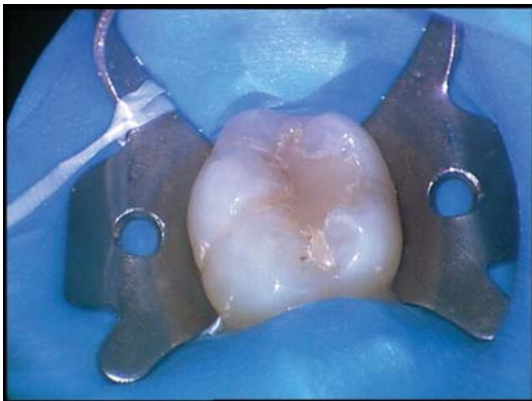

Figure 11.4 Rubber dam placement on tooth with defective restoration resulting in deep recurrent caries (contributed by Dr. Claudia Colorado, VCU Department of Endodontics).

to decrease the number of dentinal chips that can contaminate the pulp (Figure 11.5).

4. All carious dentin and the infected pulp are removed to the level of the radicular pulp (Figure 11.6).
5. Irrigation can be performed with sterile water or saline. Sodium hypochlorite can be used as well. The exposed pulp is irrigated with 2.5% Figure 11.7 sodium hypochlorite (Torabinejad & Walton, 2009). Once hemostasis is achieved, MTA is mixed according to the manufacturers guidelines.
6. MTA is mixed on a glass slab with a metal spatula. The MTA powder is mixed with sterile saline at a 3 : 1 powder/saline ratio (Figure 11.8).

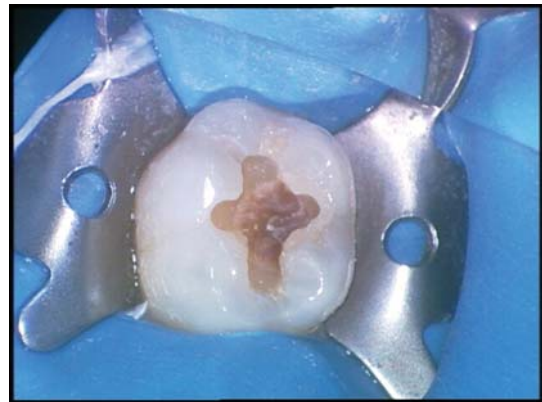


Figure 11.5 Caries excavation (contributed by Dr. Claudia Colorado, VCU Department of Endodontics).

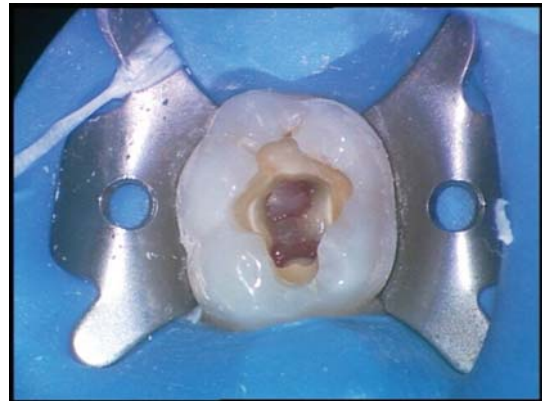

Figure 11.6 Carious dentin and infected pulp removed to level of the radicular pulp (contributed by Dr. Claudia Colorado, VCU Department of Endodontics).

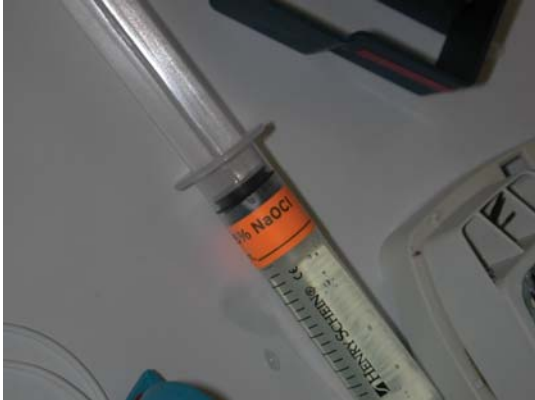

Figure 11.7 Irrigation with 2.5% sodium hypochlorite (contributed by Dr. Patrice Wunsch, VCU Department of Pediatric Dentistry).

7. The MTA is carried to the pulp stumps with a metal condenser where a one to two millimeter thickness of MTA is placed directed onto the pulp tissue (Figure 11.9). It is gently condensed with a moistened cotton pellet (Figure 11.10).
8. A moist cotton pellet is left over the MTA to enhance its set (moisture is necessary during the setting process). The MTA and cotton pellet are then covered with a glass ionomer temporary (intermediate restorative material (IRM) can be used as well).
9. It takes 3–6 h for the MTA to completely set. Therefore, the patient is rescheduled for the final restoration. The key to pulp survival after vital pulp therapy is a well-sealed restoration. Composites and amalgams can be sealed to prevent microleakage (Mertz-Fairhurst *et al.*, 1998). Full coverage crowns



Figure 11.9 Loading amalgam carrier with MTA (contributed by Dr. Patrice Wunsch, VCU Department of Pediatric Dentistry).

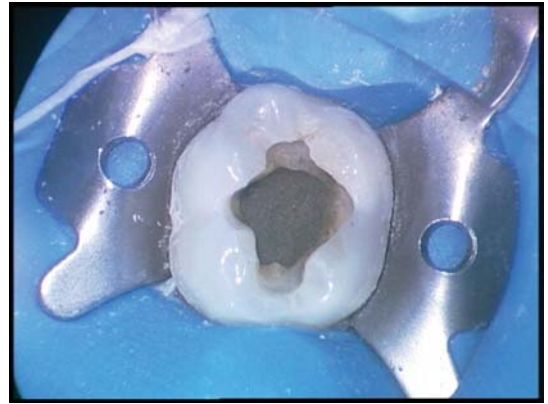


Figure 11.10 Condensing the MTA into place (contributed by Dr. Claudia Colorado, VCU Department of Endodontics).

are recommended if the tooth has enamel or dental defects or the tooth requires a restoration than involves more than two surfaces.



(a)



(b)

Figure 11.8 (a) MTA-to-saline ratio is 3 : 1 (contributed by Dr. Patrice Wunsch, VCU Department of Pediatric Dentistry). (b) MTA is mixed on a glass slab (contributed by Dr. Patrice Wunsch, VCU Department of Pediatric Dentistry).

Follow-up

The patient is rescheduled for a follow-up in 3 months when the treatment is examined both clinically and radiographically. If the treatment is successful, routine recalls are scheduled every 6 months with radiographs planned at 1-year intervals.

Complications

1. Root canal obliteration
 - a. If the tooth remains vital, this is considered normal, and there is no need for nonsurgical root canal treatment
2. Pulp necrosis
 - a. Nonsurgical root canal treatment needed
3. Lack of apexogenesis

Criteria for success

1. Vitality is preserved.
2. No pain, sensitivity, or swelling.
3. No radiographic evidence of internal or external resorption or other periradicular disease.
4. Continued apexogenesis (Rafter, 2005):
 - a. Sustain the viability of Hertwig's sheath, thus allowing for continued development of the root length ensuring a better crown to root ratio.
 - b. Maintain pulpal vitality thus allowing the remaining odontoblasts to lay down dentin which in turn produces a thicker root wall and less chance of root fracture.
 - c. Promote root end closure to allow for the natural apical constriction.
 - d. Generate a dentinal bridge at the site of the pulpotomy. Its presence indicates that the pulp has maintained its vitality.

Success rate

Success is higher for the MTA pulpotomy than the $\text{Ca}(\text{OH})_2$ pulpotomy. This can be due to the fact that MTA produces a thicker dentinal bridge, less inflammation, less hyperemia, and less pulpal necrosis compared

with $\text{Ca}(\text{OH})_2$ (Witherspoon *et al.*, 2006). MTA also provides a better seal against bacterial invasion.

References

- Camilleri, J. (2008) The chemical composition of mineral trioxide aggregate. *Journal of Conservative Dentistry*, **11** (4), 141–143.
- Camp, J. (2008) Diagnosis Dilemmas in Vital Pulp Therapy: Treatment for the Toothache Is Changing, Especially in Young, Immature Teeth. *Pediatric Dentistry*, **30** (3), 197–205.
- El Meligy, O.A.S. & Avery, D.R. (2006) Comparison of mineral trioxide aggregate and calcium hydroxide as pulpotomy agents in young permanent teeth (apexogenesis). *Pediatric Dentistry*, **28** (5), 399–404.
- Farsi, N., Alamoudi, N., Balto, K. & Al, M.A. (2006) Clinical assessment of mineral trioxide aggregate (MTA) as direct pulp capping in young permanent teeth. *The Journal of Pediatric Dentistry*, **31** (2), 72–76.
- Hilton, T.J. (2009) Keys to clinical success with pulp capping: a review of the literature. *Operative Dentistry*, **34** (5), 615–625.
- Horsted-Bindslev, P. & Lovschall, H. (2002) Treatment outcome of vital pulp treatment. *Endodontic Topics*, **2**, 24–34.
- Hutcheson, C., Seale, S., McWhorter, A., Kerins, C. & Wright, J. (2012) Multi-surface composite vs stainless steel crown restorations after mineral trioxide aggregate pulpotomy: a randomized controlled trial. *Pediatric Dentistry*, **34** (7), 460–467.
- Mejare, I. & Cvek, M. (1993) Partial pulpotomy in young permanent teeth with deep carious lesions. *Endodontics and Dental Traumatology*, **9**, 238–242.
- Mertz-Fairhurst, E., Curtis, J., Ergle, J., Rueggeberg, F. & Adair, S. (1998) Ultraconservative and Cariostatic Sealed Restorations: Results At Year 10. *Journal of the American Dental Association*, **129**, 55–66.
- Rafter, M. (2005) Apexification: a review. *Dental Traumatology*, **21**, 1–8.
- Ranly, D.M. & Garcia-Godoy, F. (2000) Current and potential pulp therapies for primary and young permanent teeth. *Journal of Dentistry*, **28**, 153–161.
- Steffen, R. & van Waas, H. (2009) Understanding mineral trioxide aggregate/Portland-cement: a review of literature and background factors. *European Archives of Paediatric Dentistry*, **10** (2), 93–97.
- Torabinejad, M. & Walton, R. (2009) Protecting the pulp, preserving the apex. In: *Endodontics*, 4th edn. Saunders Elsevier. Chapter 2, pp. 31–32.
- Ward, J. (2002) Vital pulp therapy in cariously exposed permanent teeth and its limitations. *Australian Endodontic Journal*, **28** (1), 29–37.
- Witherspoon, D.E., Small, J.C. & Harris, G.Z. (2006) Mineral trioxide aggregate pulpotomies. *Journal of the American Dental Association*, **137**, 610–618.

Diagnosis and treatment of molar–incisor hypomineralization

J. Timothy Wright

Introduction

Molar–incisor hypomineralization (MIH) is a developmental defect of the human dentition that primarily affects the enamel of the first permanent molars and can involve the incisors. Typically, the second permanent molars and premolars are not involved. This condition has been recognized since around 1970 and has been described using a variety of terms (e.g., cheese molars, idiopathic hypomineralization of enamel) (Weerheijm *et al.*, 2001a). The term MIH was accepted by leaders in the field that convened at the European Academy of Pediatric Dentistry in 2000, and this continues to be the name most used to describe this condition (Weerheijm *et al.*, 2001b). The clinical characteristics vary from case to case and between teeth in the same individual. The more severely affected the first permanent molars, the more likely it is that there will be incisor involvement. The defects vary from small well-demarcated areas of color change to extensive hypomineralization that includes the entire dental crown. Affected teeth form with a normal thickness of enamel and the abnormal areas of enamel having a decreased mineral content and increased protein and water content. Thus, the defects are not hypoplastic in that the full thickness of enamel develops. Once the tooth begins to erupt and come into function, rapid enamel loss can make the crowns appear hypoplastic, but this is typically the result of enamel fracturing, wear, and dental caries. Discoloration of the involved areas is a result of the

decreased mineral content and increased protein and water content that change the optical character of the hypomineralized enamel (Fagrell, 2011). The enamel color changes range from white opaque lesions to a creamy yellow or brown. The more severe the level of hypomineralization, the more likely the tooth is to have early loss of enamel. Early enamel loss is often associated with the development and progression of dental caries that can lead to rapid deterioration of the clinical crown (Figure 12.1) and pulpal involvement if left untreated. The degree of hypersensitivity associated with these defects varies but can be quite pronounced and appears to be frequently associated with the severity of hypomineralization and enamel loss. Hypersensitivity and difficulty anesthetizing the affected molars can add to the challenge of treating individuals with MIH (William *et al.*, 2006).

Prevalence and etiology

The prevalence of MIH ranges from about 3–40% in the population, making it relatively common and a condition that will challenge clinicians on a regular basis (Jalevik, 2010). The first permanent molar is the permanent tooth most likely to develop dental caries, and hypomineralized molars are at increased risk for developing dental caries. Caries development can obscure the presence of enamel hypomineralization that likely contributes to the carious involvement in at least some first permanent

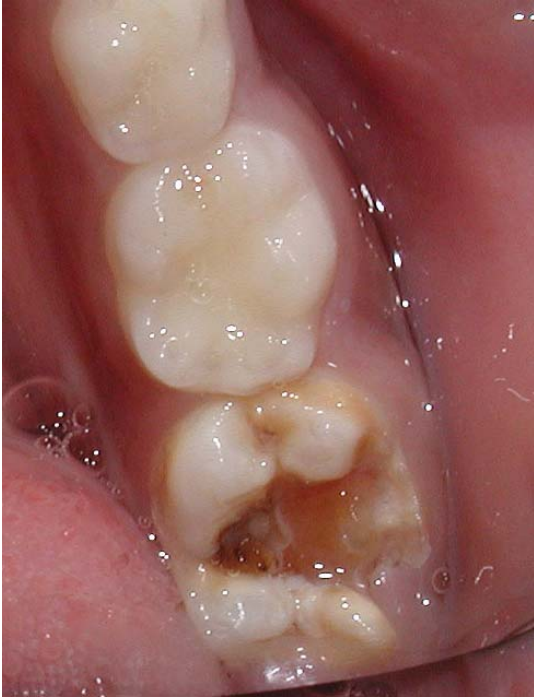

Figure 12.1 This mandibular first permanent molar shows the brown discoloration seen in severe MIH, and the subsequent loss of tooth structure and development of caries is readily evident.

molars. The first permanent molars begin to form *in utero* and typically start to mineralize just before or shortly after birth (first permanent molars of girls tend to form earlier than those of boys). The enamel of the permanent first molars and permanent incisors does not fully mineralize until the age of 3–5 years. Having enamel hypomineralization in the primary dentition increases the odds that the individual will have MIH in the permanent dentition (Elfrink *et al.*, 2012).

Attempts to identify the etiology of MIH have largely focused on categorizing environmental insults that might be associated with the condition. Maternal health, premature birth, infant health, use of antibiotics, and a number of other conditions have been associated with MIH in several studies (Whatling and Fearn, 2008; Laisi *et al.*, 2009; Alaluusua, 2010). Most of the associated environmental stressors associated with MIH appear to occur in the first year of life (Fagrell *et al.*, 2013). Although there were initially thought to be associations and possible toxins associated with breast

feeding (dioxins), subsequent studies do not support an association of MIH with breastfeeding (Laisi *et al.*, 2008).

Studies evaluating the environmental influences associated with MIH have not ruled out the potential contribution of hereditary factors as being potentially participating in the cause of MIH. Indeed one genetic locus has been associated with MIH, and there are families with a history of MIH in multiple generations and in multiple siblings (Kuhnisch *et al.*, 2013). These findings all suggest that there is at least some genetic component contributing to MIH. This appears entirely reasonable, given that we know enamel formation is highly regulated at the molecular level and involves the expression of thousands of genes (Jeremias *et al.*, 2013). Just as genetics contributes significantly to an individual's risk for developing dental caries, it is probable that multiple genetic variations are at play in defining one's risk for developing MIH and making them more susceptible to environmental insults.

Diagnosis of molar–incisor hypomineralization

Diagnosing MIH can be difficult, and clinicians may confuse MIH with other developmental defects of enamel such as fluorosis or amelogenesis imperfecta (a group of hereditary conditions that cause a variety of enamel defects). There are hundreds of environmental and genetic conditions that are known to affect enamel formation, and so making a definitive diagnosis can be challenging. The diagnosis of MIH can be further complicated if the tooth begins to decay as the tooth is erupting, thereby destroying the affected crown structure. It is, however, important to accurately diagnosis MIH so that the different approaches for managing the condition can be implemented to achieve optimal treatment outcomes. There often will not be family history of enamel defects such as can occur in cases of amelogenesis imperfecta. The hypomineralization defect is primarily limited to the first permanent molars and incisors, whereas most of the teeth of both the primary and permanent dentitions are involved in amelogenesis imperfecta. With fluorosis the primary dentition is typically not affected, but all the permanent teeth tend to be involved, and the enamel defects are more uniformly distributed than it appears with MIH

(e.g., all four first permanent molars and incisors will be similarly affected).

Clinical evaluation for the presence of MIH ideally involves examining the four first permanent molars and eight permanent incisors and is often best accomplished in an 8-year-old child (Weerheijm *et al.*, 2003). The examination should be performed when the teeth are clean and moist. They are examined for the presence of demarcated changes in enamel color and translucency (opacities) and areas of enamel loss that most often occur in the affected molars. A severity scale has been developed to classify MIH as mild, moderate, or severe at the tooth level, meaning that one tooth may be mild, and another tooth in the same patient may be severe, and seeing this amount of variability is a common occurrence (Table 12.1) (Mathu-Muju & Wright, 2006). Enamel color changes are caused by changes in the enamel composition (amount of mineral and protein) and structure. Enamel that is yellow brown tends to have less mineral compared to white opacities and is more likely to succumb to enamel loss. These yellow-brown areas tend to lack the shiny reflective surfaces of normal enamel and have a more ground glass and slightly rough appearance indicative of a decreased mineral content. Clinically assessing these characteristics is helpful in determining prognosis for an individual tooth and the likelihood that it will break down over time as a result of enamel loss. These clinical attributes are also helpful in selecting appropriate treatment approaches and optimizing therapeutic success.

Treatment approaches for molar–incisor hypomineralization

Treatment approaches for MIH will vary substantially depending on the level of severity of the defect. The treatment goals for molars are to prevent the tooth from developing dental caries, to help prevent or reduce enamel loss, to restore form and function when there is enamel loss, and to address esthetic issues (this issue is typically more important in the affected incisors and is discussed) (William *et al.*, 2006; Lygidakis *et al.*, 2010). For some moderately and most severely affected molars, another goal is to manage the hypersensitivity associated with the hypomineralized and lost enamel. Normally, enamel has excellent insulating properties and protects the tooth from chemical and thermal stresses. When the mineral content is reduced and the protein and water content is increased or the enamel is lost, the tooth often becomes easily stimulated, and the level of sensitivity can be quite severe. Treatment approaches thus tend to be predicated on the severity of the MIH and the presence or absence of dental sensitivity (Table 12.2).

Optimizing approaches directed at the prevention of dental caries for individuals with MIH should always be considered, as their caries risk is increased due to having defective enamel. Discussions related to dietary risk factors, fluoride exposure included toothpaste, and other fluoride sources such as topical fluoride applications (fluoride varnish or gel) should

Table 12.1 Severity score of teeth affected with MIH.

	Mild	Moderate	Severe
Crown appearance	Demarcated opacities in non-stress-bearing area of molar	Intact atypical restoration present	Posteruptive enamel breakdown present
Enamel loss	Isolated opacities	Occlusal/incisal third of teeth without initial posteruptive enamel breakdown	Posteruptive enamel breakdown on erupting tooth that can be rapid
Caries	No caries associated with affected enamel	Posteruptive enamel breakdown/caries limited to one or two surfaces without cuspal involvement	Often develop widespread caries associated with affected enamel
Sensitivity	Normal dental sensitivity	Usually normal dental sensitivity	Usually history of dental sensitivity
Esthetics	Usually not an issue	Parents often express concern	Parents typically concerned

Table 12.2 Management of molar–incisor hypomineralization.

	Mild	Moderate	Severe
Molars	Desensitizing toothpaste Fluoride varnish Sealants	Fluoride varnish Sealants Resin restorations	Glass ionomer coverage Interim resins Stainless steel crowns Extraction
Incisors	No Treatment Resin perfusion	Bleach/Seal Resin perfusion Microabrasion Resin restorations	Bleach/Seal Resin Perfusion Microabrasion Resin restorations Veneers

be considered. For milder levels of dental sensitivity, the use of toothpaste for sensitive teeth might be of some benefit, although there are no studies to verify their usefulness. Other treatments such as amorphous calcium phosphate–casein phosphopeptide have been suggested, but there is little evidence that they function with any greater effectiveness than fluoride toothpaste and are much more costly. The use of chlorhexidine rinses at the concentration sold in the United States (0.12%) is not effective for controlling caries and can cause significant staining and so are not recommended for caries management (Rethman *et al.*, 2011).

For mild MIH fissure sealants provide a valuable preventive measure. Sealant retention can be an issue in teeth with MIH because the enamel is inherently weakened and has an increased protein and water content. Studies on sealant retention in MIH-affected teeth have been limited in numbers of teeth studied but indicate that sealants can be successful; however, retention varies with the material and technique for placement. A number of approaches have been suggested to enhance the bonding to these defective enamel surfaces. Pretreatment of the pits and fissures with 5% sodium hypochlorite will help reduce the discoloration of the surface and remove proteins and organic material from within the enamel, helping create an intimate resin–enamel interface. Studies also indicate that the use of a bonding agent before sealant placement will improve retention. So we recommend the following protocol for sealant placement in teeth with MIH:

- isolate tooth to maintain a dry field;
- clean pits and fissures and any discolored tooth surface with pumice and rinse;
- apply 5% NaOCl for 60 s and rinse thoroughly;

- apply phosphoric acid etchant for 30 s, rinse, and dry;
- apply bonding agent and sealant to pits and fissures and treated discolored areas.

Bleaching of the affected enamel and perfusing it with resin can markedly improve the appearance of the enamel (Figure 12.2a–12.2c). Resins that perfuse into enamel are bonding agents, unfilled clear sealants, and the new resin systems designed specifically for treating noncavitated enamel decalcifications or hypomineralized areas. This same technique can be used to manage yellow-brown discolored areas on the anterior and has been called the bleach–etch–seal technique (BEST) (Wright, 2002). This can produce excellent esthetic results in some but not all cases depending on the extent, depth, and type of discoloration. White opacities will tend to remain white, although resin perfusion can markedly diminish this discoloration in some cases as well.

The technique outlined previously uses resin-based sealant systems that have been shown in numerous clinical studies to be highly effective in preventing caries (Gooch *et al.*, 2009). They are relatively technique sensitive to place and require the tooth be isolated. Glass ionomers (GIs) provide another option that can be used as a sealant and as discussed in the next section a restorative material. GIs provide an excellent option for partially erupted teeth, teeth with sensitivity to air, or difficult to isolate teeth, as they are moisture tolerant and can bond directly to the enamel and be placed without multiple and intermediate steps.

Teeth with moderate degrees of MIH will have more extensive areas of affected enamel, and there is a high likelihood that stress-bearing areas will eventually fracture with function over time. Thus, cuspal and marginal

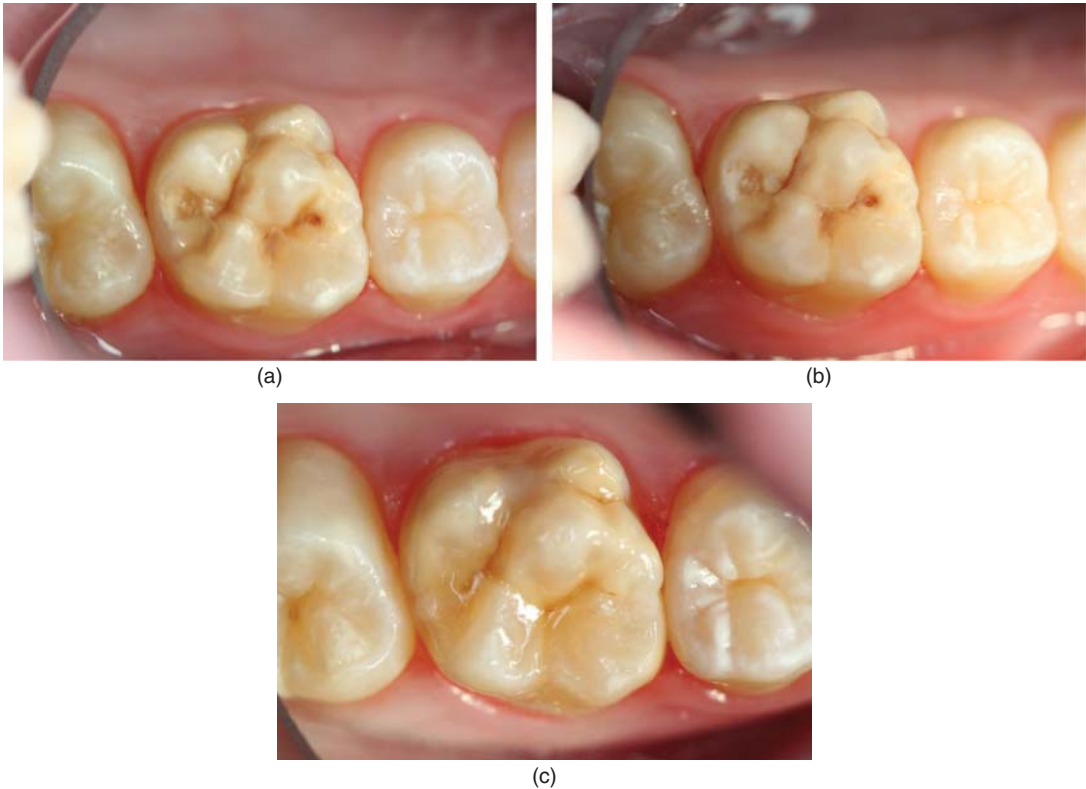


Figure 12.2 This maxillary first permanent molar has moderate MIH with some enamel loss already occurring in both the mesial and distal occlusal areas (12.2A). The tooth was cleaned and treated with 5% NaOCl, which shows the improved color change that can occur with this treatment (12.2B). The tooth was etched, bonding agent placed and polymerized, and then sealed with a white opaque sealant in the lingual area for improved esthetics and then coated entirely with a highly penetrating clear resin sealant (12.2C).

ridge enamel fractures are common in these teeth. If there is no enamel loss, then initial treatment should be placement of a resin or GI sealant that can help protect the enamel surface. If enamel fracturing occurs, then a filled resin or GI-type restoration can be placed to restore the normal tooth contours and help prevent caries from forming in uncleanable and exposed areas. Removal of the severely affected enamel areas to allow for a minimal bulk of material required for fracture resistance and to allow the restoration to extend to minimally or nonaffected enamel that is adjacent to the fractured area will improve restoration longevity. The technique for placement of resin restorations is the same as that outlined for resin sealant placement. Amalgam restorations also perform relatively well in the treatment of these teeth (Lygidakis *et al.*, 2010). If this nonadhesive approach is used, the restoration should not end on severely affected

areas of enamel that will be stress bearing, as they will likely fracture away from the amalgam.

Teeth with severe MIH are the most challenging to treat. The molars may be losing enamel and becoming cariously involved as they first begin to emerge into the oral cavity. Extreme sensitivity can accompany this clinical presentation. These teeth can often be treated using GI materials that can be placed with no tooth preparation or need for anesthetic. The tooth can be blotted dry with cotton, and either a chemical or light-cured or resin-modified GI placed (Figure 12.3). If the tooth is early in its course of eruption, then additional material will likely need to be placed at regular intervals until a more definitive restorative approach can be considered. Placement of these materials provides an effective barrier to thermal and chemical stimulation and can provide immediate relieve from sensitivity (Figure 12.2). Although these restorations

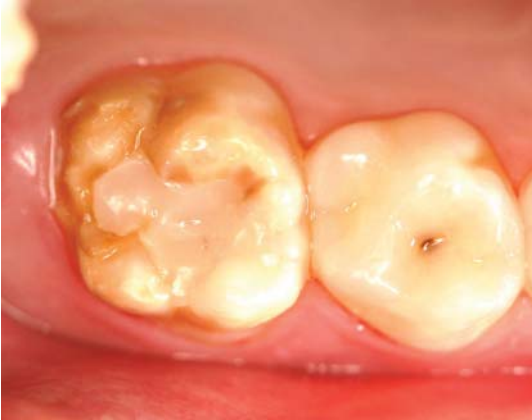

Figure 12.3 This maxillary first permanent molar caused extreme sensitivity with temperature changes and was treated using a protective resin-modified glass ionomer with no tooth preparation other than pumice prophylaxis and blotting the tooth dry. The margins show some deterioration at this 3-year follow-up, but the restoration remains intact with no development of caries or problems with sensitivity.

can serve as excellent protective treatments, they typically are not definitive, and when the tooth is fully erupted, additional or other treatment can be considered. In some cases, these types of treatments can last for years, allowing additional dentin formation, root apexification, and increased maturity of the patient.

If early treatment is not provided in teeth severely affected with MIH, then extensive destruction and caries development can result in pulp necrosis and

teeth requiring more extensive restorations. Many of the severely affected teeth will ultimately need to be restored with crowns. Clinical studies show that stainless steel crowns (SSCs) and cast crowns provide outstanding results with very few failures (Lygidakis *et al.*, 2010). For newly erupted teeth and even in young patients in their early teens, SSCs have many advantages over other types of crowns, as they require a minimal amount of tooth reduction for placement, are less expensive than cast crowns, and can be completed in one visit.

There are no long-term data on the outcomes of providing root canal therapy and crowns to teeth in young preadult patients. Although excellent results can be achieved using these techniques (Figure 12.4), the long-term prognosis for teeth treated in such a manner should be considered guarded until evidence indicates otherwise. Teeth with a poor or guarded prognosis should be considered as potential candidates for extraction. Individuals having multiple MIH-affected teeth, especially if they are severely affected, may benefit from extracting the first permanent molars. If this is performed when the patient is young and the second permanent molar has less than half of its root formation, then the 12-year molar will often move mesially and close much of the space left from extraction of the first permanent molar (Figure 12.5a and 12.5b). Before considering this option, it is optimal to obtain a panoramic radiograph and evaluate whether the second and/or third molars are present, the stage or tooth

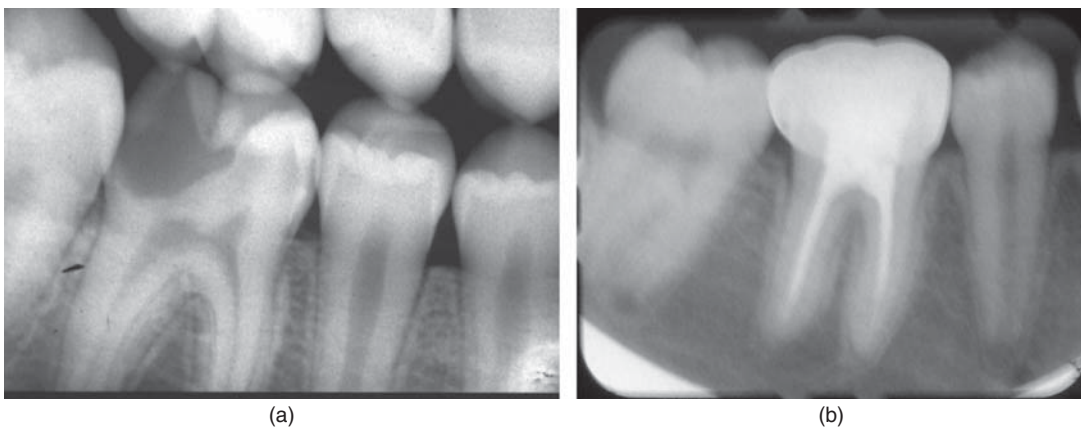


Figure 12.4 These radiographs show treatment of a mandibular first permanent molar with severe MIH and caries that was treated with root canal therapy and a SSC.

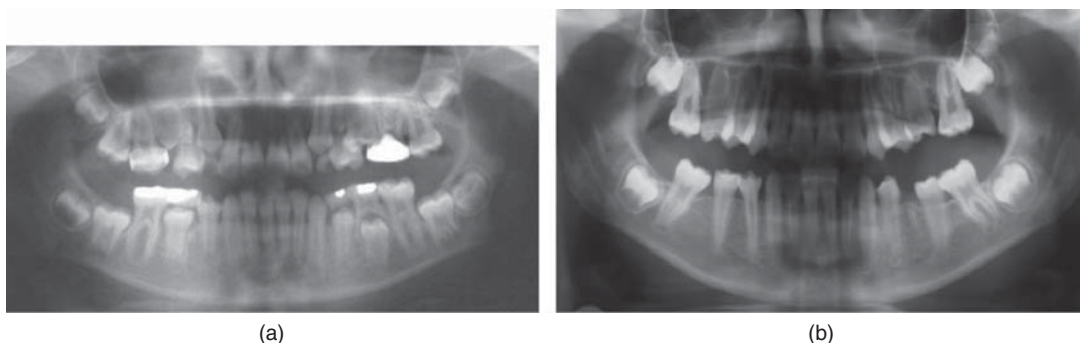


Figure 12.5 This child had three first permanent molars with severe MIH that had been restored and had marked crowding in the maxillary arch (12.5a). All four first permanent molars were extracted and the position of the 12-year molars and amount of space closure obtained by their eruption are seen before final orthodontic treatment (12.5b).

development, and have an orthodontic consultation. Some orthodontic tooth movement may be necessary to achieve optimal space closure, tooth inclination, and alignment.

Pain management can be challenging in patients with severe MIH, as the child associates all stimuli to these teeth with pain. Children with severe MIH are more likely to restorative or surgical interventions and are more likely than children not affected with MIH to have dental fear and exhibit behavior problems (Jalevik and Klingberg, 2002). Obtaining adequate anesthesia or sedation before using surgical approaches including restoration where tooth structure is removed is critical.

Summary

Clinicians are frequently faced with patients who require management of molars and incisors that have hypomineralized defects. Although a specific etiology remains to be established, it appears likely that these defects are the result of a combination of genetic predisposition and environmental insults. Managing patients with MIH requires a variety of patient management approaches, materials, and techniques. The dental hypersensitivity these patients experience and associate with their first permanent molars can make them extremely challenging to manage from a behavioral and anesthetic point of view. Having optimal caries prevention and reducing sensitivity as the teeth erupt using protective restorations and sealants can help reduce the need for more severe restorative approaches, help maintain pulp vitality, and will thus make patient

management from an anesthetic and behavioral aspect potentially less complicated. The materials we have to place protective and definitive restorations are excellent and can be applied using a variety of techniques to gain optimal therapeutic results. The timing of different treatment approaches, including extraction of the first permanent molars, can have a marked impact on the effectiveness of the treatment. By carefully diagnosing MIH and its severity and selectively applying different therapies, clinicians can achieve the goals of having patients with MIH who do not have hypersensitivity and who have a functional and esthetic dentition.

References

- Alaluusua, S. (2010) Aetiology of molar-incisor hypomineralization: a systematic review. *European Archives of Paediatric Dentistry*, **11**, 53–58.
- Elfrink, M.E., Ten Cate, J.M., Jaddoe, V.W., Hofman, A., Moll, H.A. & Veerkamp, J.S. (2012) Deciduous molar hypomineralization and molar incisor hypomineralization. *Journal of Dental Research*, **91**, 551–555.
- Fagrell, T. (2011) Molar incisor hypomineralization. Morphological and chemical aspects, onset and possible etiological factors. *Swedish Dental Journal. Supplement*, **5**, 11–83.
- Fagrell, T.G., Salmon, P., Melin, L. & Noren, J.G. (2013) Onset of molar incisor hypomineralization (MIH). *Swedish Dental Journal*, **37**, 61–70.
- Gooch, B.F., Griffin, S.O., Gray, S.K. *et al.* (2009) Preventing dental caries through school-based sealant programs: updated recommendations and reviews of evidence. *Journal of the American Dental Association*, **140**, 1356–1365.
- Jalevik, B. (2010) Prevalence and diagnosis of molar-incisor hypomineralisation (MIH): a systematic review. *European Archives of Paediatric Dentistry*, **11**, 59–64.

- Jalevik, B. & Klingberg, G.A. (2002) Dental treatment, dental fear and behaviour management problems in children with severe enamel hypomineralization of their permanent first molars. *International Journal of Paediatric Dentistry*, **12**, 24–32.
- Jeremias, F., Koruyucu, M., Kuchler, E.C. *et al.* (2013) Genes expressed in dental enamel development are associated with molar-incisor hypomineralization. *Archives of Oral Biology*, **58**, 1434–1442.
- Kuhnisch, J., Thiering, E., Heitmüller, D. *et al.* (2013) Genome-wide association study (GWAS) for molar-incisor hypomineralization (MIH). *Clinical Oral Investigations*, **18**, 677–682.
- Laisi, S., Ess, A., Sahlberg, C., Arvio, P., Lukinmaa, P.L. & Alaluusua, S. (2009) Amoxicillin may cause molar incisor hypomineralization. *Journal of Dental Research*, **88**, 132–136.
- Laisi, S., Kiviranta, H., Lukinmaa, P.L., Vartiainen, T. & Alaluusua, S. (2008) Molar-incisor-hypomineralisation and dioxins: new findings. *European Archives of Paediatric Dentistry*, **9**, 224–227.
- Lygidakis, N.A., Wong, F., Jalevik, B., Vierrou, A.M., Alaluusua, S. & Espelid, I. (2010) Best clinical practice guidance for clinicians dealing with children presenting with molar-incisor-hypomineralisation (MIH): an EAPD policy document. *European Archives of Paediatric Dentistry*, **11**, 75–81.
- Mathu-Muju, K. & Wright, J.T. (2006) Diagnosis and treatment of molar incisor hypomineralization. *Compendium of Continuing Education in Dentistry*, **27**, 604–610.; quiz 611
- Rethman, M.P., Beltran-Aguilar, E.D., Billings, R.J. *et al.* (2011) Nonfluoride caries-preventive agents: executive summary of evidence-based clinical recommendations. *Journal of the American Dental Association*, **142**, 1065–1071.
- Weerheijm, K.L., Duggal, M., Mejare, I. *et al.* (2003) Judgement criteria for molar incisor hypomineralisation (MIH) in epidemiologic studies: a summary of the European meeting on MIH held in Athens, 2003. *European Journal of Paediatric Dentistry*, **4**, 110–113.
- Weerheijm, K.L., Groen, H.J., Beentjes, V.E. & Poorterman, J.H. (2001a) Prevalence of cheese molars in eleven-year-old Dutch children. *ASDC Journal of Dentistry for Children*, **68** (259–62), 229.
- Weerheijm, K.L., Jalevik, B. & Alaluusua, S. (2001b) Molar-incisor hypomineralisation. *Caries Research*, **35**, 390–391.
- Whatling, R. & Fearn, J.M. (2008) Molar incisor hypomineralization: a study of aetiological factors in a group of UK children. *International Journal of Paediatric Dentistry*, **18**, 155–162.
- William, V., Messer, L.B. & Burrow, M.F. (2006) Molar incisor hypomineralization: review and recommendations for clinical management. *Pediatric Dentistry*, **28**, 224–232.
- Wright, J.T. (2002) The etch-bleach-seal technique for managing stained enamel defects in young permanent incisors. *Pediatric Dentistry*, **24**, 249–252.

Ectopic eruption of maxillary first permanent molar

Ari Kupietzky and Jane A. Soxman

Introduction

A smooth transition from the primary to the permanent dentition is of utmost importance in managing a pediatric dental patient. Ectopic eruption (EE) of the maxillary first permanent molar is a common occurrence in the developing mixed dentition and is many times diagnosed first by the pediatric dentist.

EE is defined as a tooth erupting in an abnormal position or orientation (Gehm & Crespi, 1997). EE of the first permanent molar is a local disturbance characterized by eruption of the molar under the distal undercut of the second primary molar and its failure to erupt to the normal occlusal plane (Chintakanon & Boonpinon, 1998). The first permanent molar may become impacted and cease to erupt, causing premature resorption of the distobuccal root of the neighboring primary molar (Figures 13.1 and 13.2). Early correction of ectopically erupting maxillary first permanent molars is an integral part of interceptive orthodontics and is crucial for the proper development of a stable occlusion. If left untreated, EE may cause serious sequelae, including early loss of the second primary molar, space loss, and impaction of second premolars (Figure 13.3a). Future corrective treatment may be complicated, lengthy, costly, and may include the distalizing and

uprighting of the permanent molar by use of headgear and fixed or removable appliances with subsequent long-term space maintenance (Figure 13.3b, 13.3c, and 13.3d).

Treatment of EE includes a broad spectrum of procedures, including observation with follow-up, elastomer separation, disking the distal of the adjacent second primary molar, the distal brass wire separation, fixed or removable appliance therapy, or extraction of the second primary molar and subsequent space regaining followed by space maintenance.

Treatment modalities may be divided into two categories: interproximal wedging and distal tipping. The former type of treatment has traditionally been used in cases of minimal to intermediate impaction of the first permanent molar on the distal aspect of the second primary molar. When the impactions are severe, distal tipping techniques with or without second primary molar extraction have been indicated. Distal tipping techniques use fixed or removable appliances (examples include Humphrey appliance, sectioned wire with open coil spring, slingshot type appliances, hemisection of adjacent primary tooth, and others).

This chapter presents step-by-step procedures for treatment of EE with separators and a brief description of more complicated treatment modalities.

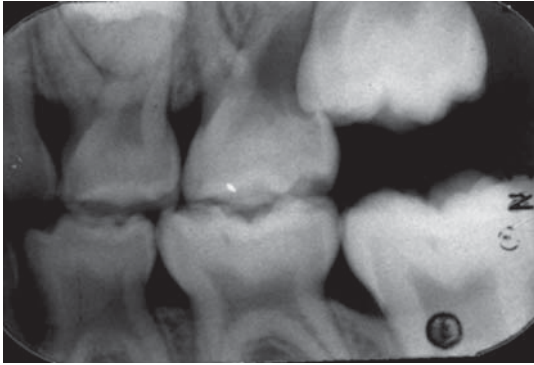


Figure 13.1 The first permanent molar may become impacted and cease to erupt, causing premature resorption of the neighboring primary molar as seen in routine bitewing radiograph.

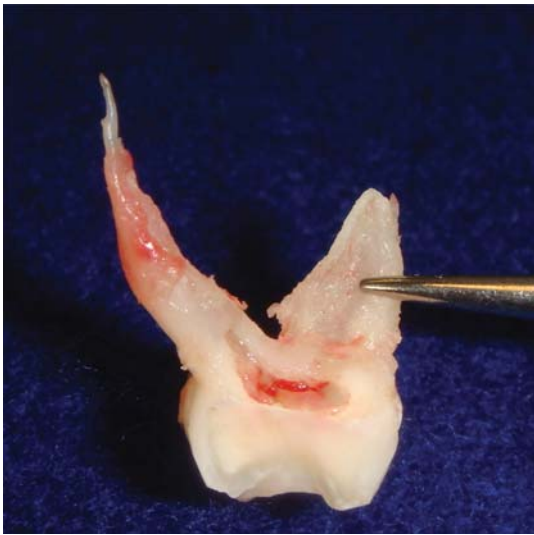


Figure 13.2 Extracted second primary molar with distobuccal root resorption.

Identification

EE of the maxillary first permanent molar usually presents between the ages of 5 and 7 years on radiographic examination. The position of the

unerupted first permanent molars on bitewing radiographs should be noted and documented in the patient's chart, for example, first permanent molar in good position or not visualized (Figure 13.4).

Observation

In many cases other than severe impaction, a conservative approach is suggested. Spontaneous correction occurs in 69.4% of cases and 14.3% progress to pulpal exposure of primary molar (Figure 13.5) (Barberia-Leache *et al.*, 2005). The parent/guardian and child are advised to notify for discomfort, sinus tract and/or mobility of the second primary molar during the observation period (Figure 13.6).

Elastomer separators

The simplest method for correction uses a sequence of elastic separators. The technique can be used to resolve many of these impactions efficiently and effectively, with minimal patient discomfort (Cerny, 2003).

Conventional elastomeric ring separators come in two sizes: green – 3 mm diameter, 0.75 mm thick; blue – 4 mm diameter, 1 mm thick (Figure 13.7). These sizes are easy to fit and effective at moving teeth apart as much as 1 mm. However, in more severe impactions, a larger and thicker elastomer has been suggested (Cerny, 2003).

Separators may be placed using separator pliers or floss (Figure 13.8a, 13.8b, 13.8c, 13.8d, and 13.8e).

When used in sequence with the smaller orthodontic separators, “jumbo separators”: 6 mm diameter × 2 mm thick can move teeth apart as much as 2 mm, which is often enough to free many partially impacted molars (Figure 13.9a, 13.9b, 13.9c, 13.9d, 13.9e, and 13.9f). The jumbo separators should be soaked in hot water for 2–3 min before fitting. This makes them more pliable and less susceptible to fracture. Care should be taken not to overstretch the separator while attempting to place it between the two teeth. Stretching the separator

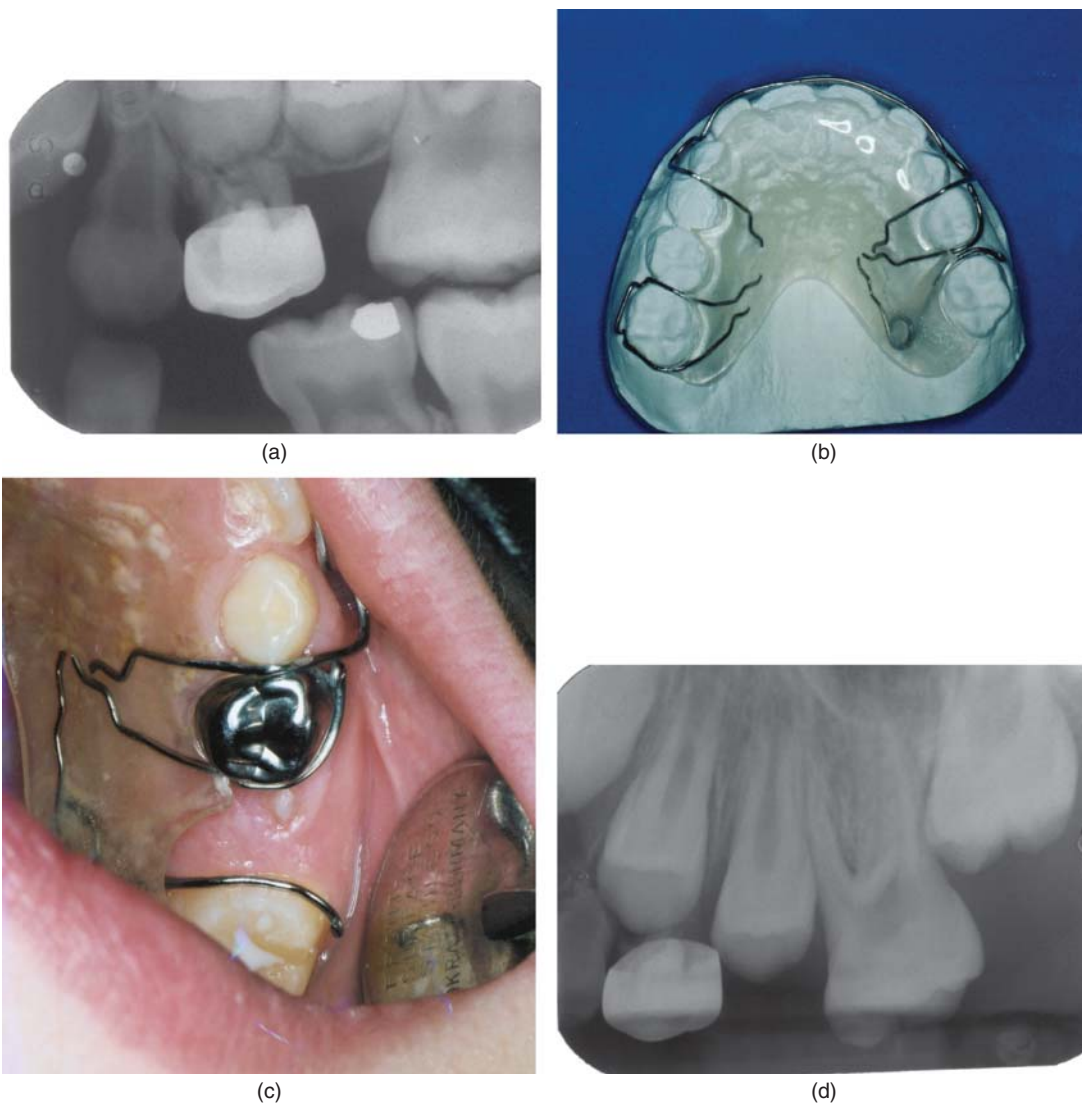


Figure 13.3 (a) If left untreated, EE may cause serious sequelae, including early loss of the second primary molar, space loss, and impaction of second premolars. (b) A removable appliance is used to distalize the permanent first molar and allow proper eruption of the second premolar. (c) Space has been regained allowing eruption of the blocked out tooth. (d) The periapical radiograph demonstrates eruption of the second premolar.

by no more than one-third of its diameter allows easy placement, with little distortion and deactivation. Patients should be instructed to continue routine tooth brushing but not to floss or use toothpicks around the separators.

The brass wire technique

The brass wire technique is a fairly simple procedure and can be used successfully in moderately and occasionally even in severely impacted molar cases. The technique was first described by Levitas (1964) over 50 years ago.

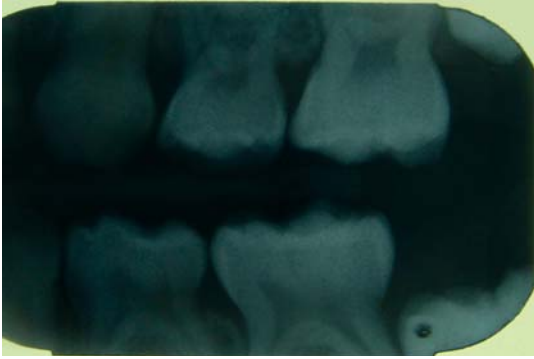


Figure 13.4 Bitewing radiograph of unerupted maxillary left first permanent molar in good position.




Figure 13.7 Elastomers of variable sizes: green (standard) – 3 mm diameter, 0.75 mm thick; blue (standard) – 4 mm diameter, 1 mm thick; black (jumbo) – 6 mm diameter, 2 mm thick. (reprinted with permission from Cerny (2003))

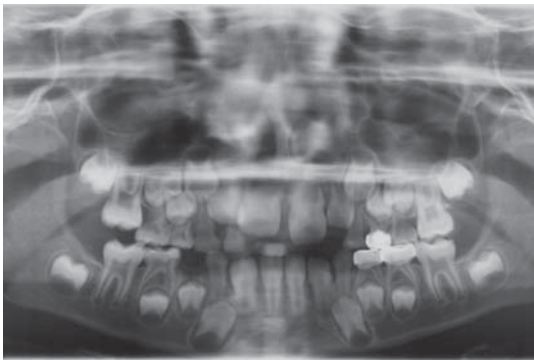
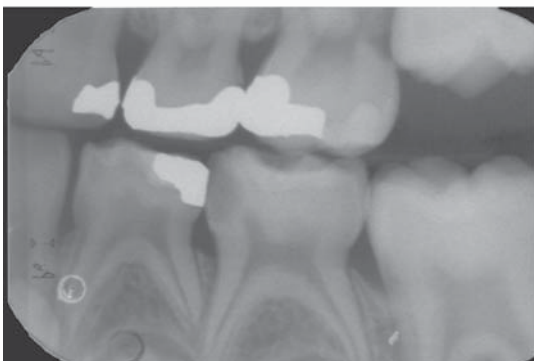
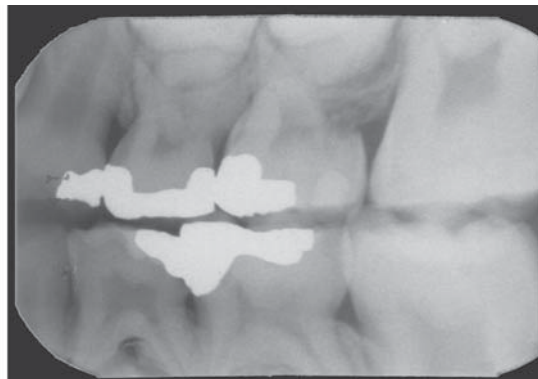


Figure 13.5 Panoramic radiograph showing impaction of maxillary right first permanent molar and spontaneous correction of ectopic maxillary left first permanent molar.

1. A bitewing radiograph should be taken before placement of the brass wire to determine the position of the marginal ridge and interproximal contact area of the molars (Figures 13.10a and 13.11a).
2. Local anesthesia may be required dependent on the severity of the impaction and the temperament of the patient. It may include infiltration of the buccal and palatal papillae.
3. A brass wire is placed between the contact area of the impacted first permanent molar and the adjacent primary molar with the use of a Mathieu plier or mosquito needle holder. Placement is from the



(a)



(b)

Figure 13.6 In many cases other than severe impaction, a conservative approach is suggested. (a) The unerupted maxillary first permanent molar in the bitewing radiograph was followed. (b) The molar erupted 6 months later without intervention.

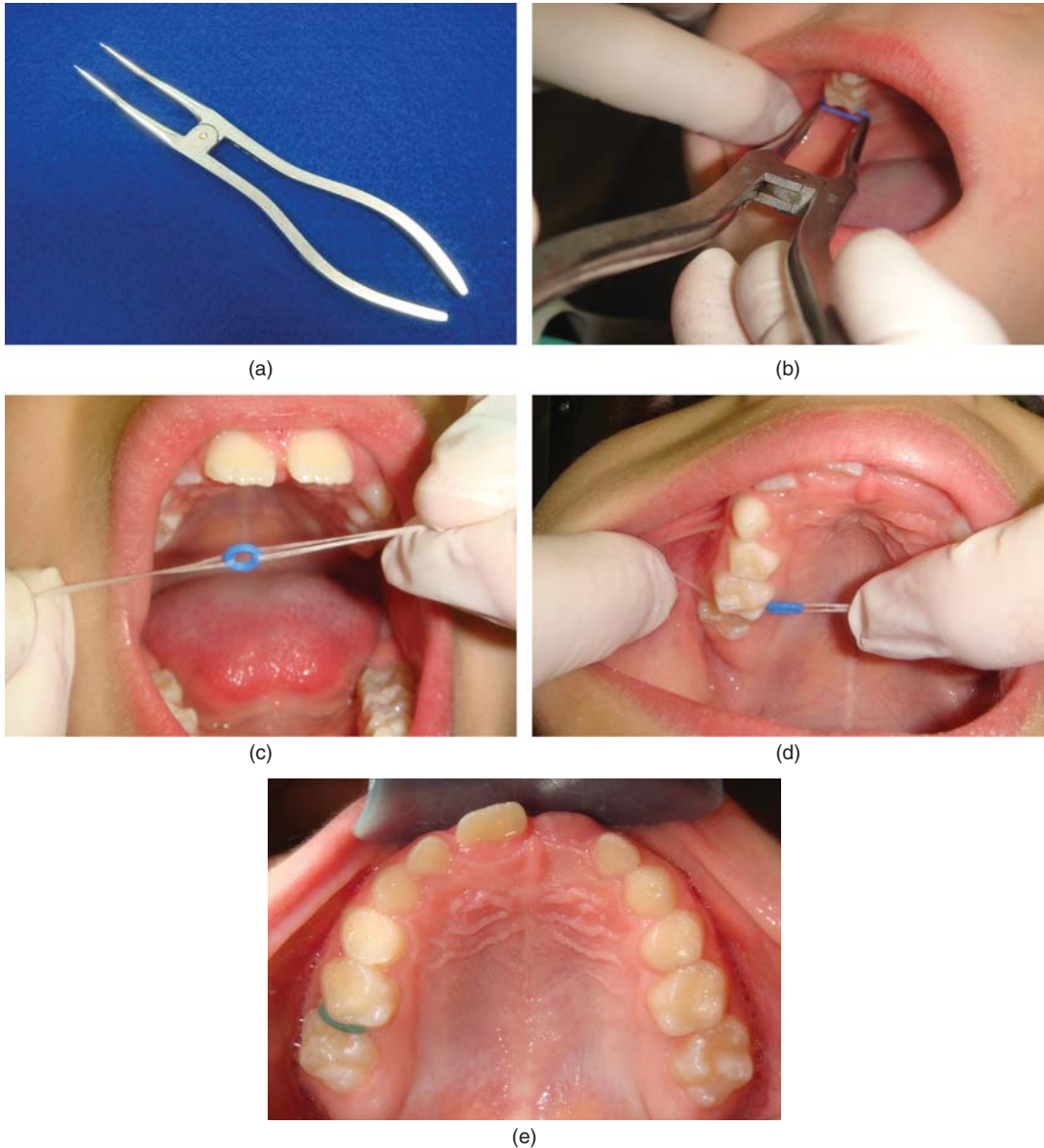


Figure 13.8 (a) Separator plier. (b) Placing elastomer with separator plier. (c) Elastomer with floss. (d) Placing elastomer with floss. (e) Deimpacted maxillary first permanent molar.

palatal tissue distal to the primary molar out toward the buccal. The brass wire can be purchased as single preformed loops (0.020 or 0.025, Ortho Organizers, Inc., San Marcos, CA, USA) or can be prepared from a coil of wire (Malin Co., Brookpart, OH, USA) by flattening out one end with a Howe utility plier. The flat end facilitates insertion from palatal to

buccal (Figure 13.12). Leave extra extension for twisting.

4. The other end of the wire is then bent over the marginal ridge area and twisted with the buccal end. The wire is tightened until snug. The excess wire is cut, and the twisted end is tucked into the proximal area to minimize irritation of the buccal mucosa.

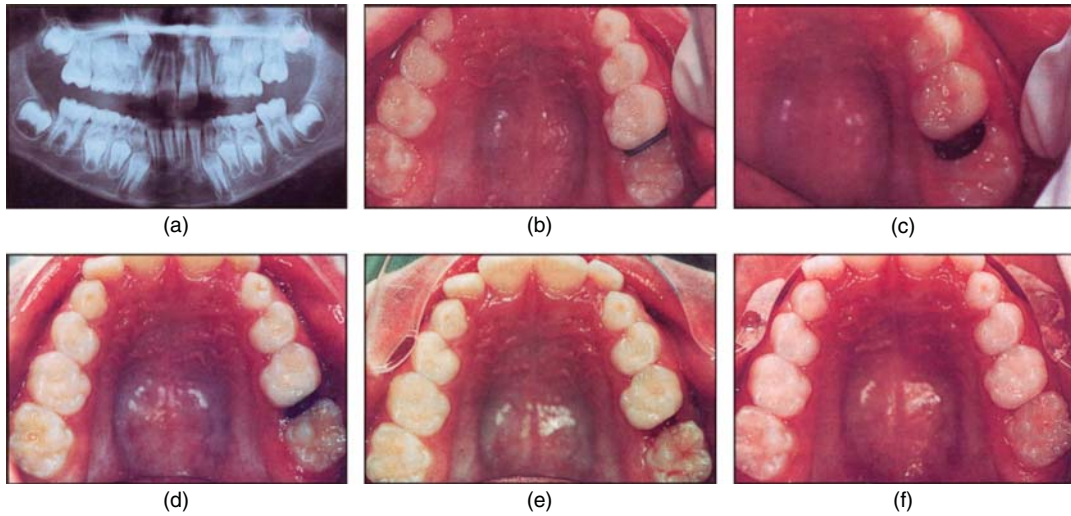


Figure 13.9 Nine-year-old female patient with partially impacted upper left first molar (a). Placement of blue separator (b). Placement of jumbo separator 1 week later (c). Jumbo separator 2 months later (d). After removal of jumbo separator (e). Six weeks after separation (f). (reprinted with permission from Cerny (2003))

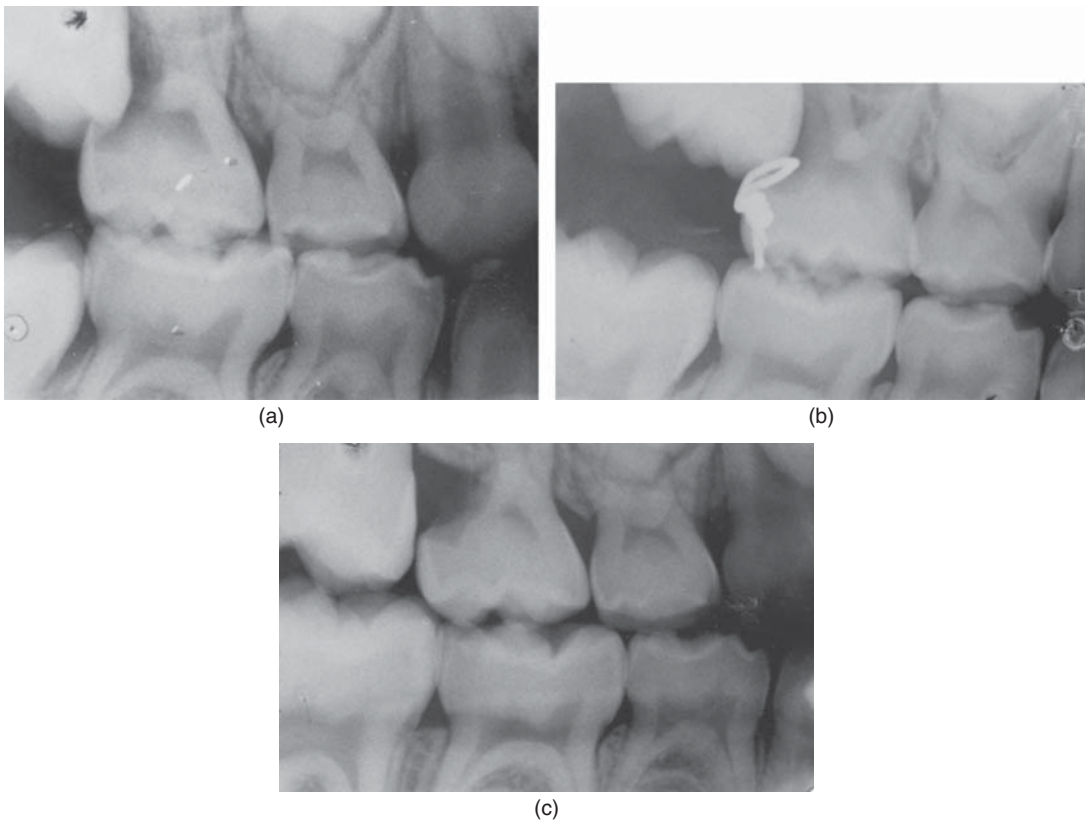


Figure 13.10 (a) Right bitewing radiograph taken at pretreatment. (b) Radiograph taken at placement of brass wire. Note, thickness of 0.020 wire, compared to 0.028 wire in Figure 13.11. (c) Radiograph taken at 3 months after removal of brass wire.

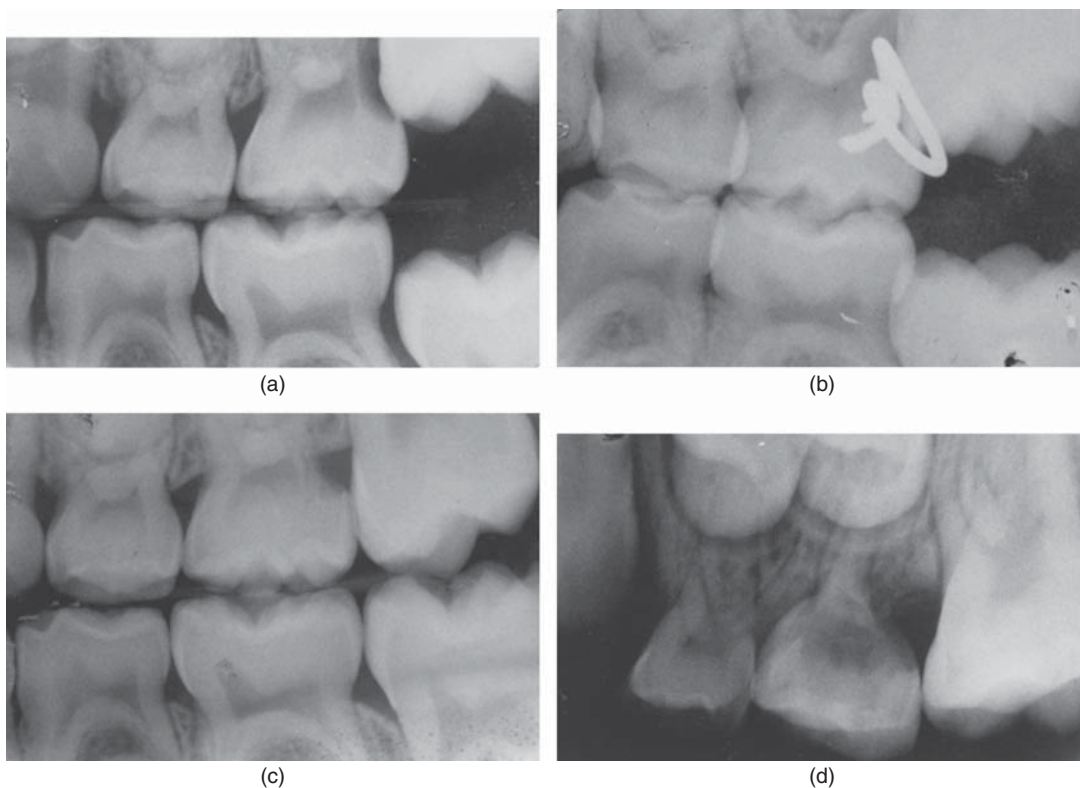


Figure 13.11 (a) Left bitewing radiograph taken at pretreatment. (b) Radiograph taken at placement of brass wire. Note, thickness of 0.028 wire, relative to 0.020 wire (in Figure 13.10). (c) Radiograph taken at 3 months after removal of brass wire. (d) Periapical radiograph taken 6 months after treatment. No symptoms were present. Primary second molar was stable and functioning well as a “space maintainer.”

The clinician should standardize the direction of the twist for future tightening without unraveling (Figure 13.13).

5. The separator must encircle the area of contact. Its prolonged activation acts to separate the contacting molars. A bitewing radiograph should be taken after wire placement to confirm its correct position, especially in moderate-to-severe impaction cases (Figures 13.10b and 13.11b).
6. An initial attempt should be made to place a 0.028-in. wire. If unsuccessful, a thinner wire (0.020) may be used with its replacement with the thicker wire at a future visit. If unsuccessful, two other wedging techniques may be attempted. One method uses metal separators of various diameters (Hirayama & Chow, 1992; Kim & Park, 2005), the other uses a clinical aid consisting of a catheter to place the wire interproximally (Huang & Childers, 1995).

7. The patient should be seen at 3–4-week intervals for wire tightening. Careful supervision is important. The wire may induce infection and early loss of the primary molar. However, proper oral hygiene is adequate in most cases to prevent any inflammation or infection.
8. Tightening of the wire is tolerated by most patients, but some may complain of mild pain and discomfort. Pediatric patient management techniques should be used. Many orthodontists refer these cases to the pediatric dentist because of difficulty in managing young children through these types of procedures.
9. The wire may be removed when the permanent molar is deimpacted and will actually slip through the contact area during routine activation. A bitewing (Figures 13.10c and 13.11c) and periapical radiograph (Figure 13.11d) may be taken to assess the stability of the primary molar and its ability to

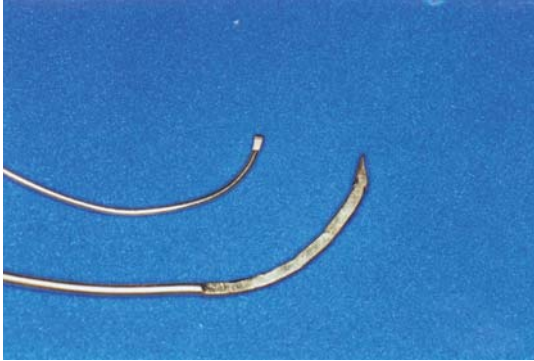

Figure 13.12 Close-up view of brass wire. The brass wire can be purchased as a single preformed loop (0.020 or 0.025 thickness, Ortho Organizers, Inc., San Marcos, CA, USA) or can be prepared from a coil (0.028, Malin Co., Brookpart, OH, USA) of wire by flattening out one end with a Howe utility plier. The flat end facilitates insertion from palatal to buccal. Leave extra extension for twisting. Two thicknesses are shown (0.020 and 0.028).

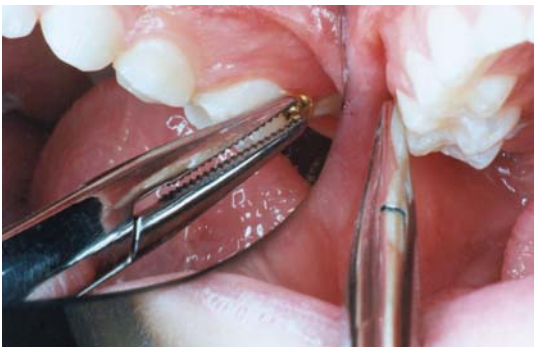

Figure 13.13 The clinician should standardize the direction of the twist of the brass wire for future tightening without unraveling.

act as space maintainer. The patient should be seen 3 months later to assess the primary molar. Primary molars may function for many years, although they sustained severe root resorption and even coronal resorption without any symptoms. In the event that the second primary molar is lost prematurely due to mobility or infection, space can be maintained with a simple band and loop appliance. Figures 13.14 and 13.15 present treatment and post-treatment clinical views of the radiographs in Figures 13.10 and 13.11.

Disking of the adjacent maxillary second primary molar

A wooden wedge is placed on the distal of the adjacent second primary molar, and a 169-L carbide bur in high speed is used to disk the distal of the second primary molar. Infiltration with a small amount of local anesthesia may be necessary. This procedure will not result in caries or sensitivity but may deimpact the maxillary first permanent molar (Figure 13.16a, 13.16b, 13.16c, and 13.16d).

Distal tipping techniques

When the degree of impaction or inaccessibility of the first permanent molar prevents separation, active appliance therapy is indicated to disimpact the tooth. In extreme situations, the second primary molar may be extracted, and following eruption of the permanent molar, space regaining and distalization are mandated followed by space maintenance until eruption of the second premolar (Figure 13.3).

Appliances may be of either the fixed segmental type or a removable acrylic appliance. The former usually consists of a band cemented to the second primary molar with an active spring soldered to the band engaging the occlusal surface of the permanent molar or bonded button attached to the tooth. The Halterman appliance (Halterman, 1982) consists of a reverse band and loop incorporating a distal spur. A chain elastic is placed from the spur to a bonded button on the ectopically erupting permanent molar (Figure 13.17).

In cases of extreme mobility of the primary second molar, the appliance may extend to the contra lateral side for proper anchorage (Figure 13.18). An alternative unilateral application consists of a modified Halterman appliance consisting of a bonded acrylic appliance to both the first and second primary molars, affording more stability and fixation of the second primary molar (Figure 13.19).

The ectopic spring-loaded distalizer (QC Orthodontic Lab, Inc.) offers another choice for appliance use (Figure 13.20a and 13.20b). This appliance requires good cooperation. The extension wrapping around the distobuccal cusp must be secured with flowable composite before cutting the elastic chain. After the elastic chain is removed, the distalizing spring activates

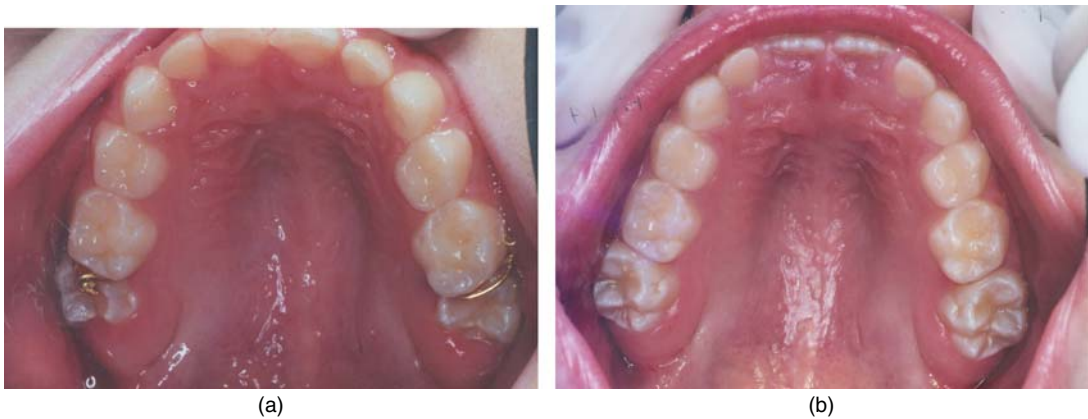

Figure 13.14 Occlusal view of 6-year-old patient shown in Figures 13.10 and 13.11 demonstrating bilateral ectopically erupting first permanent. Brass wire placement is shown. On the patient's right side, a 0.020 wire was placed (Malin Co., Brookpart, OH, USA). On the left side, a 0.028 preformed wire was used (Ortho Organizers, Inc., San Marcos, CA, USA) after attempts to place the thicker wire failed. At a later visit, the wire was replaced with the 0.028 wire.

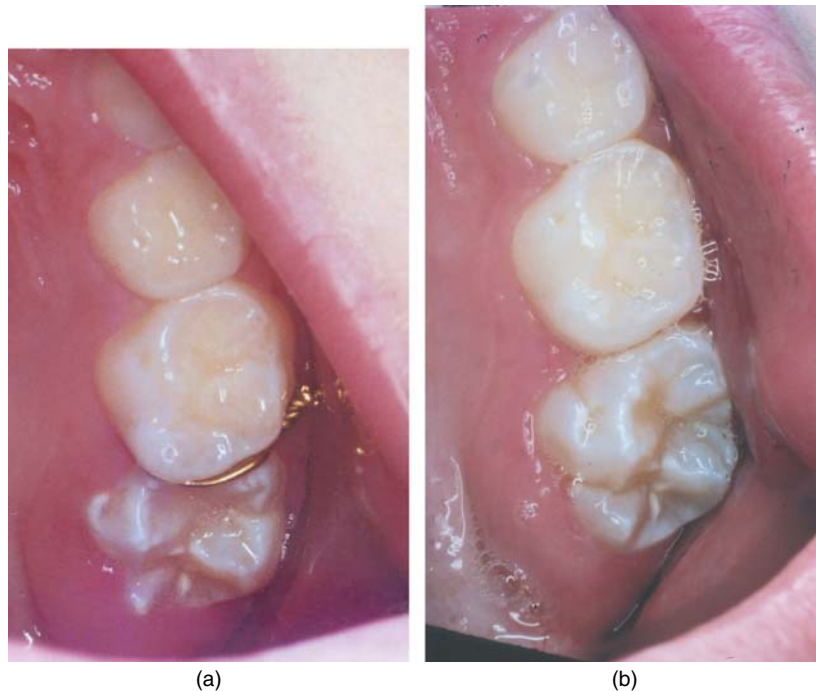


Figure 13.15 The brass wire is placed between the contact area of the impacted first permanent molar and the adjacent primary molar with the use of a Mathieu plier or Mosquito needle holder. Placement is from the palatal tissue distal to the primary molar out toward the buccal. (a) Occlusal view before treatment. (b) Occlusal view after treatment.

(Figure 13.20a, 13.20b, 13.20c, 13.20d, 13.20e, 13.20f, 13.20g, 13.20h, 13.20i, and 13.20j).

Removable appliances may also be used to distalize an ectopically erupting first permanent molar

(Figure 13.21). The removable appliance is designed with typical retention clasps and a palatal finger spring, which reaches the occlusal table of the blocked molar. An acrylic button is attached to the distal end of the

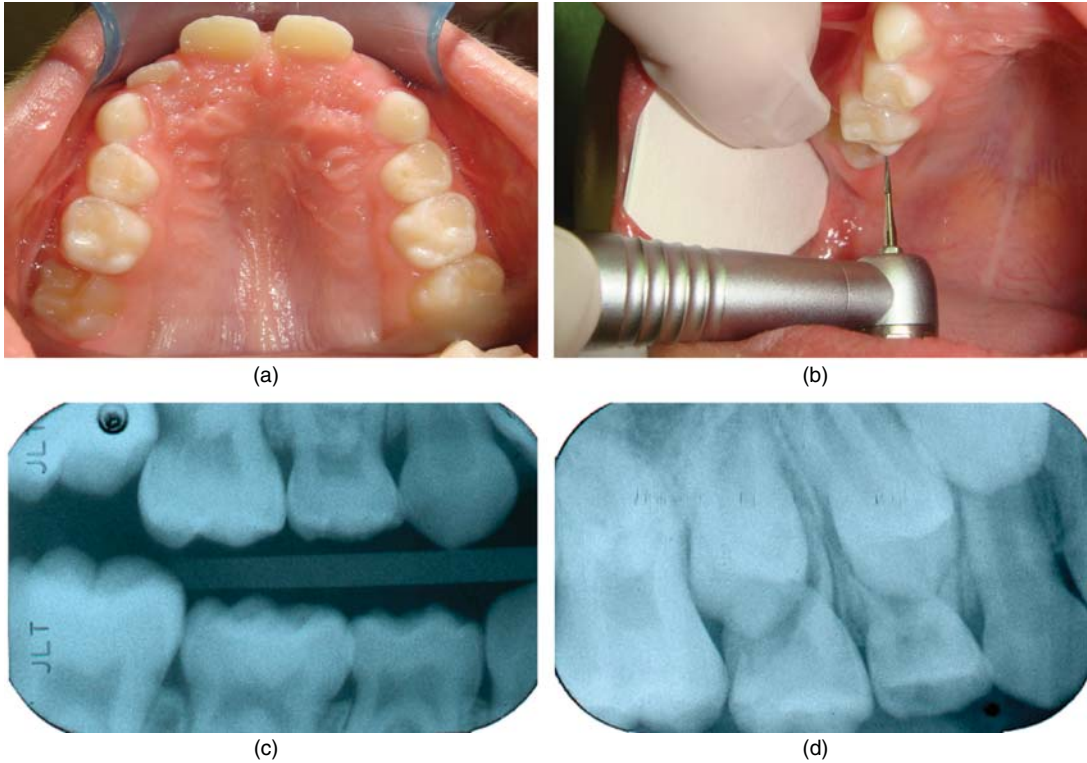


Figure 13.16 (a) Maxillary right first permanent molar ectopic eruption. (b) 169-L bur to disk the distal of the maxillary second primary molar. (c) Periapical radiograph with ectopic eruption of maxillary right first permanent molar before disking distal of maxillary right second primary molar. (d) Correction of ectopic eruption of maxillary right first permanent molar after disking distal of maxillary right second primary molar.

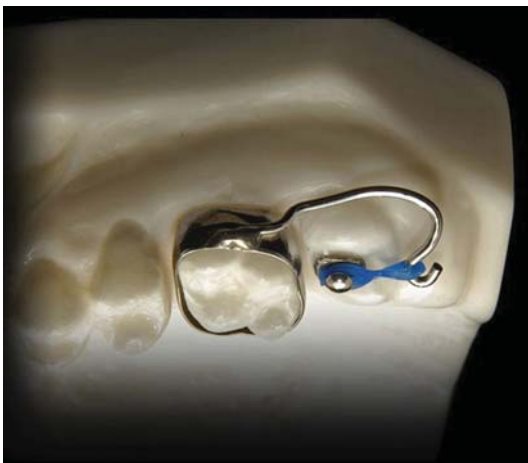

Figure 13.17 Halterman appliance.

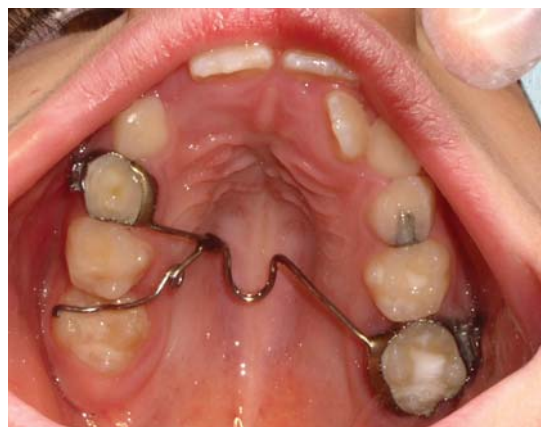

Figure 13.18 In cases of extreme mobility of the primary second molar, the appliance may extend to the contra lateral side for proper anchorage.

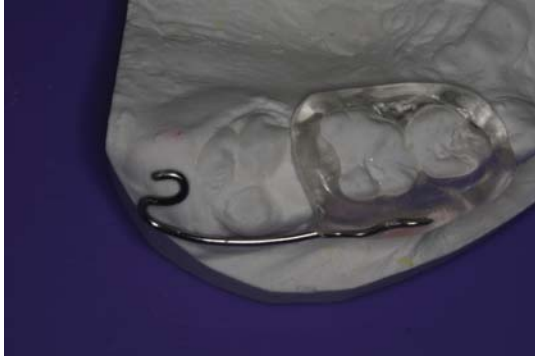
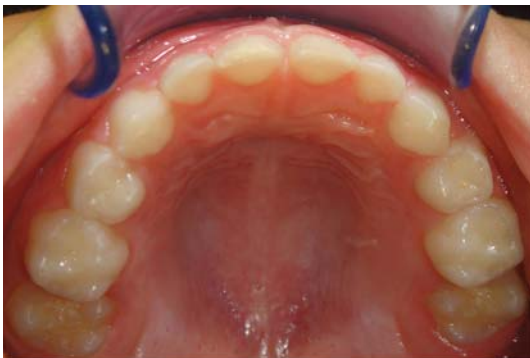
Figure 13.19 A modified Halterman appliance consisting of a bonded acrylic appliance to both the first and second primary molars affords more stability and fixation of the second primary molar. A button is bonded onto the occlusal table of the permanent molar and a chain is attached.

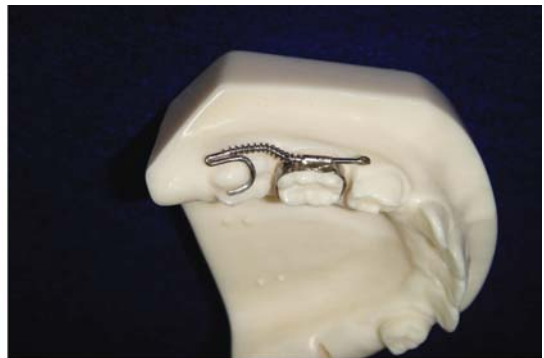spring and contacts the occlusal surface of the molar. Other methods include either bonding a button or a composite extension to the molar to engage the activated spring.

Space control

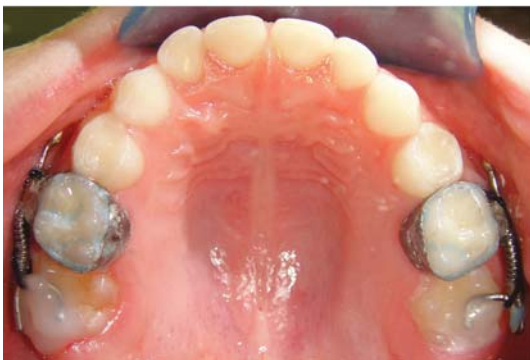With EE, space control is a more appropriate term than space maintenance, as unavoidable space loss will occur in almost every case due to the mesial eruption path of the maxillary first permanent molar. If the maxillary second primary molar is prematurely lost before full eruption of the maxillary first permanent molar, the appliance of choice is the band and loop. The first primary molar is banded, and the loop extends distally to the mesial of the partially erupted first permanent



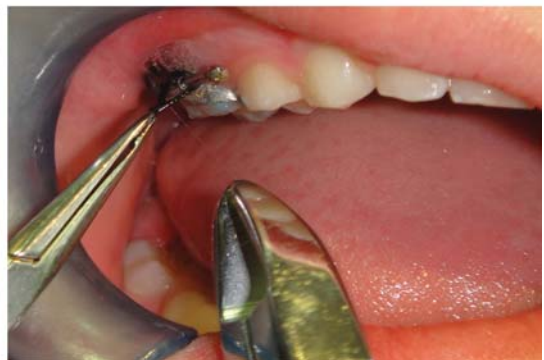(a)



(b)



(c)



(d)

Figure 13.20 (a) Bilateral ectopic eruption of maxillary first permanent molars. (b) Ectopic spring-loaded distalizer appliance. (c) Appliance delivered and flowable composite placed to secure extension over distobuccal cusp tip. (d) Black chain elastic cut to activate spring. (e) Black chain elastic removed. (f) Three months after delivery and activation. (g) Nine months after delivery. (h) Eleven months after delivery. (i) Appliance removed 12 months after delivery. (j) One year after appliance removed.

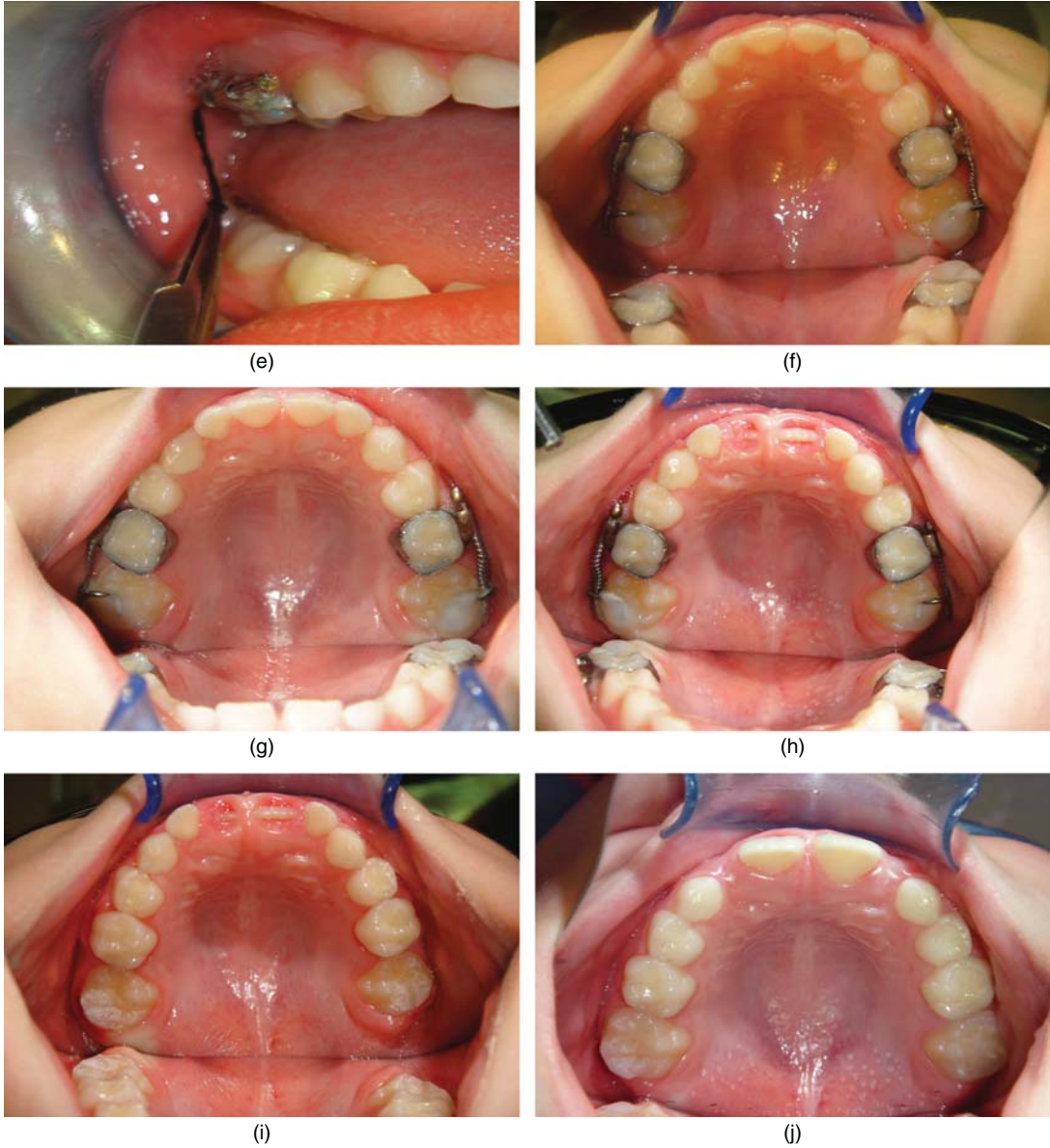


Figure 13.20 (Continued)

molar. When the first permanent molar is adequately erupted for banding, or the first primary molar is mobile and near exfoliation, the appliance may be changed to a transpalatal for unilateral loss of a second primary molar or a Nance appliance for bilateral loss of second primary molars. The parent/guardian should be informed of the possible requirement for a second appliance to maintain the space for the second premolar.

Summary

EE signifies a disturbance in the normal eruption of the permanent dentition. It most commonly affects the maxillary first permanent molars. The diagnosis of EE is usually made by radiographs. Clinical experience indicates that maxillary first permanent molars that are locked with their crowns visible in the mouth are not

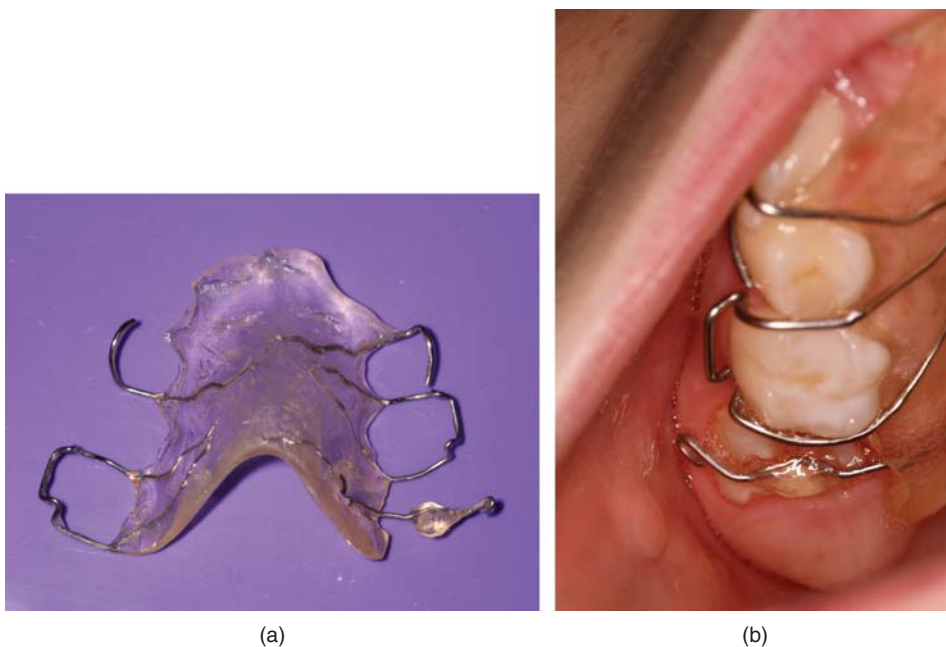


Figure 13.21 (a) The removable appliance is designed with typical retention clasps and a palatal finger spring that reaches the occlusal table of the blocked molar. (b) An acrylic button is attached to the distal end of the spring and contacts the occlusal surface of the molar.

good candidates for self-correction. Timely identification and intervention are mandatory. If left untreated, EE may cause serious sequelae, including early loss of the second primary molar, space loss, and impaction of second premolars.

Selected texts and figures have been adapted with permission from Dr. Kupietzky's previous works

Kupietzky, A. (2000) Correction of ectopic eruptions of permanent molars utilizing the brass wire technique. *Pediatric Dentistry*, **22**, 408–412. Figures 13.6–13.8 and 13.10–13.11

References

- Barberia-Leache, E., Suarez-Clua, M.C. & Saavedra-Ontiveros, D. (2005) Ectopic eruption of the maxillary first permanent molar: characteristics and occurrence in growing children. *Angle Orthodontics*, **75**, 610–615.
- Cerny, R. (2003) Jumbo separators for partial molar impactions. *Journal of Clinical Orthodontics*, **37**, 33–35.
- Chintakanon, K. & Boonpinon, P. (1998) Ectopic eruption of the first permanent molars: prevalence and etiologic factors. *Angle Orthodontist*, **68**, 153–160.
- Gehm, S. & Crespi, P.V. (1997) Management of ectopic eruption of permanent molars. *Compendium Continuing Education Dentistry*, **18**, 561–569.
- Halterman, C.W. (1982) A simple technique for the treatment of ectopically erupting permanent first molars. *Journal of the American Dental Association*, **105**, 1031–1033.
- Hirayama, K. & Chow, M.H. (1992) Correcting ectopic first permanent molars with metal or elastic separators. *Pediatric Dentistry*, **14**, 342–343.
- Huang, W. & Childers, N.K. (1995) Clinical aid in placing brass wires to treat ectopically erupting permanent first molars. *Pediatric Dentistry*, **17**, 122–123.
- Kim, Y.H. & Park, K.T. (2005) Simple treatment of ectopic eruption with a triangular wedging spring. *Pediatric Dentistry*, **27**, 143–145.
- Levitas, T.C. (1964) A simple technique for correcting an ectopically erupting maxillary first permanent molar. *Journal of Dentistry for Children*, **31**, 16–18.

کتاب پزشکی کام

تامین منابع علمی تخصصی پزشکی



کتاب پزشکی دات کام

www.ketabpezeshki.com

+98 21 6648 5438

+98 21 6648 5457

14

Ectopic eruption of maxillary permanent canines

Jane A. Soxman

The maxillary permanent canine normally erupts at the age of 11–12 years (American Academy of Pediatric Dentistry, 2014). The canine bulge should be palpable high in the alveolar process above the primary canine by the age of 9–10 years if dental and chronological ages are synonymous. At the age of 11–12 years, the absence of the canine bulge indicates a significantly higher possibility of palatal displacement (Chalakkal *et al.*, 2011). Digital palpation to determine the status of the maxillary permanent canines should be routinely performed. If the canine bulge is not palpated or the canine appears to be in an abnormal position with mesial inclination on palpation, radiographic examination with a panoramic or periapical radiograph is indicated. Abnormal inclination of the canine, mesially angled toward or superimposed over the root of the permanent lateral incisor or premolar, signals the need for immediate intervention to avoid root resorption, which can rapidly occur (Fricker *et al.*, 2008) (Figures 14.1–14.3a, 14.3b, and 14.4).

An overretained maxillary primary canine may indicate ectopic position of a permanent maxillary canine or a congenitally missing permanent successor (Figures 14.5a, 14.5b, 14.6a, and 14.6b).

Intervention

Timely intervention will promote normal eruption with spontaneous uprighting and distal movement of

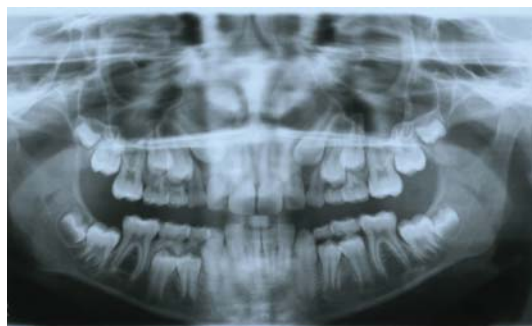

Figure 14.1 Panoramic radiograph showing bilateral ectopic position of maxillary permanent canines.

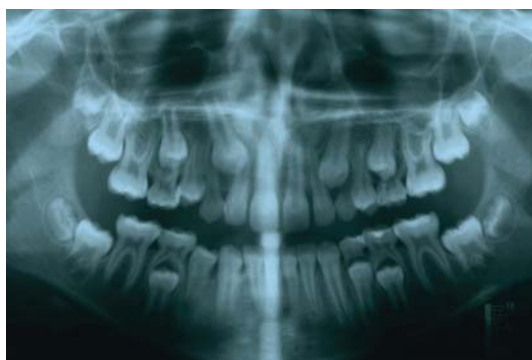

Figure 14.2 Panoramic radiograph showing abnormal inclination of the maxillary right permanent canine superimposed over the root of the maxillary right permanent lateral incisor.

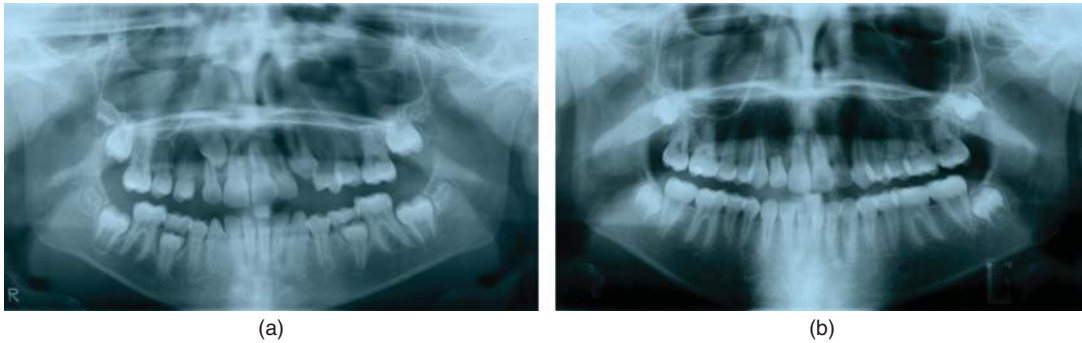

Figure 14.3 (a) Panoramic radiograph showing ectopic position maxillary right permanent canine. (b) Panoramic radiograph showing root resorption of the maxillary right permanent lateral incisor resulting from ectopic eruption of the maxillary right permanent canine.

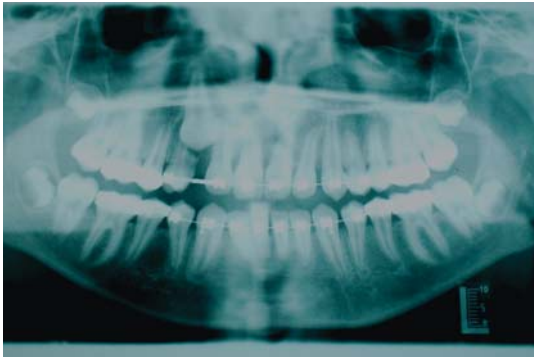

Figure 14.4 Panoramic radiograph showing root resorption of the maxillary right first premolar due to ectopic eruption of the maxillary right permanent canine.

the crown for both palatally or centrally positioned permanent canines (Bonetti *et al.*, 2011). Extract the primary canines after the permanent lateral incisors are fully erupted. With normal sequence of eruption, the maxillary first premolars erupt before the permanent canines. Maxillary premolars typically erupt when one-half to three-fourths of the root has formed (Terlaji & Donly, 2001). With a minimum of one-half root formation of the first premolar, the first primary molar is also extracted. Extraction of the first primary molar

before one-half root formation of the premolar may delay eruption of the premolar (Shapira *et al.*, 1998). Adding extraction of the maxillary first primary molar significantly improves the eruption path for the permanent canine (Figure 14.7a and 14.7b). Improvement of intraosseous position and uneventful eruption occurred in 97.3% of cases when extraction of the maxillary first primary molar was combined with extraction of the maxillary primary canine. (Bonetti *et al.*, 2011).

Unilateral or bilateral extraction is a case-by-case decision determined by the amount of maxillary arch length deficiency. If the ectopic canine is unilateral, with no arch length deficiency, extraction is limited to the primary canine/first primary molar on the affected side. In the presence of moderate to significant arch length deficiency, bilateral extractions are indicated (Figure 14.8) (Personal communication with Dr. Vincent Kokich).

Baccetti *et al.* (2008) found that after removal of the primary canines, normal eruption of a palatally displaced canine was increased from 35% to 65%. Adding cervical pull headgear increased the chance for intraosseous uprighting and normal eruption to 87.5%. Another study found rapid palatal expansion, after extraction of primary canines in the late mixed dentition, combined with a transpalatal arch, promoted normal eruption of palatally displaced canines (Sigler *et al.*, 2011).

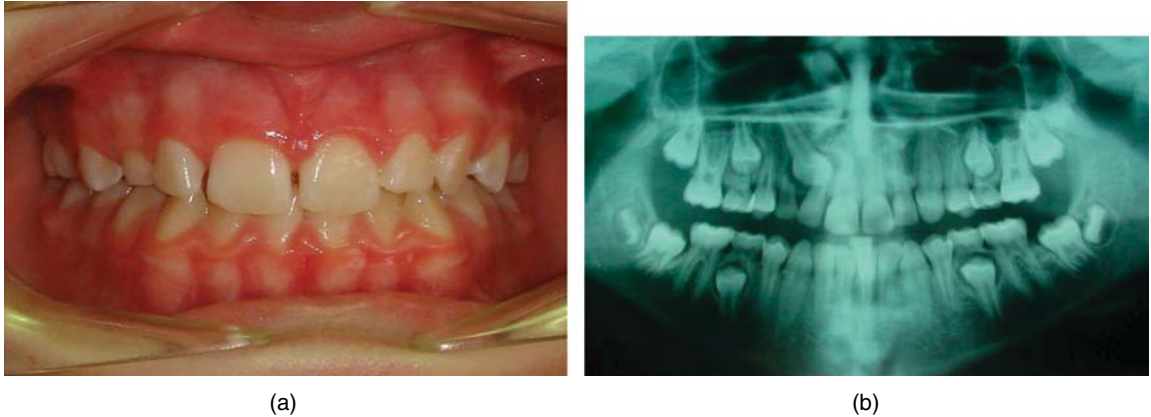


Figure 14.5 (a) Photograph showing overretained maxillary right primary canine. (b) Panoramic radiograph showing ectopic position of maxillary right permanent canine with overretained maxillary right primary canine.

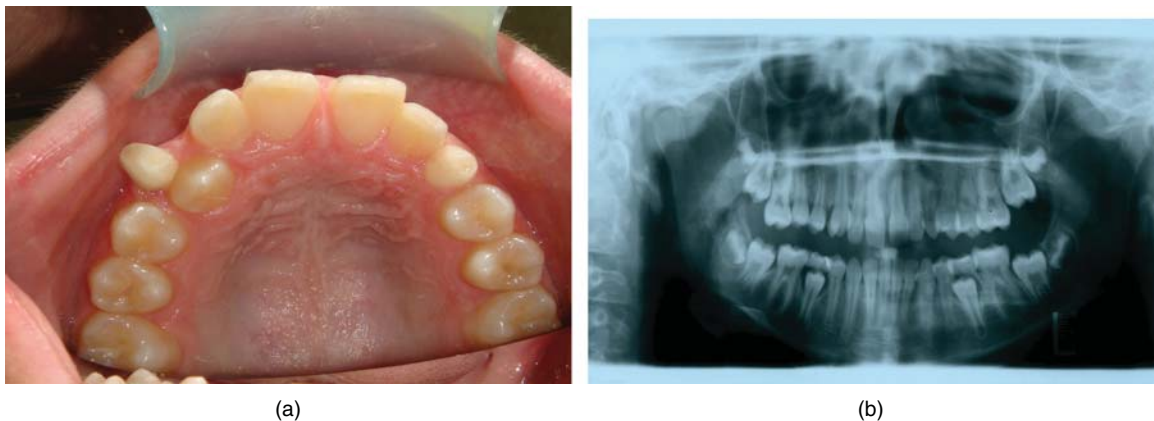


Figure 14.6 (a) Upper occlusal photograph of overretained maxillary right primary canine causing palatal displacement of maxillary right permanent canine and also showing retention of maxillary left primary canine. (b) Panoramic radiograph showing maxillary left primary canine with congenitally missing maxillary left permanent successor.

Although timely extraction of the primary canine and first primary molar is performed, exposure and orthodontic force may still be required to bring a horizontally impacted maxillary permanent canine into its proper position in the maxillary arch (Figure 14.9).

Distally displaced mandibular premolars are a valuable developmental risk indicator associated with palatally displaced maxillary canines. Observation of bitewing and periapical radiographs may provide an opportunity for earlier diagnosis (Baccetti *et al.*, 2010) (Figure 14.10).

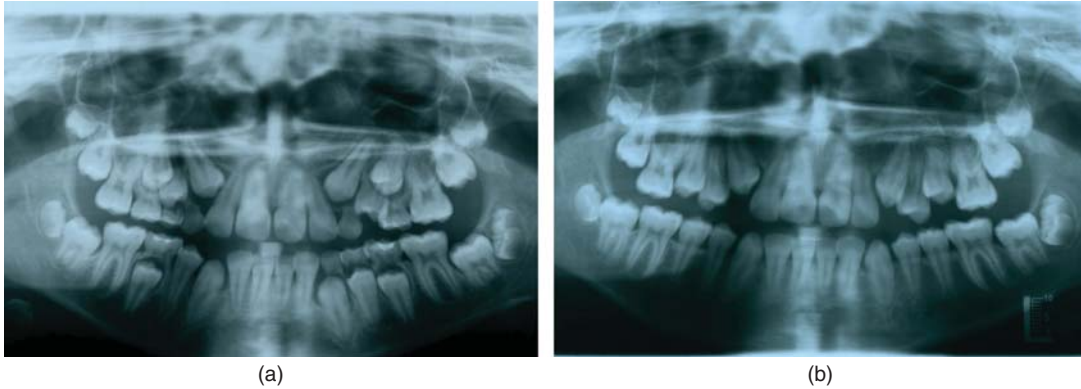


Figure 14.7 (a) Panoramic radiograph showing bilateral ectopic position of the maxillary permanent canines. (b) Panoramic radiograph showing uprighting of maxillary right and left permanent canines 1 year after extraction of maxillary right and left primary canines and maxillary right first primary molar.

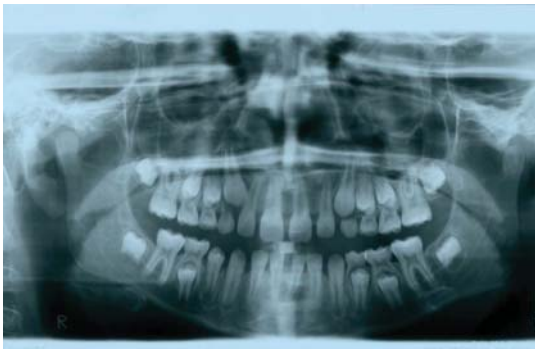

Figure 14.8 Panoramic radiograph showing indication for unilateral extraction of maxillary right primary canine and maxillary right first primary molar instead of bilateral extraction of primary canines and primary first molars due to no arch length deficiency.

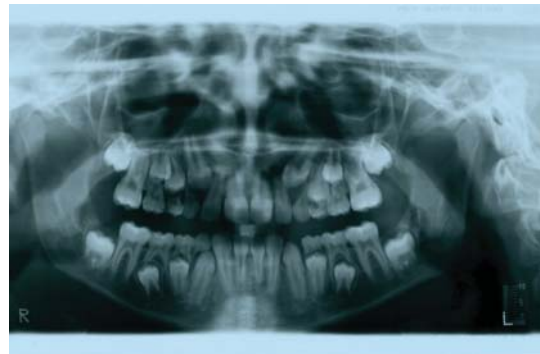

Figure 14.10 Panoramic radiograph showing distally displaced mandibular premolars with ectopic position of maxillary permanent canines.

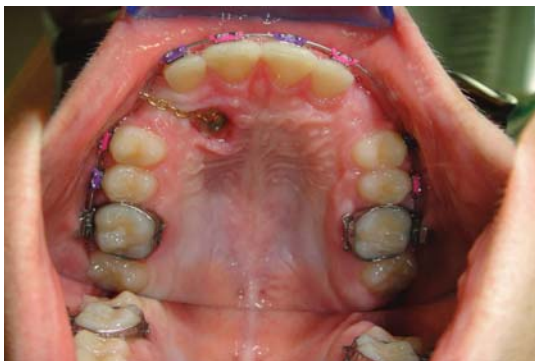

Figure 14.9 Occlusal photograph showing exposure of palatally impacted maxillary permanent canine.

References

- American Academy of Pediatric Dentistry. (2014) Resource section dental growth and development. *Pediatric Dentistry*, **36** (special issue), 371.
- Baccetti, T., Leonardi, M. & Armi, P. (2008) A randomized clinical study of two interceptive approaches to palatally displaced canines. *European Journal of Orthodontics*, **30**, 381–385.
- Baccetti, T., Leonardi, M. & Gliuntini, V. (2010) Distally displaced premolars: a dental anomaly associated with palatally displaced canines. *American Journal of Orthodontics and Dentofacial Orthopedics*, **138**, 318–322.
- Bonetti, G.A., Zanarini, M. *et al.* (2011) Preventive treatment of ectopically erupting maxillary canines by extraction of deciduous canines and first molars: a randomized clinical trial. *American Journal of Orthodontics and Dentofacial Orthopedics*, **139**, 316–323.

- Chalakkal, P., Thomas, A.M. & Chopra, S. (2011) Displacement, location, and angulation of unerupted permanent maxillary canines and absence of canine bulge in children. *American Journal of Orthodontics and Dentofacial Orthopedics*, **139**, 345–350.
- Fricker, J., Kharbanda, O.P. & Dando, J. (2008) Orthodontic diagnosis and treatment in the mixed dentition. In: Cameron, A.C. & Widmer, R.P. (eds), *Handbook of Pediatric Dentistry*, 3rd edn. Mosby, London, pp. 341–377.
- Shapira, Y., Kuftinec, M.M. & Stom, D. (1998) Early diagnosis and interception of potential maxillary canine impaction. *Journal of the American Dental Association*, **129**, 1450–1454.
- Sigler, L.M., Baccetti, T. & McNamara, J.A. Jr. (2011) Effect of rapid maxillary expansion and transpalatal arch treatment associated with deciduous canine extraction on the eruption of palatally displaced canines: a 2-center prospective study. *American Journal of Orthodontics and Dentofacial Orthopedics*, **139**, e235–e244.
- Terlaji, R.D. & Donly, K.J. (2001) Treatment planning for space maintenance in the primary and mixed dentition. *Journal of Dentistry for Children*, **68**, 109–114.

15

Infraocclusion of mandibular primary molars

Jane A. Soxman

When the occlusal surface of a primary molar is 1 mm or more below the occlusal plane of the adjacent teeth, the primary molar is submerged (Hvaring *et al.*, 2014). Submerging is usually the first clinical indication of an ankylosed primary molar (Figures 15.1 and 15.2). With normal development, adjacent teeth continue to erupt, and vertical bone height of the alveolar bone continues to increase, creating an impression of submerging of the affected primary molar. Ankylosis results from a fusion between the root's cementum and/or dentin with the surrounding alveolar bone, resulting in cessation of eruption of the primary molar and proximal alveolar bone growth. Interruption in the integrity of the periodontal ligament (PDL) impedes eruptive forces in the ankylosed tooth. A radiograph may or may not show loss of the PDL (American Academy of Pediatric Dentistry, 2014). Since only a small area of the root is affected, detection with a radiograph may be difficult (Tieu *et al.*, 2013). An increase in the occurrence of dental anomalies associated with infraocclusion has been reported. One study reported an increased incidence of distal angulation of the mandibular second premolar, microdontia of maxillary permanent lateral incisors, palatally displaced canines, and tooth agenesis (Shalish *et al.*, 2010). The presence or absence of a permanent successor is a primary factor influencing the treatment plan.

Submerged with permanent successor

In most cases, exfoliation of the infraoccluded primary molar occurs at the appropriate time without intervention. If a submerged primary molar is maintaining arch

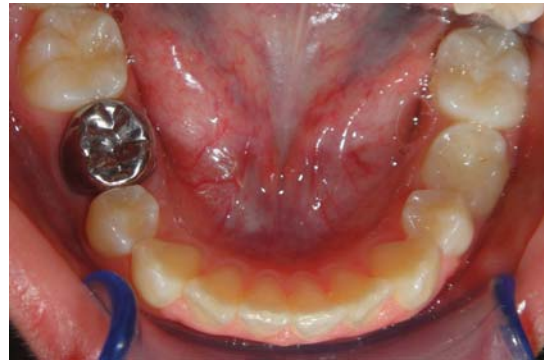

Figure 15.1 Submerging mandibular second primary molar occlusal view.

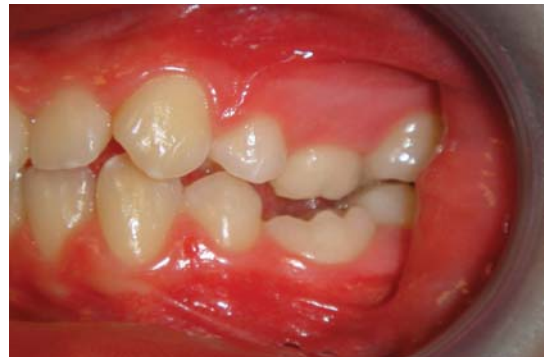

Figure 15.2 Submerging mandibular second primary molar buccal view.

length, preventing mesial shift of the first permanent molar, or is not impeding eruption of the permanent successor, the tooth may be maintained until normal

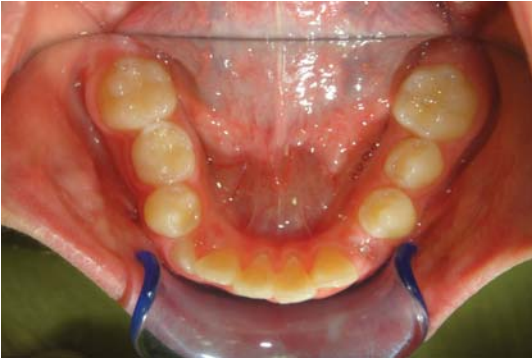


Figure 15.3 Submerged mandibular right second primary molar with contralateral second premolar erupted.

exfoliation or until the contralateral primary molar exfoliates (Fricker *et al.*, 2008). If the contralateral primary molar has exfoliated, its permanent successor has erupted, and the infraoccluded primary molar is not mobile, extraction of the infraoccluded primary molar is indicated (Figure 15.3). A periapical radiograph may be obtained to determine root length of the primary molar and position of the premolar. If the premolar is erupting with a mesial or distal path of eruption, the mesial or distal root of the mandibular primary molar may not resorb, causing infraocclusion and overretention of the mandibular primary molar (Figures 15.4 and 15.5). Crown build-up to preserve space, preventing tipping of adjacent teeth and supereruption of the tooth in the opposite arch may be performed (Dias *et al.*, 2012). With continued retention after loss of the contralateral primary molar, extraction of the

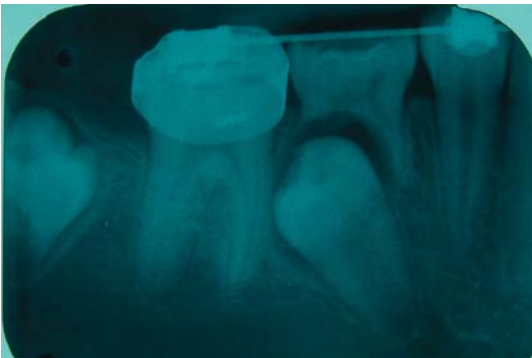

Figure 15.4 Periapical radiograph showing ectopic eruption of permanent successor.

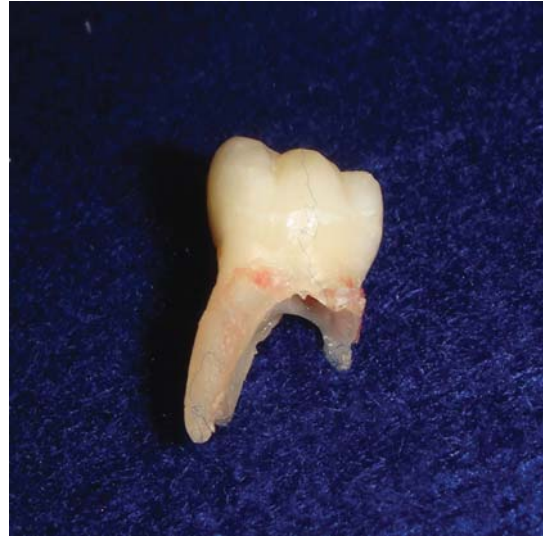

Figure 15.5 Extracted infraoccluded mandibular second primary molar with lack of distal root resorption.

retained primary molar is indicated. Distal eruption of the succeeding premolar is a complication that also occurs and warrants consideration of timely extraction and appropriate space management (Tieu *et al.*, 2013). Root development of the permanent successor may be delayed with delayed root resorption of an ankylosed primary molar. If the decision is made not to extract the ankylosed primary molar, both root formation and eruption of the permanent successor, along with root resorption of the ankylosed primary molar, should be periodically evaluated (Nazif *et al.*, 1986).

Late extraction of primary molars with severe infraocclusion may result in risk to the alveolar bone development. To protect vertical alveolar bone growth between mandibular first permanent molars and second premolars, earlier extraction is indicated in the presence of a marked marginal ridge discrepancy, resulting in tipping of adjacent teeth, space loss, and ectopic position of the premolar (Dias *et al.*, 2012). Vertical or oblique bone loss, apparent on radiographic examination, signals extraction of the ankylosed primary molar to maintain marginal alveolar bone height (Figure 15.6). After early extraction, a vertical bony defect may be present, but continued eruption of the adjacent teeth will promote growth of the bone and tissue to their normal levels, eliminating the alveolar defect (Kokich & Kokich, 2006).

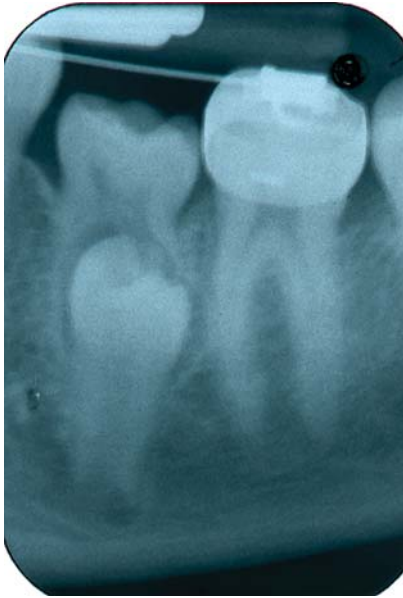

Figure 15.6 Periapical radiograph showing vertical bone loss of infraoccluded mandibular left second primary molar.

Sectioning ankylosed primary molars for extraction maintains alveolar bone and prevents root fracture (See procedure for extracting ankylosed primary molar in Chapter 8).

Submerged with congenitally missing permanent successor

In the absence of ankylosis, primary molars without permanent successors may function for many years before exfoliation, preserving alveolar bone height and width (Sletten *et al.*, 2003; Sabri, 2004). If a periapical radiograph shows flat bone levels between the submerged primary molar and adjacent teeth, the tooth may be maintained, preserving alveolar bone until facial growth is complete, and an implant can be placed (Kokich & Kokich, 2006) (Figure 15.7). In this case, the mesial and distal surfaces of the mandibular primary molar can be disked to achieve premolar width. The mesiodistal width at the cemento-enamel junction measured on a bitewing or periapical radiograph provides a good guideline for the amount of reduction, as does comparison to the contralateral side (Figure 15.8). The average width of the mandibular second premolar is

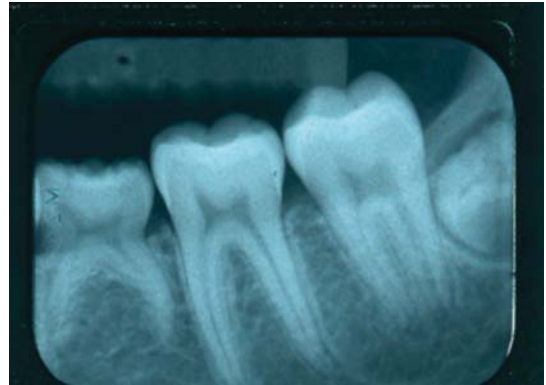

Figure 15.7 Periapical radiograph showing submerged mandibular second primary molar with level interproximal bone and congenitally missing successor.

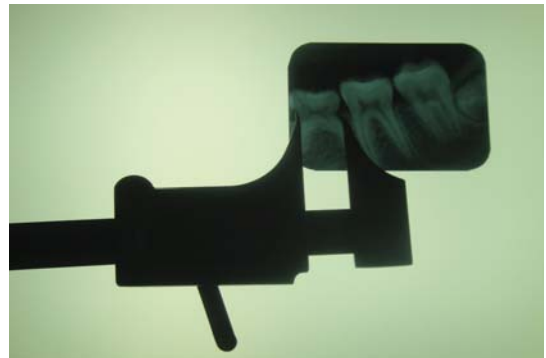


Figure 15.8 Measuring cemento-enamel junction on periapical radiograph with Boley gauge.

7.5 mm (Kokich & Kokich, 2006). Seven millimeters has also been recommended as the width to attain (Sabri, 2004). This size can be marked with a pencil or marking pen on the occlusal of the primary molar to provide a guide for reduction. After administration of local anesthesia and rubber dam placement, a carbide fissure or diamond bur may be used to remove interproximal enamel, avoiding pulpal exposure. The bur is maintained in a vertical position (Figure 15.9). A layer of composite may be added on the mesial and distal surfaces to prevent caries. The occlusal surface is built up with composite to achieve a level occlusal plane, preventing super eruption of the tooth in the upper arch (Figure 15.10). Alternatively, a stainless steel, veneered or zirconia crown may be placed (Figure 15.11).

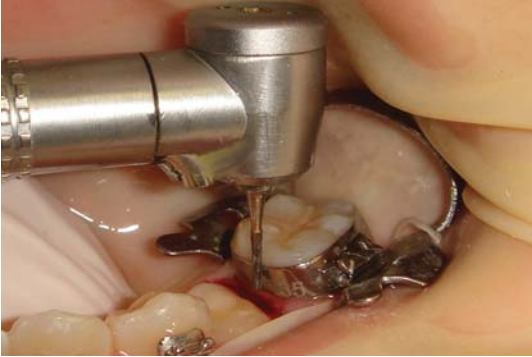

Figure 15.9 Interproximal reduction on distal of second primary molar.

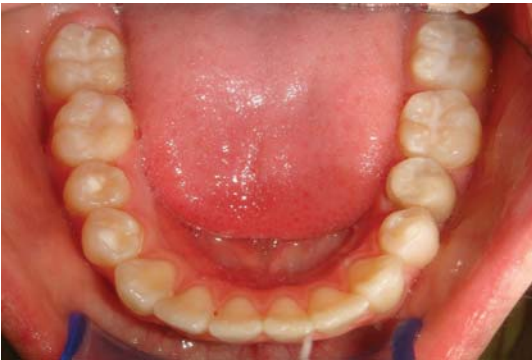

Figure 15.10 Reshaped mandibular second primary molar to premolar morphology.

Because the roots of the primary molar diverge beyond the width of the crown, there may be unwarranted concern that the space cannot be closed adequately with interproximal reduction. The socket wall of the adjacent permanent teeth moves closer and is eventually in contact with the roots of the primary molar, causing root resorption. Bone replaces the roots, creating an ideal site for future implant (Kokich & Kokich, 2006).

With vertical bone loss, extraction is indicated (Figure 15.12). An orthodontic consultation will assist in determining whether to maintain or close the space after extraction. If the decision is to maintain the space for a future restoration, the orthodontic goals will include establishing the appropriate amount of space for an implant and the preservation of the alveolar ridge.

Delaying extraction of an ankylosed primary molar, until after orthodontic treatment will often result in a

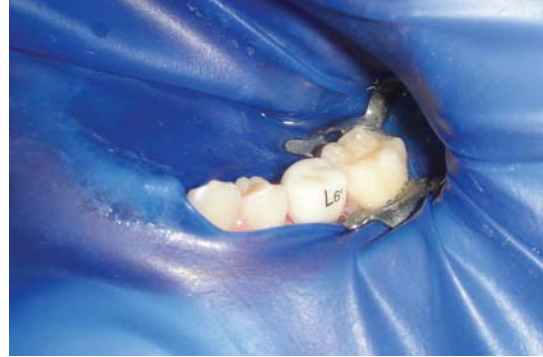


Figure 15.11 Zirconia crown on mandibular second primary molar. Note the “prime” notation for a more narrow mesial–distal size crown. Size removed with a spoon or rubber point after cementation.

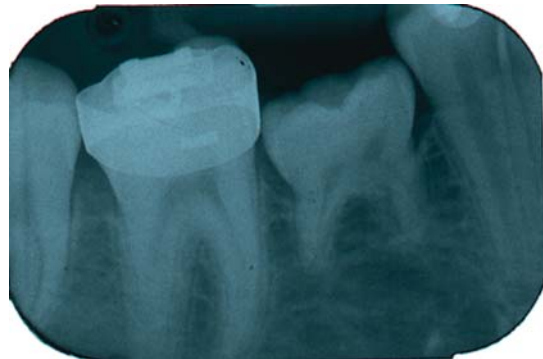

Figure 15.12 Periapical radiograph of infraoccluded mandibular second primary molar with congenitally missing permanent successor.

vertical defect in the alveolar bone, especially if there has been significant vertical development of the surrounding alveolar ridge. Bone grafting most likely will be necessary, increasing treatment costs and difficulty placing an implant (Sabri, 2004).

The timing for extraction in a growing child is critical. If early extraction is performed due to observed early submerging, the alveolar ridge usually moves occlusally with eruption of adjacent teeth as the periosteum is stretched over the extraction site. Vertical crestal bony defects are prevented. Early extraction of the ankylosed mandibular second primary molar is preferred over late (Sabri, 2004).

If substantial bone resorption with significant buccolingual narrowing of the alveolar ridge and loss of

vertical height occurs after extraction, the first premolar may be orthodontically moved into the extraction site. This movement will provide a suitable ridge for a single-tooth implant for the first premolar after facial growth is complete. An osseointegrated implant is biologically conservative and the first choice for a congenitally missing mandibular premolar. An implant can be placed after vertical facial growth is complete, confirmed by serial cephalometric superimpositions. On an average, girls' facial growth may occur until the age of 17 years and boys' until the age of 21 years (Kokich & Kokich, 2006).

With early extraction, the width of the alveolar ridge may be reduced by 30% over 7 years. Although the ridges may still be wide enough for an implant, the implant must be placed toward the lingual because the ridge resorbs more on the facial side. The consequence is that the occlusion on the buccal and lingual cusps of the implant's crown must be altered to avoid fracture of the abutment or the implant crown (Kokich & Kokich, 2006).

Appropriate management of infraoccluded mandibular primary molars is mandatory to preserve the alveolar bone and for future orthodontic and possible prosthetic considerations. Interdisciplinary collaboration is mandatory. Orthodontists should be given the opportunity to prepare and maintain alveolar bone throughout the mixed dentition. Inappropriate management will negatively impact orthodontic treatment, creating significant challenges, if the advantages and disadvantages of the approaches are not understood (Tieu *et al.*, 2013). Appropriate and timely management of infraoccluded primary molars will reduce treatment costs and prevent negative consequences that could last a lifetime.

References

- American Academy of Pediatric Dentistry (2014) Guideline on management of the developing dentition and occlusion in pediatric dentistry. *Pediatric Dentistry*, **36** (special issue), 251–263.
- Dias, C., Closs, L.Q., Fontanella, V. *et al.* (2012) Vertical alveolar growth in subjects with infraoccluded mandibular deciduous molars. *American Journal of Orthodontics and Dentofacial Orthopedics*, **141**, 81–86.
- Fricter, J., Kharbada, O.P. & Dando, J. (2008) Orthodontic diagnosis and treatment in the mixed dentition. In: Cameron, A.C. & Widmer, R.P. (eds), *Handbook of Pediatric Dentistry*, 3rd edn. Mosby, London, pp. 341–377.
- Hvaring, C.L., Ogaard, B., Stenvik, A. *et al.* (2014) The prognosis of retained primary molars without successors: infraocclusion, root resorption and restorations in 111 patients. *European Journal of Orthodontics*, **36**, 26–30.
- Kokich, V.G. & Kokich, V.O. (2006) Congenitally missing mandibular second premolars: clinical options. *American Journal of Orthodontics and Dentofacial Orthopedics*, **130**, 437–444.
- Nazif, M., Zullo, T. & Paulette, S. (1986) The effects of primary molar ankylosis on root resorption and the development of permanent successors. *Journal of Dentistry for Children*, **53**, 115–118.
- Sabri, R. (2004) Management of congenitally missing second premolars with orthodontics and single-tooth implants. *American Journal of Orthodontics and Dentofacial Orthopedics*, **125**, 634–642.
- Shalish, M., Peck, S., Wasserstein, A. *et al.* (2010) Increased occurrence of dental anomalies associated with infraocclusion of deciduous molars. *Angle Orthodontist*, **80**, 440–445.
- Sletten, D.W., Smith, B.M., Southard, K.A. *et al.* (2003) Retained deciduous mandibular molars in adults: a radiographic study of long-term changes. *American Journal of Orthodontics and Dentofacial Orthopedics*, **124**, 625–630.
- Tieu, L.D., Walker, S.L., Major, M.P. *et al.* (2013) Management of ankylosed primary molars with premolar successors. *Journal of the American Dental Association*, **144**, 602–611.

Space maintenance may be necessary after premature tooth loss in the primary and mixed dentition to preserve arch length, width, and perimeter (American Academy of Pediatric Dentistry, 2014a). Space loss is considered to be one of the major contributors to malocclusion in the permanent dentition, along with ectopic eruption or impaction of premolars (Simon *et al.*, 2012; Dean, 2012). For cases in which space loss has already occurred, such as with ectopic eruption of maxillary first permanent molars or space loss due to interproximal caries before extraction, appliances are used for space control. Preservation of the tooth with restoration or delaying extraction should be considered, understanding that the natural tooth is the best space maintainer. If orthodontic treatment is to begin within 6 months of primary molar loss or the permanent successor is near eruption, a space maintainer may not be necessary.

Sequence of eruption

Sequence of eruption, which may vary, should be considered when treatment planning for a space maintainer in the early and late mixed dentition. In the mandible, the first permanent molars erupt first, followed by the central incisors, lateral incisors, canines, first premolars, and second premolars. In the maxilla, the first permanent molars are followed by the central incisors, lateral incisors, first premolars, second premolars, and last, the canines. This sequence of eruption in the maxilla will be a consideration when managing ectopic eruption of the maxillary permanent canines (American Academy of Pediatric Dentistry, 2014b).

Dental age

Dental age and chronological age may differ. Typically, the permanent first molar erupts at the age of 5.5–7 years, and mandibular incisors erupt at the age of 6–7 years, but if eruption does not occur until the age of 8 or 9 years, the child is dentally delayed. This delay typically follows throughout the eruption of the permanent dentition. Conversely, if the permanent dentition erupts earlier than usual, the child is dentally ahead (American Academy of Pediatric Dentistry, 2014b).

Alveolar bone covering permanent successor

The amount of alveolar bone covering the permanent successor should also be considered. About 6 months is necessary for the permanent successor to move through 1 mm of bone, which can be determined with a bitewing or periapical radiograph (Simon *et al.*, 2012).

Root development of permanent successor

Root length of the permanent successor should be evaluated. Premolars typically erupt when one-half to three-fourths of the root has formed (Terlaji & Donly, 2001). If the primary molar is extracted due to an abscess, the permanent successor may erupt more rapidly than expected with less root formation.

Time elapsed since loss of primary tooth

Space maintainers should be inserted within a few weeks after an extraction. Space loss usually occurs within 6 months after premature loss of a primary molar (Simon *et al.*, 2012). Space loss typically occurs more rapidly in the maxilla than in the mandible. Inform parents/guardians that if too much time elapses before insertion, space closure may occur and the space maintainer will no longer fit. Another impression and laboratory fee for fabrication of a revised space maintainer will be necessary. If possible, obtain a photograph or radiograph of the site to document space loss before inserting the appliance.

Space maintenance appliances

Fixed appliances are preferable to removable, avoiding loss, breakage, choking, and noncompliance with wear. The band and loop or crown and loop are used for premature loss of a maxillary or mandibular first primary molar. For premature loss of a second primary molar, the Nance or transpalatal arch appliances are used in the maxillary arch and the lower lingual holding arch (passive lingual arch) are used in the mandible. Actual examples of appliances can be used for more detailed explanation along with a mixed dentition typodont (Kilgore International) (Figure 16.1).

Problems with space maintainers

Space maintainers require follow-up. Parents/guardians should be informed of the need to immediately notify the practice if the space maintainer becomes loose, is dislodged from the tooth, broken, or is interfering with the eruption of a permanent tooth (Figure 16.2). If the primary molar banded for the appliance exfoliates, a second appliance may be indicated to maintain space for a second premolar. Fixed appliances may increase the incidence of caries on the banded molar or adjacent teeth in children with high-caries risk (Fricker *et al.*, 2008). Poor oral hygiene can result in decalcification at the cervical margin of the band. Cementing bands with glass ionomer cement may reduce the risk of decalcification and caries. Removing the appliance to

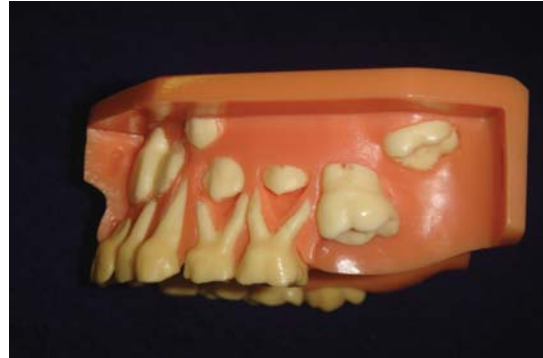

Figure 16.1 Mixed dentition typodont (Kilgore International).

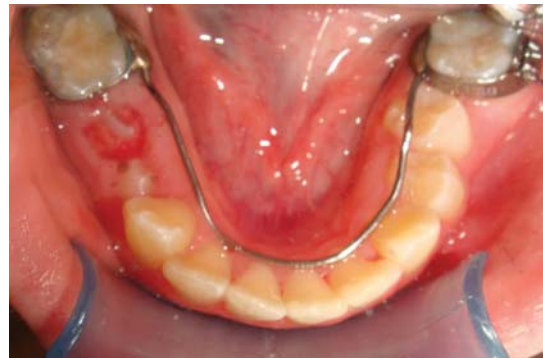

Figure 16.2 Lingual arch wire interfering with eruption of mandibular second premolar.

perform prophylaxis may be advisable every 6 months. A portion of the appliance may impinge on the gingival tissues after a period. Any complaint of discomfort by the child should be reported to the practice. Documentation in the patient's chart of provision of this information to parents is advisable. Mean survival times for space maintainers are reported as between 26 and 27 months. The main reasons for failure were cement loss, split bands, eruption interference, bent wire, and solder breakage (Fathian *et al.*, 2007). A lingual arch wire with a long arm has a significantly higher chance of solder breakage. Some insurance companies provide a code to recement an appliance.

Primary incisors

After eruption of the primary canines, premature loss of one or more primary incisors due to trauma or caries

results in negligible space loss (Fricker *et al.*, 2008). Space maintenance is necessary only for aesthetic concerns or parental desire (Simon *et al.*, 2012; Kupietzky, 2001). If a digit-sucking habit is of enough intensity, the space for the erupting permanent incisor may be reduced (American Academy of Pediatric Dentistry, 2014a). With significant overjet due to a parafunctional habit, fabrication of a partial denture (pedo partial) should be delayed until cessation of the habit. A fixed partial denture can be fabricated for both the maxilla and mandible with one or more denture teeth (Figure 16.3). If primary molar bands are not available when the impression is obtained or if the child cannot cooperate for banding, banding can be performed on the plaster model by the laboratory fabricating the appliance.

First primary molar

If the maxillary or mandibular first permanent molars are fully erupted and in good occlusion, and if the permanent incisors are erupted, space maintenance may not be necessary. In addition, if the child is younger than 4 years, and a periapical radiograph shows the first permanent molar to be a few millimeters below the alveolar bone or with less than one-half root formation, placement of a space maintainer may be delayed until closer to the anticipated time of eruption of the first permanent molar.

With loss of the first primary molar, before the eruption of the first permanent molar or when the first permanent molar is erupting, a band and loop in the maxilla or mandible or lingual archwire in the mandible

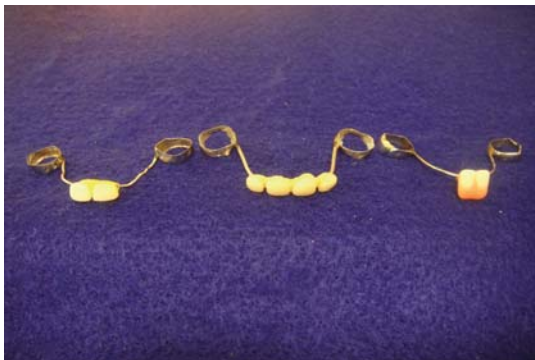

Figure 16.3 Maxillary and mandibular pedo partials for premature loss of primary incisors.

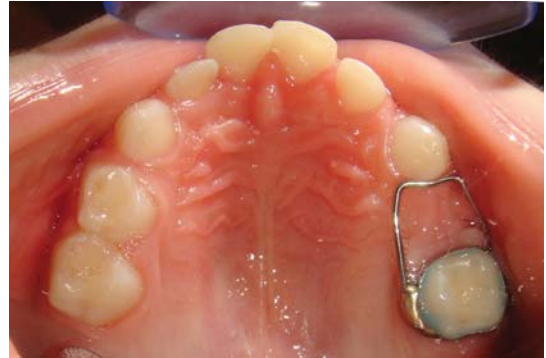

Figure 16.4 Band and loop for premature loss of maxillary first primary molar with unerupted first permanent molar.

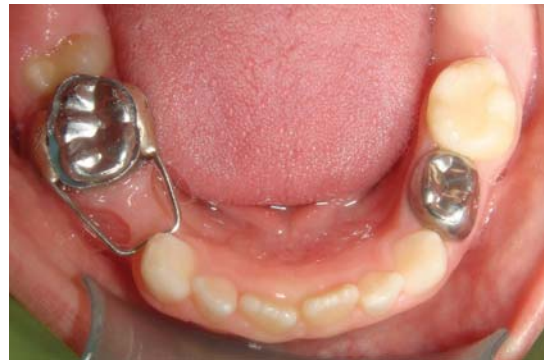

Figure 16.5 Band and loop for premature loss of mandibular first primary molar with partially erupted first permanent molar.

is necessary to avoid mesial drift of the second primary molar into the extraction site (Tunison *et al.*, 2008). For premature loss of a first primary molar in the maxilla or mandible, the second primary molar is banded, and the loop extends mesially to the distal of the primary canine (Figures 16.4 and 16.5).

Although a first permanent molar may be fully erupted in the maxilla, space loss has been shown to occur primarily as a result of distal drift of the primary canine into the extraction site and palatal movement of the maxillary incisors (Figure 16.6) (Lin *et al.*, 2007). This same distal movement of the primary canine may occur in the mandible (Tunison *et al.*, 2008).

Second primary molar

Premature loss of a second primary molar always requires a space maintainer. If the first permanent

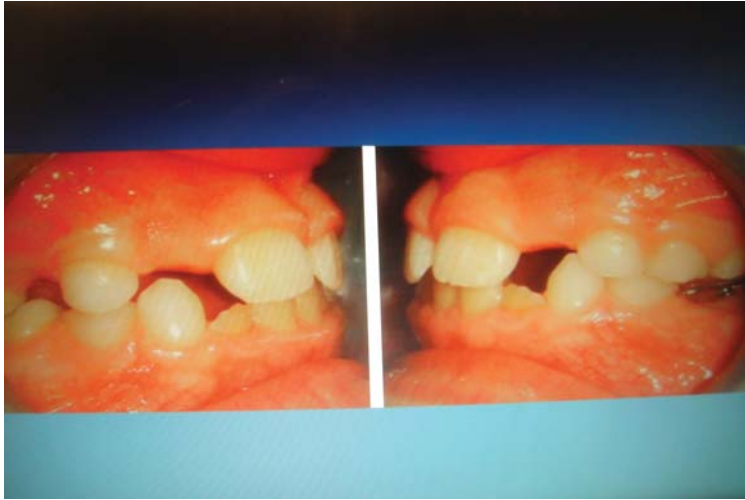

Figure 16.6 Distal drift of maxillary right primary canine into first primary molar extraction site.

molar is fully erupted, it is banded and the appliance is fabricated with a loop extending to the distal of the first primary molar or the first primary molar is banded with the loop extending distally to mesial of the first permanent molar (Figures 16.7 and 16.8). If the crown of the first permanent molar is not sufficiently erupted for banding, the first primary molar is instead banded, and the loop extends distally to the mesial of the partially erupted first permanent molar (Figure 16.9). When the crown of the first permanent molar is sufficiently erupted for banding, or when the first primary molar is near exfoliation, a Nance or transpalatal arch appliance replaces the band and loop in the maxillary arch. In the mandibular arch, a passive lingual arch appliance

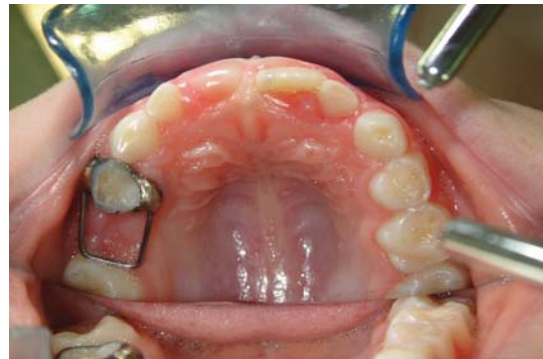

Figure 16.8 Band and loop with first primary molar banded and loop extending distally to mesial of the first permanent molar.

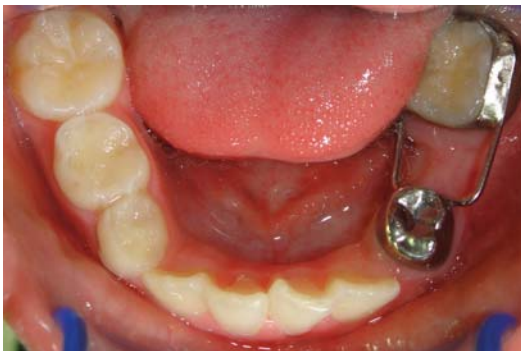

Figure 16.7 Band and loop with first permanent molar banded and loop extending mesially to distal of the first primary molar.

is recommended after eruption of the mandibular incisors for premature loss of a second primary molar (Figure 16.10). Parents/guardians should be informed at the outset that a second appliance may be required and that dental insurance may not cover the second appliance.

Band and loop

Most often used for unilateral space loss, but may be used bilaterally in the mandible before eruption of the mandibular permanent incisors. The primary or permanent molar is banded. A 0.036-in. round wire is used to make a loop that extends to the abutment tooth. The loop should be wide enough to permit eruption of

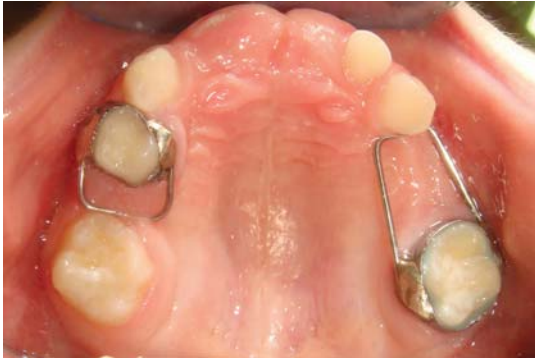

Figure 16.9 Band and loop with first primary molar banded and loop extending distally to the mesial of the partially erupted first permanent molar. This appliance is often necessary as an interim appliance with premature loss of the second primary molar due to ectopic eruption of the maxillary first permanent molar. Note space loss has occurred due to ectopic eruption along with rotation of first permanent molar on long axis. A Nance appliance will be fabricated for this patient when the right and left maxillary first permanent molars are erupted adequately to band.

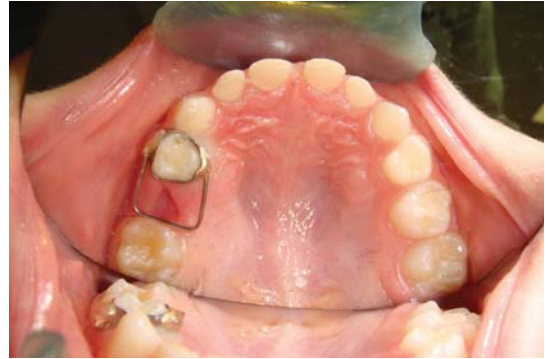

Figure 16.11 Band and loop with wide loop.

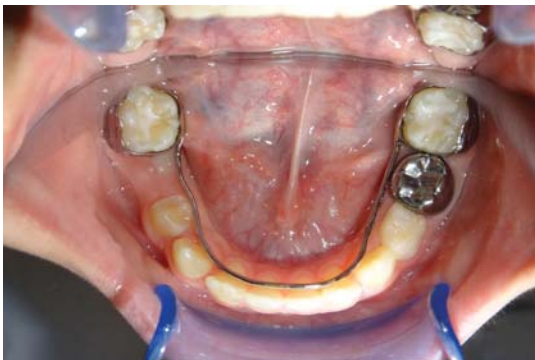

Figure 16.10 Passive lingual arch appliance for premature loss of mandibular second primary molar.

the premolar should that occur before removal of the appliance (Figures 16.11 and 16.12).

Transpalatal arch/palatal arch bar

The maxillary first permanent molars are banded and a 0.036- or 0.040-in. round wire is contoured to the posterior hard palate and soldered to the palatal side of the bands (Figure 16.13). This appliance prevents mesial tipping of the first permanent molar and is used only with unilateral loss of a second primary molar. The remaining second primary molar assists in reducing the tendency of the maxillary first permanent molar

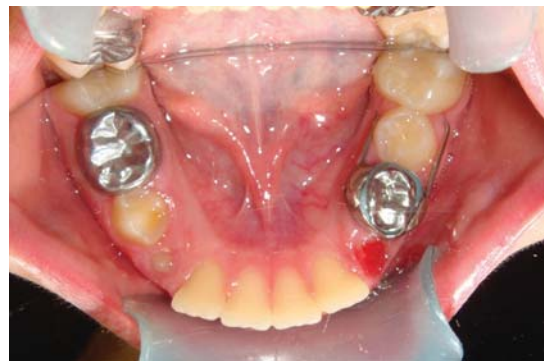

Figure 16.12 Mandibular second premolar erupting inside the loop of the band and loop.

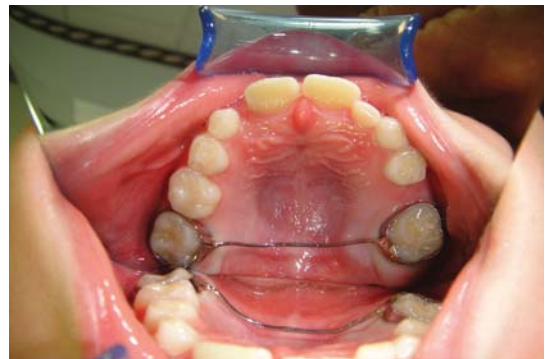


Figure 16.13 Transpalatal arch/palatal arch bar for premature unilateral loss of a maxillary second primary molar.

to rotate around its palatal root causing space loss. An omega loop may be incorporated in the transpalatal bar for placing a light distal force, curtailing tipping and/or rotation of the first permanent molars (Terlaji & Donly, 2001) (Figure 16.14).

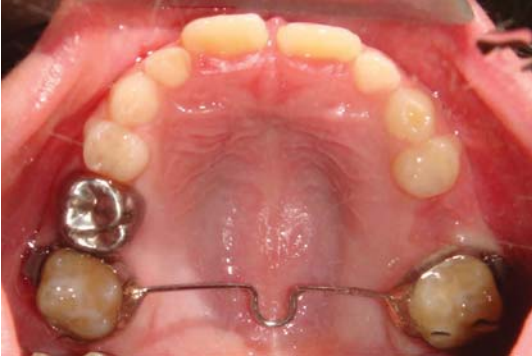


Figure 16.14 Transpalatal arch/palatal arch bar with an omega loop for premature unilateral loss of a maxillary second primary molar.

Nance appliance

Used for unilateral or bilateral loss of maxillary second primary molars. The first permanent molars are banded, and a transpalatal wire, embedded in an acrylic button, contacts the palatal rugae (Figure 16.15a and 16.15b). Soft tissue irritation with food impaction under the acrylic button is the primary problem with this appliance. Providing the patient with a monoject syringe to irrigate the area may be helpful.

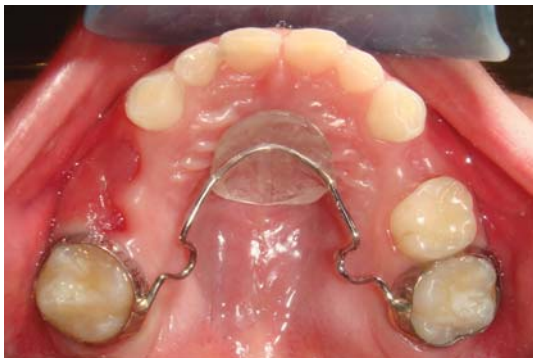Lower lingual holding arch/passive lingual arch

Indicated for bilateral loss of the mandibular second primary molars after eruption of the permanent mandibular incisors to avoid interference with their eruption (Dean, 2012). If a mandibular incisor is

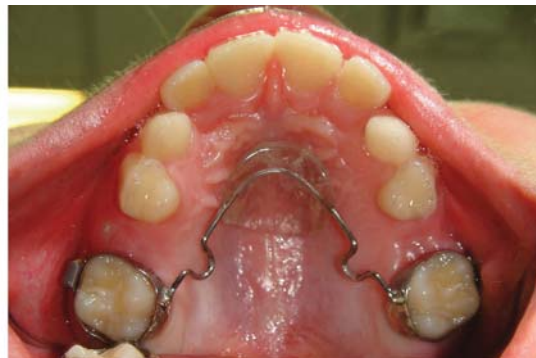erupting to the lingual at the time of the delivery, waiting 2–3 weeks should be adequate time for the permanent incisor to spontaneously correct its position in the arch. If an overretained primary incisor is causing lingual eruption, extraction should be performed (Figure 16.16a and 16.16b). The mandibular first permanent or second primary molars are banded. A 0.036- or 0.040-in. round wire is soldered to the lingual surface of the molar bands. The wire should contact the lingual surface of all mandibular incisors (Figure 16.17).

Distal shoe

This appliance is used with premature loss of a second primary molar when the first permanent molar is unerupted. The distal shoe prevents mesial drift of the first permanent molar during eruption. A periapical radiograph is necessary to determine the position of the developing first permanent molar. A plaster model and periapical radiograph may be sent to the laboratory for appliance fabrication before extraction of the second primary molar. Delivering the appliance at the time of the extraction avoids an additional appointment, another injection of local anesthesia and surgical incision. The first primary molar is banded or restored with a stainless steel crown for attachment of a 0.036- or 0.040-in. round wire. The wire extends to a distal extension, placed subgingivally 1.0–1.5 mm below the marginal ridge of the unerupted permanent molar (Figure 16.18). A periapical radiograph is obtained with try-in before cementation to evaluate the position of the distal shoe blade in relation to the first permanent molar. If necessary, the distal shoe blade



(a)



(b)

Figure 16.15 (a) Nance appliance for unilateral premature loss of a maxillary second primary molar. (b) Nance appliance for bilateral premature loss of maxillary second primary molars.

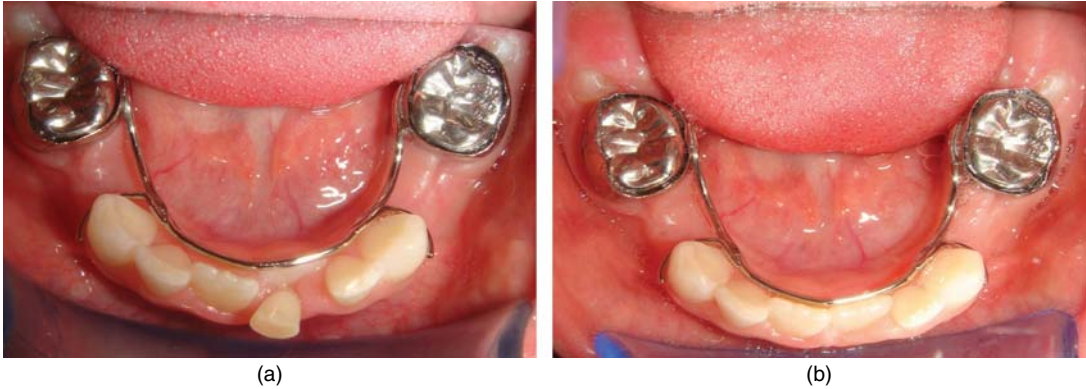

Figure 16.16 (a) Mandibular central incisor erupting in lingual position and lingual arch wire impeding eruption. (b) Lingual arch wire delivered 3 weeks later after spontaneous correction in arch of mandibular central incisor.

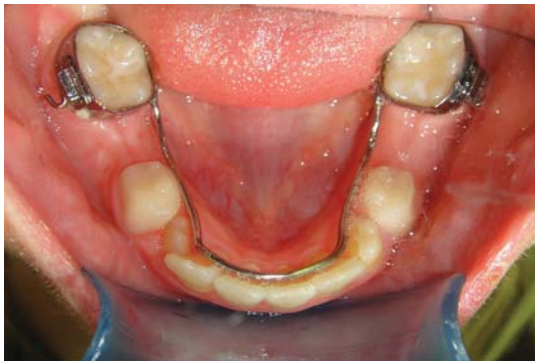

Figure 16.17 Lower lingual holding arch or passive lingual arch.

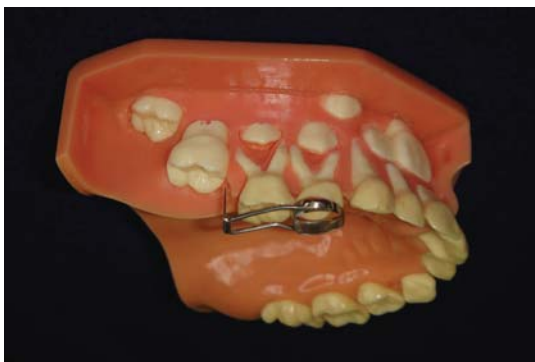

Figure 16.18 Distal shoe appliance.

may be shortened with a carbide bur in high speed. The subgingival blade guides the path of eruption of the first permanent molar. The patient is monitored every 2 months to assess the integrity of the appliance

(Brill, 2002). The distal shoe is replaced with another appliance upon eruption of the first permanent molar. This appliance is not commonly used because of the requirement for conscientious follow-up and risk of infection with poor oral hygiene. The distal shoe is contraindicated in immunocompromised children (Simon *et al.*, 2012). The distal shoe may be used in either arch, but care must be taken to assure no perforation of the floor of the maxillary sinus.

Banding and impression for appliance fabrication

Stainless steel bands, a band remover and a bite stick to seat the bands are required for fitting molar bands (Figure 16.19). Stainless steel bands without brackets

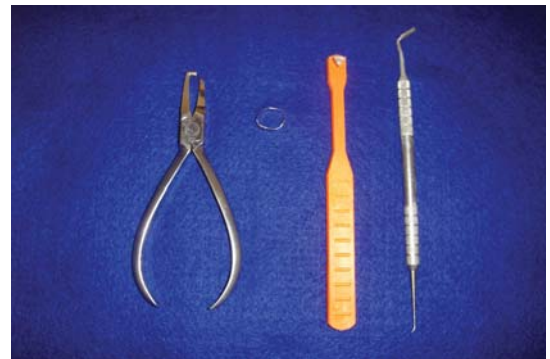

Figure 16.19 Band remover, stainless steel band, bite stick, and band seater.

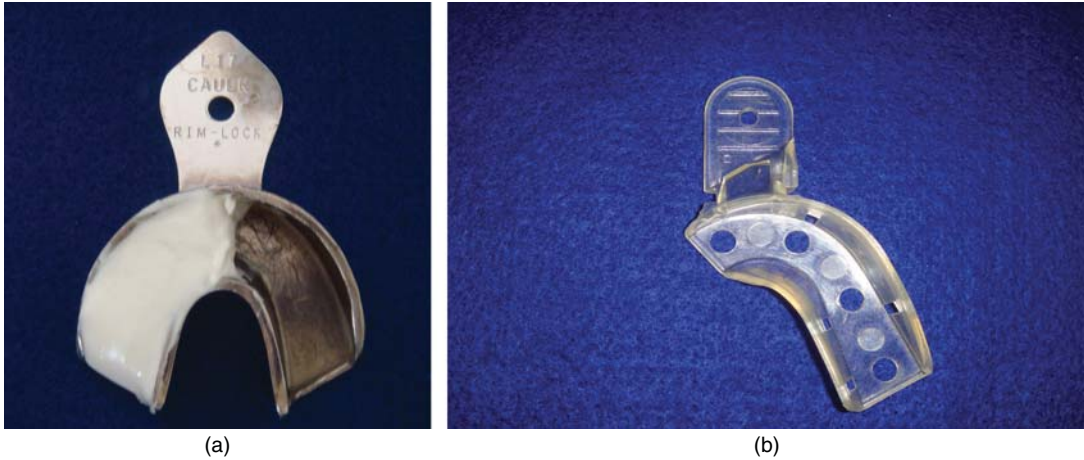


Figure 16.20 (a) One half of tray filled with impression material for band and loop. (b) Half impression tray.

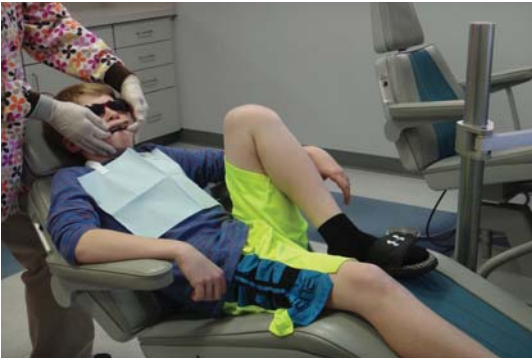

Figure 16.21 Bent knee to reduce gag reflex while taking impression.

or buccal tubes for fabrication of space maintainers may be purchased. If the practice does not have the armamentarium for molar banding or the child cannot cooperate for banding, the molars can be banded by the laboratory on the plaster model. In some cases, placing an orthodontic separator between the first permanent molar and the second primary molar will open the contact, to facilitate seating the band. The separator remains in place for about a week. Measuring the molar to be banded with a Boley gauge may help to select the correct size for the band before try-in. A band seater and/or bite stick, or in some cases a tongue blade, may be used to have the patient seat the crown. If using a band seater or bite stick, step around the band for seating.

Impression material should be fast setting. Filling one-half of the tray with impression material or using a half-tray facilitates obtaining the impression for a band and loop space maintainer (Figure 16.20a and 16.20b). If the patient has a gag reflex, suggest that he or she press a foot into the chair with a bent knee, while the impression is being taken (Figure 16.21). If a child is crying while the impression is being obtained, use compound instead of alginate to avoid possible aspiration of impression material.

The band remover is used to remove the band from the buccal and palatal sides after taking the impression (Figure 16.22a and 16.22b).

The band is seated in the impression, taking care to place the band in the proper occluso/cervical direction.

Movement of the bands within the impression while pouring the plaster into the impression may result in improper position of the band once the plaster sets. Placing staples to stabilize the band has been recommended (Personal communication Dr. Greg Psaltis) (Figures 16.23, 16.24a, 16.24b, 16.25, and 16.26).

Chairside fabrication

Kits are available for chairside fabrication of the band and loop and distal shoe appliances (Denovo Dental, Inc., Dental Supply Company, A.T. Chairside Space Maintainers). Immediate repair or replacement of the appliance is possible, and performing

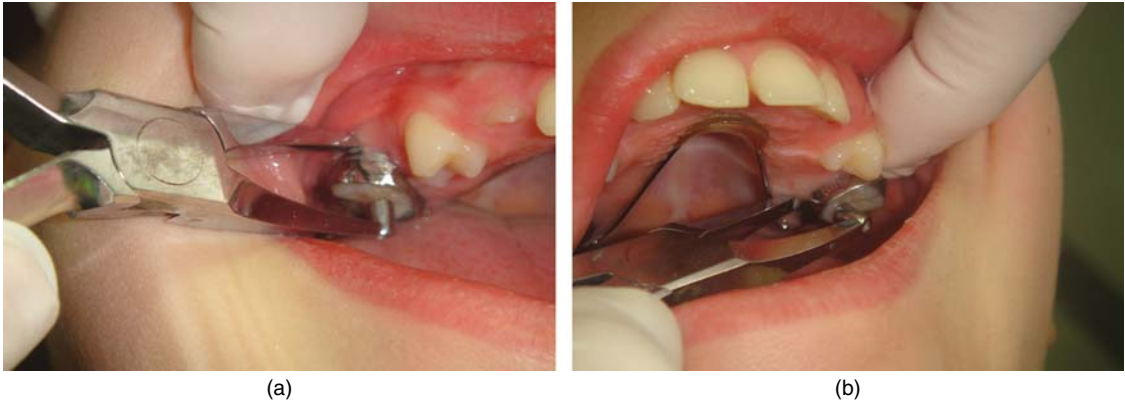

Figure 16.22 (a) Removing band from molar with band remover on buccal surface. (b) Removing band from molar with band remover on palatal surface.



Figure 16.23 Stapler with bent and unbent staples.

fabrication at the time of the extraction eliminates laboratory fees and space loss with possible delay in delivery due to no-show or cancellation (Figure 16.27).

After appliance delivery

Space maintenance requires supervision and parental/guardian compliance. The date of insertion and removal of appliances should be recorded in a designated place for regular review of patients with space maintainers. If the patient is no longer being seen in the practice, and the practice is unable to contact the parent/guardian by

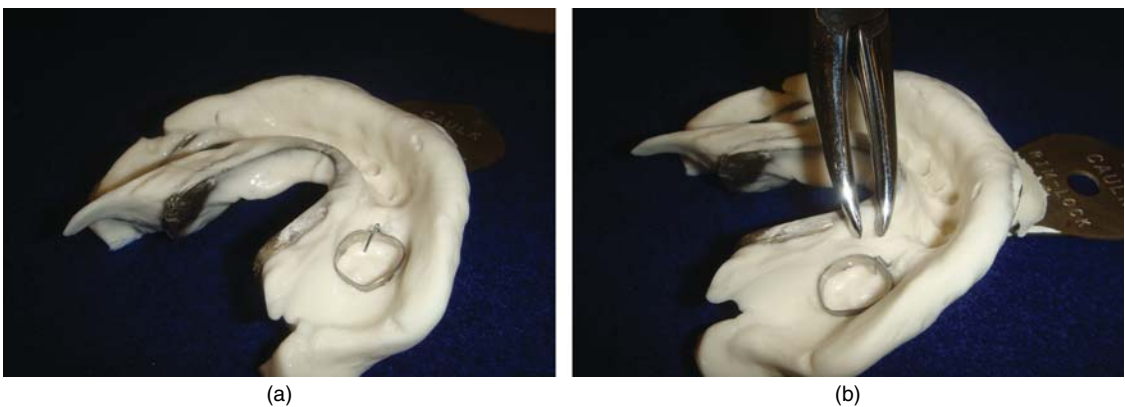

Figure 16.24 (a) Staple to secure band in impression. (b) Howe plier to bend staple over band.

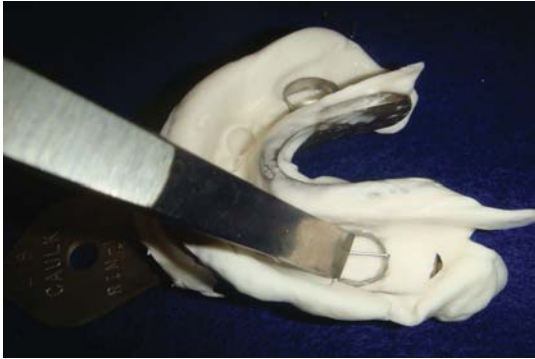

Figure 16.25 Unbent staple over band in impression being secured with opposite end of cotton plier.

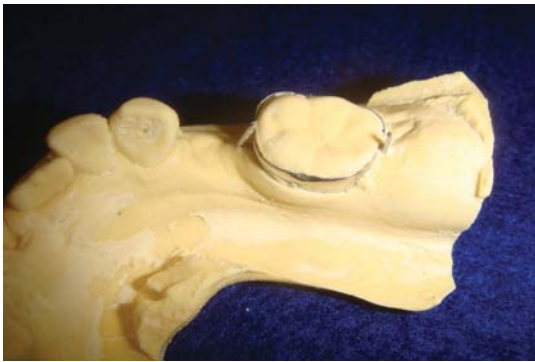

Figure 16.26 Plaster model with banded primary molar and staple to secure band.

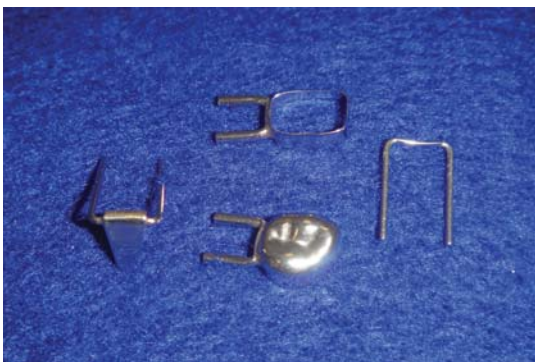

Figure 16.27 Prefabricated space maintainers.

mail, phone, or email regarding the need for evaluation of the status of the space maintainer, a letter sent via certified mail with a return receipt is suggested for legal documentation of this notification. Appliances may

be removed once a year for prophylaxis and fluoride application to insure healthy tooth structure under and around the bands.

Timely and appropriate use of space maintenance or space control will significantly influence the development of favorable arch form and decrease incidence of malocclusion and future costs for orthodontic intervention along with permitting normal eruption of the developing permanent dentition. Parental/guardian compliance with follow-up to monitor space maintainers is mandatory.

References

- American Academy of Pediatric Dentistry (2014a) Guideline on management of the developing dentition and occlusion in pediatric dentistry. *Pediatric Dentistry*, **36** (special issue), 251–263.
- American Academy of Pediatric Dentistry (2014b) Resource section dental growth and development. *Pediatric Dentistry*, **36** (special issue), 371.
- Brill, W.A. (2002) The distal shoe maintainer: chairside fabrication and clinical performance. *Pediatric Dentistry*, **24**, 561–565.
- Dean, J.A. (2012) Bilateral space management in the mixed dentition. In: Moursi, A.M. (ed), *Clinical Cases in Pediatric Dentistry*. Wiley-Blackwell, Oxford, UK, pp. 212–215.
- Fathian, M., Kennedy, D.B. & Nouri, M.R. (2007) Laboratory-made space maintainers: a 7-year retrospective study from private dental practice. *Pediatric Dentistry*, **29**, 500–506.
- Fricker, J., Kharbanda, O.P. & Dando, J. (2008) Orthodontic diagnosis and treatment in the mixed dentition. In: Cameron, A.C. & Widmer, R.P. (eds), *Handbook of Pediatric Dentistry*, 3rd edn. Mosby, London, pp. 341–377.
- Kupietzky, A. (2001) The treatment and long-term management of severe multiple avulsions of primary teeth in a 19-month-old child. *Pediatric Dentistry*, **23**, 517–521.
- Lin, Y.-T., Lin, W.-H. & Lin, Y.-T.J. (2007) Immediate and six-month space changes after premature loss of a primary maxillary first molar. *Journal of the American Dental Association*, **138**, 362–368.
- Simon, T., Nwabueze, I., Oueis, H. *et al.* (2012) Space maintenance in the primary and mixed dentitions. *Journal of the Michigan Dental Association*, **94**, 38–40.
- Terlaji, R.D. & Donly, K.J. (2001) Treatment planning for space maintenance in the primary and mixed dentition. *Journal of Dentistry for Children*, **68**, 109–114.
- Tunison, W., Flores-Mir, C., El Badrawy, H. *et al.* (2008) Dental arch space changes following premature loss of primary first molars: a systematic review. *Pediatric Dentistry*, **30**, 297–302.

Pulpal treatment in young permanent incisors following traumatic injuries

Joe H. Camp

Pulp capping and pulpotomy

Preservation of vitality in young permanent immature teeth is imperative to allow completion of root formation in order to have the strongest root possible. If injury occurs resulting in pulpal necrosis before dentinogenesis is completed, retention of the tooth is compromised by diminished root length and thinness of dentin. The thinner dentinal walls of the root lead to increased root fracture. The decrease in root length results in less root-to-crown ratio and may lead to tooth mobility with resultant loss of attachment apparatus.

In a 4-year study, Cvek (1992) reported significant increase in cervical root fracture in endodontically treated immature teeth. Dependent on the stage of development, fractures ranged from 77% in teeth with the least root development to 28% with the most developed roots (Figures 17.1 and 17.2).

Direct pulp capping (Figure 17.3) and pulpotomy attempt to preserve pulpal vitality by the application of a medicament or dental material to the exposed pulp. Pulpotomy differs from pulp capping only in that additional pulp tissue is removed before placement of the pulp-capping agent. The success rates of these procedures following injury in the young teeth are highly successful (Cvek and Lundberg, 1983; Fuks *et al.*, 1987). While there is much disagreement on these vital procedures versus pulpectomy and root canal filling, there is almost universal agreement these procedures are indicated in teeth with immature apices.

In young fractured teeth with pulp exposure, Cvek (1978) and Cvek and Lundberg (1983) have shown that inflammation and/or infection will be confined to the surface 2–3 mm. The underlying tissue will respond favorably to pulpotomy. Neither the exposure size nor time between injury and treatment up to 90 days is critical for healing when only the superficial layers of pulp are removed. It is usually not necessary or desirable to remove all the coronal pulp tissue. This partial pulpotomy is commonly referred to as a Cvek pulpotomy (Cvek, 1993) (Figures 17.4 and 17.5).

Many medicaments and materials have been used for pulp capping and pulpotomy. Traditionally, calcium hydroxide $\text{Ca}(\text{OH})_2$ has been the most widely used agent of choice (Figure 17.7). However, additional recent research has shown mineral trioxide aggregate (MTA) to be more biologic while producing better results (Abedi *et al.*, 1996; Pitt Ford *et al.*, 1996). MTA has become the agent of choice (Figures 17.6 and 17.7).

Healing is directly related to the capacity of the capping agent and restoration to provide a biologic seal against bacterial leakage while simultaneously forming a dentinal bridge. MTA provides a biologically active substrate to which cells are attached. Calcium released from the MTA reacts with phosphate in the tissue fluid to produce hydroxyapatite (Sarkar *et al.*, 2002).

In the Cvek pulpotomy, only tissue judged to be inflamed is removed. Removal of tissue is accomplished with an abrasive diamond or round carbide bur using high-speed and copious water spray. All fibers of the

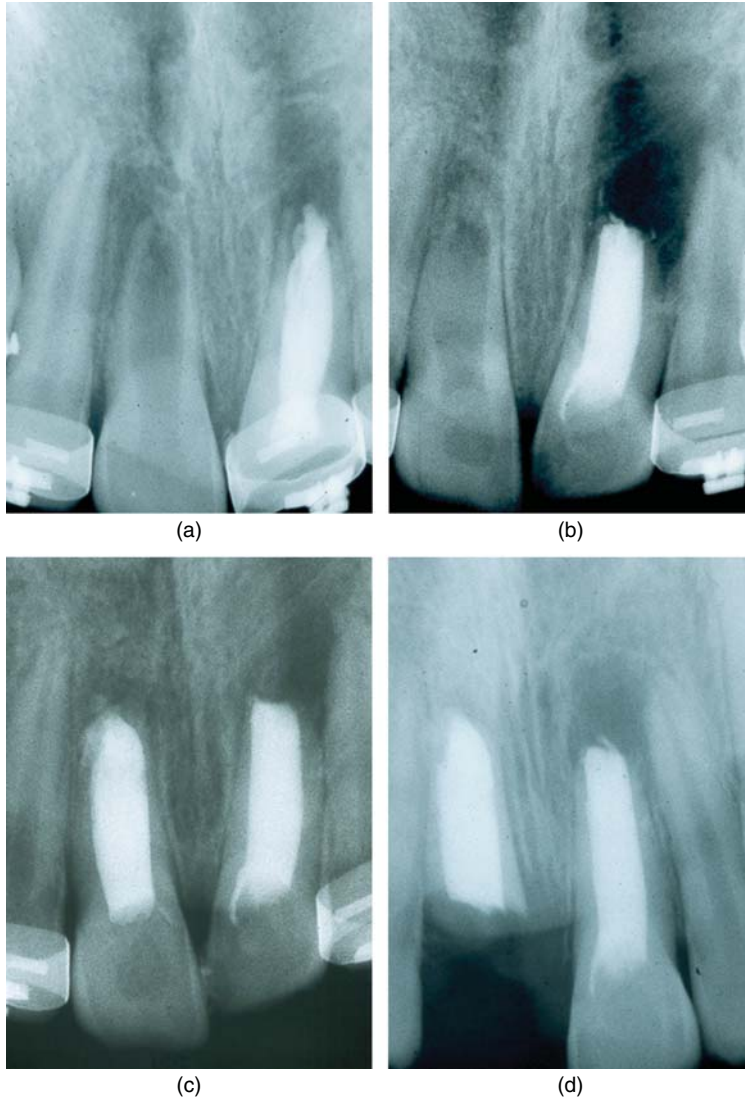


Figure 17.1 Fractured root of the maxillary right central incisor following successful apexification with calcium hydroxide and filling of root canal with guttapercha. (a) Preoperative radiograph. Unsuccessful previous root canal treatment with guttapercha in the left central incisor. (b) Successful apexification of the right incisor. The left incisor has root canal filled with guttapercha followed by an apical curettage. (c) Radiograph at 18 months. The right central has been filled with guttapercha. The lesion at the apex of the left incisor is healing. (d) Fracture of the thin root of the right central incisor 3 months later. The left incisor continues to heal apically.

pulp coronal to the amputation must be removed, otherwise hemorrhage will persist. After tissue removal is completed, the site is washed with sterile water or saline to remove all debris. Blowing air on the pulp is contraindicated because it will cause damage to the tissue from desiccation.

Hemorrhage control is obtained by light pressure on the pulp with a dampened cotton pellet. Hemostasis should be achieved in 1–2 min (Figures 17.4b, 17.4c and 17.5c). If bleeding persists, an additional 1–2 mm of pulpal tissue is removed. Hemostatic agents are contraindicated. A cotton pellet wetted with sodium

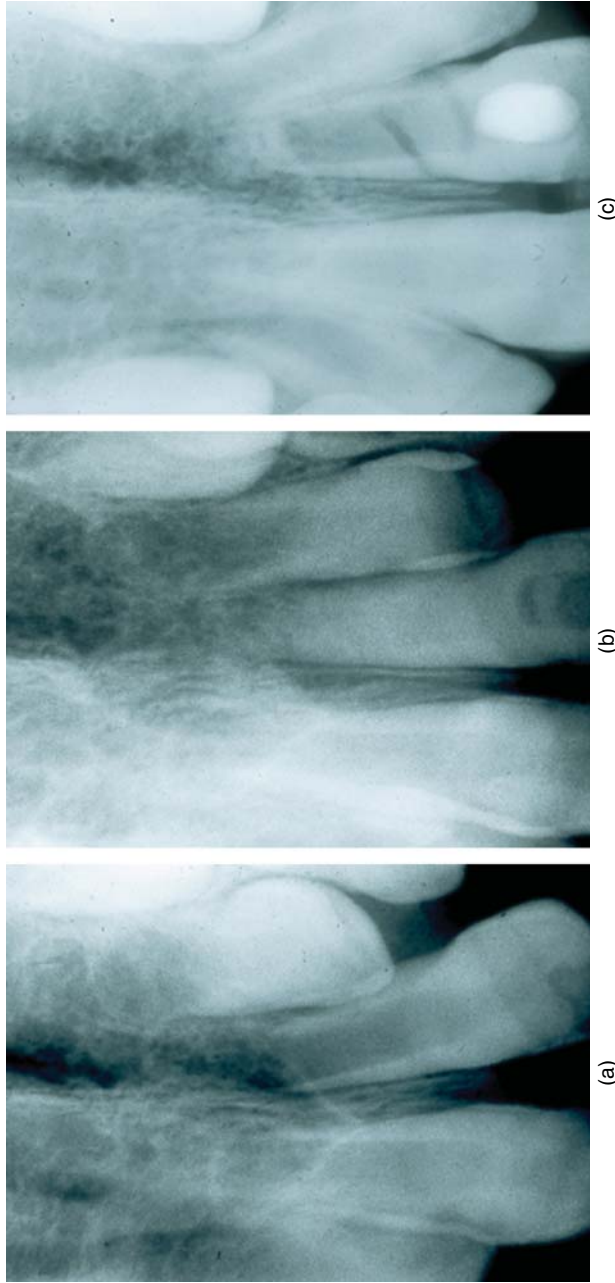

Figure 17.2 Root fracture of maxillary left central incisor while undergoing apexification with calcium hydroxide. (a) Preoperative radiograph of left central incisor with necrotic pulp and incompletely formed root. (b) Canal cleaned and filled with calcium hydroxide. (c) 18-month radiograph. Apexification completed but before the canal is sealed with gutta-percha, another injury results in root fracture and the tooth must be extracted.

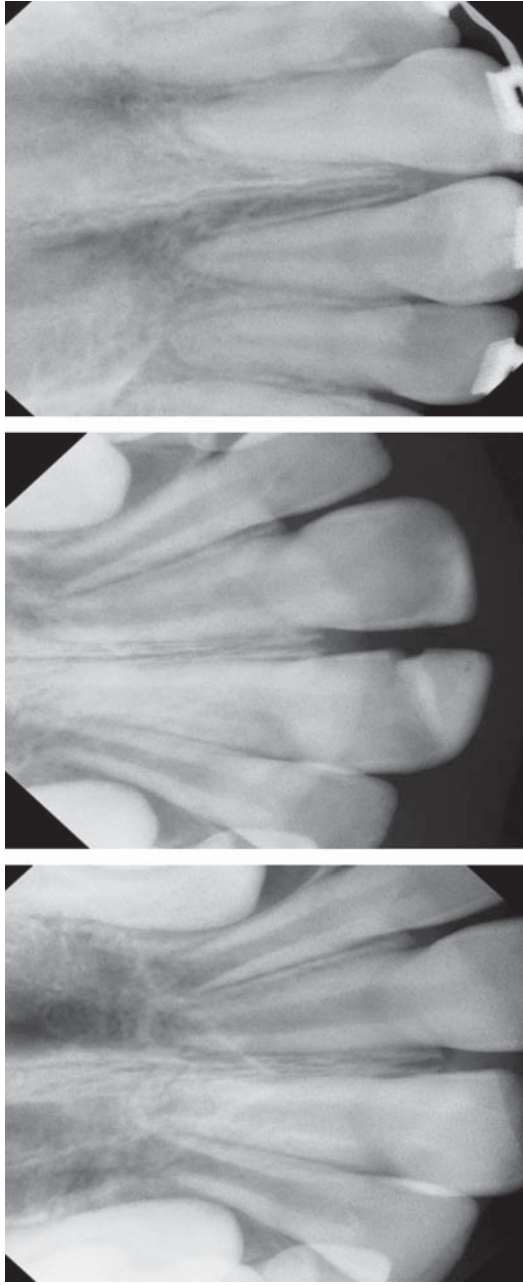


Figure 17.3 Apical closure and root completion following direct pulp capping in maxillary right central incisor. (a) Radiograph of fractured left incisor with pulp exposure. Note the immature roots. (b) Radiograph of MTA pulp capping covered with composite resin. (c) Radiograph 4.5 years after pulp capping showing dentinal bridging and completed root formation.

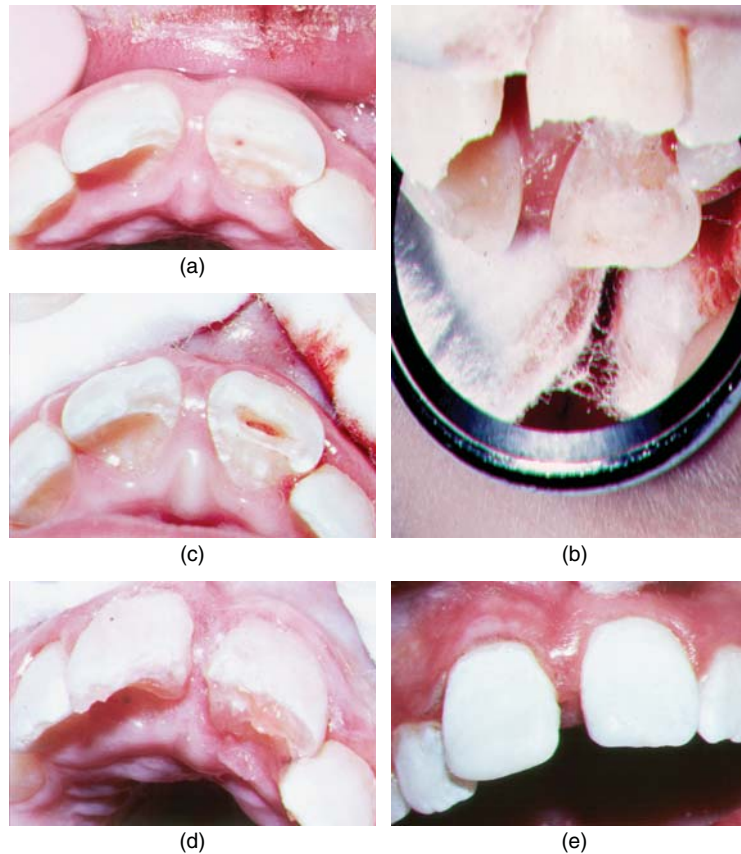


Figure 17.4 Cvek pulpotomy with MTA on a maxillary right central incisor. (a) Clinical appearance of pulp exposure 4 days after injury. The right incisor has a pulp exposure and the left incisor has a minor dentin fracture. (b) Three millimeters of the pulp has been removed with a clean amputation, washed, and a wetted cotton pellet placed against the pulp to control hemorrhage. (c) The amputation site after cotton is removed. Note the lack of hemorrhage. (d) The pulp has been capped with 1.5 mm of white MTA. A thin layer of light-cured composite has been placed over the MTA and cured to protect it during sealing of the tooth. (e) The two central incisors are etched. (f) Sealing of the incisors with bonded composite restorations. A definitive well-contoured restoration will be placed in 8 weeks after healing has occurred.

hypochlorite (NaOCl) may be applied to help in hemorrhage control. The application of NaOCl to pulp tissue is hemostatic but does not cause tissue damage. It does not inhibit pulpal healing, odontoblastic cell formation, or dentinal bridging (Akimoto *et al.*, 1998). Pulp capping will not be successful unless hemorrhage is controlled.

A 1–2-mm layer of MTA is placed directly over the exposure site. Because MTA requires 4–6 h to set, it is covered with a thin layer of flowable light-cured composite resin or glass ionomer. Care should be exercised in covering only the MTA in order to have the maximum surface of dentin and enamel to etch for placement of the permanent restoration.

Research (Tsumimoto, 2013) has demonstrated that placement of resin over wet, unset MTA does not alter the composition, setting, or action of the material. The tooth may then be etched and the final restoration placed.

Apexification and apical plug

Once the pulp has become necrotic, all deposition of dentin ceases. If this occurs before closure of the root, the tooth is left with an open apex and possibly a shortened root. Conventional endodontic procedures cannot be performed.

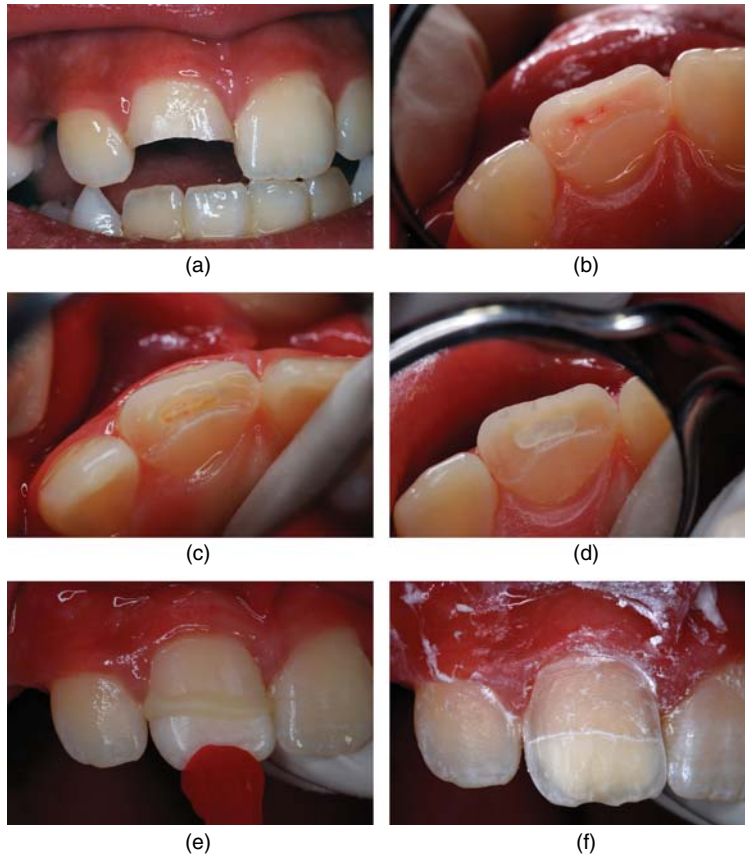


Figure 17.5 Cvek pulpotomy with Ca(OH)_2 and restoration of crown on traumatically injured maxillary central incisor. (a) Facial views of fractured incisor (courtesy of Dr. Ted Croll). (b) Incisal view of tooth revealing pulp exposure (courtesy of Dr. Ted Croll). (c) Pulp chamber after 2 mm diamond bur preparation and hemostasis (courtesy of Dr. Ted Croll). (d) Ca(OH)_2 placed in prepared chamber (courtesy of Dr. Ted Croll). (e) Fractured coronal segment reattached with resin-modified glass-ionomer cement (courtesy of Dr. Ted Croll). (f) Facial enamel preparation for placement of direct bonded resin-based composite veneer. (g) Self-etching resin bonding agent applied (courtesy of Dr. Ted Croll). (h) Restored tooth 26 months immediately following routine prophylaxis (courtesy of Dr. Ted Croll). (i) Two radiographic views of 26 month after Cvek pulpotomy (courtesy of Dr. Ted Croll).

Apexification, generally with Ca(OH)_2 alone or in combination with other drugs to stimulate apical closure was the accepted treatment for many years. Following apical closure with cementum, the canal was filled with guttapercha (Figure 17.1c). Although highly successful, this technique left a root highly susceptible to fracture varying from 28% to 77% after 4 years (Cvek, 1992). The thinner the root dentin, the more likely the root was to fracture (Figures 17.1 and 17.2). Therefore, treatments oriented toward preserving vitality, pulp capping, and pulpotomy should be

attempted if possible. If these conservative treatments fail, more radical endodontic treatments can still be performed.

While apexification with pastes was highly successful, the treatment required 1–2 years to form the apical barrier. Alternative treatments with artificial barriers in the canal to allow immediate obturation of the canal were developed.

The introduction of MTA in 1996 (Tittle *et al.*, 1996) as an apical barrier against which to pack a root filling has become the standard. Subsequent research showed that

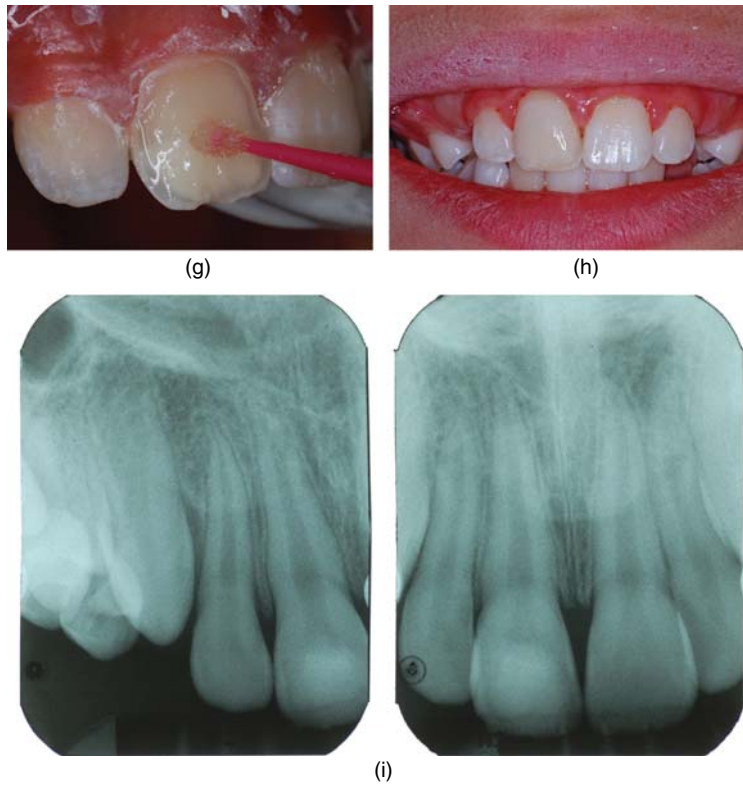


Figure 17.5 (Continued)

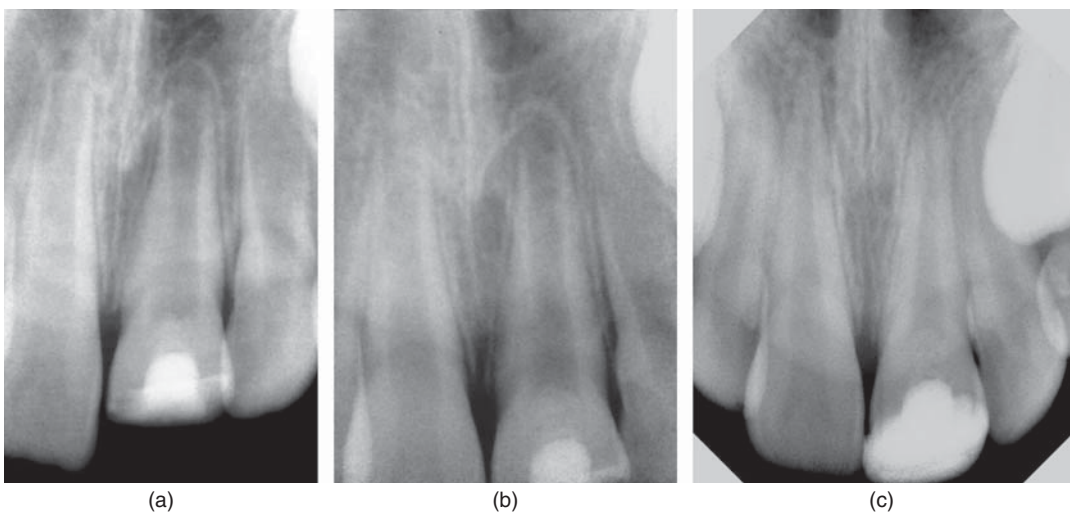


Figure 17.6 Cvek pulpotomy with MTA on a maxillary left central incisor with an open apex. (a) Radiograph 3 months after pulpotomy. Note the dentin bridge. (b) Radiograph 6 months after pulpotomy. The dentin bridge has thickened. (c) Radiograph 3.5 years after Cvek pulpotomy. The root formation is completed and the apex closed. The dentin bridge has thickened but the root is free of abnormal calcification.

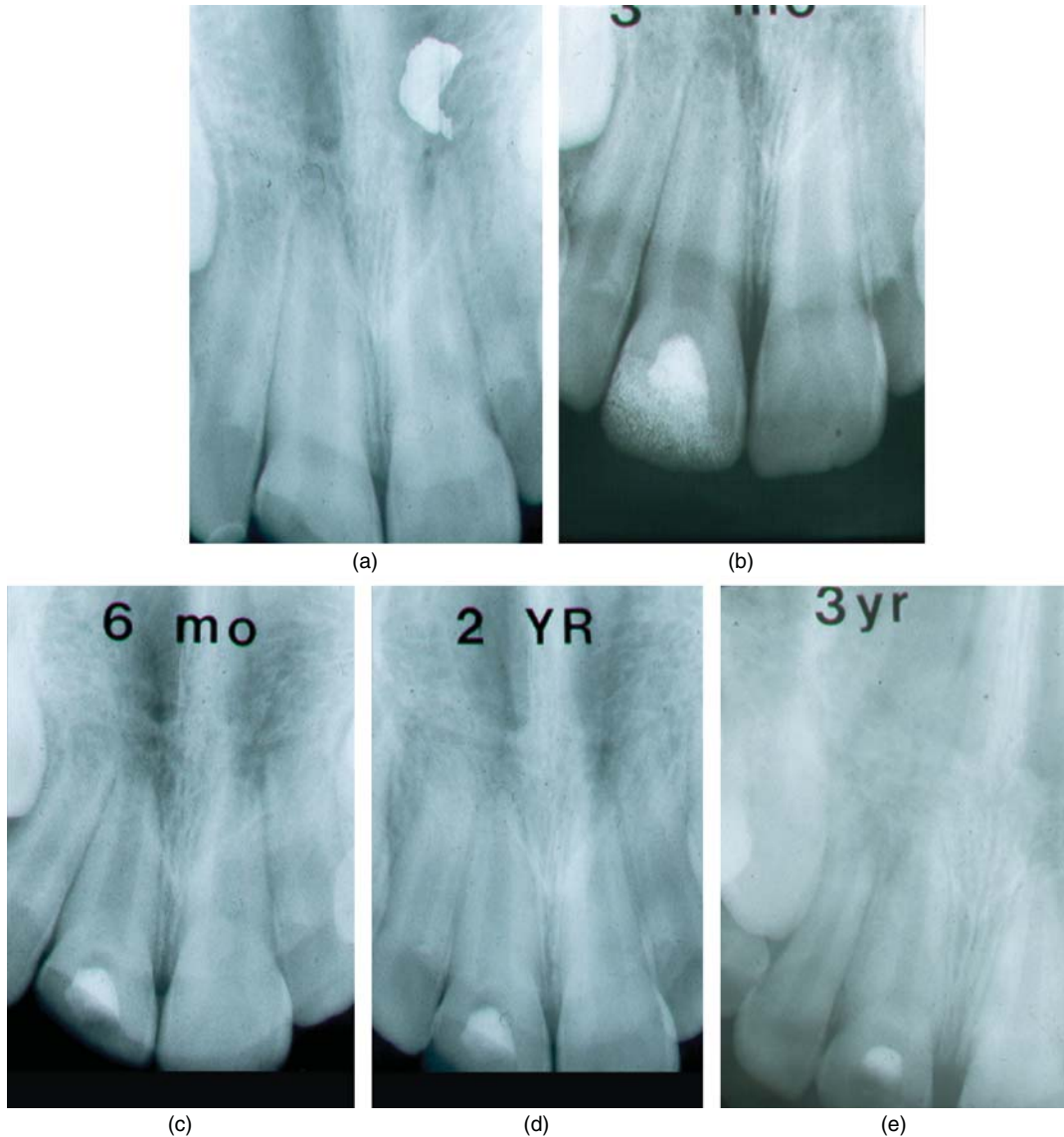


Figure 17.7 Cvek pulpotomy with calcium hydroxide on a maxillary right central incisor with an open apex. (a) Preoperative radiograph of fractured incisor with pulp exposure. (b) Radiograph at 12 weeks showing dentin bridge. (c) Radiograph at 6 months. Note the dentin bridge has not thickened any further. (d) Radiograph at 2 years. Root formation is completed. (e) Radiograph at 3 years. The canal is not calcified.

MTA induced apical hard tissue formation while causing less inflammation than previously used materials (Figures 17.8 and 17.9).

After placement and setting of an apical plug of several millimeters of MTA, the canal can be obturated

(Figure 17.8b). MTA is cementoconductive and stimulates cementogenesis at the apex with cementoblasts attached to the material (Figures 17.8d and 17.9c). Complete closure of the apex creates a biologic seal (Torabinejad *et al.*, 1997).

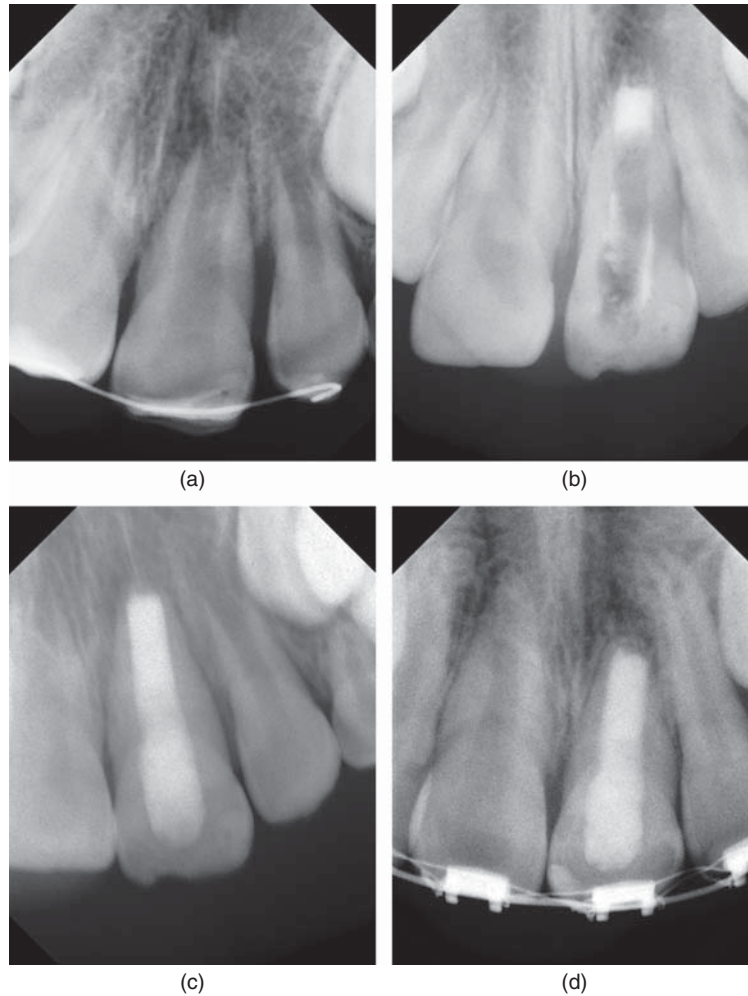


Figure 17.8 Apical plug with MTA. (a) Preop radiograph of immature root, necrotic pulp and periapical lesion. (b) Apical plug of 4 mm MTA. (c) Remainder of canal filled with bonded composite resin. (d) Radiograph at 3.5 years. Complete closure of apex with cementum and healing of periapical lesion. Patient is undergoing orthodontics.

Apical barrier technique with MTA

Following endodontic access, the tooth length is established with radiographs, as apex locators are not reliable in teeth with open apices (Berman & Fleischman, 1984; Hulsman & Pieper, 1989).

The use of the rubber dam is mandatory. The canal is cleansed and disinfected as in any root canal procedure. The use of NaOCl to dissolve necrotic tissue is essential. By using a small diameter needle and keeping the tip 5–6 mm from the apex while injecting slowly, there is no danger of apical extrusion of the liquid.

An acidic pH as occurs with suppuration adversely affects the physical properties and hydration of MTA and weakens its microhardness (Lee *et al.*, 2004). If suppuration is present, the canal must be medicated with Ca(OH)_2 and sealed to allow resolution of the drainage. At a subsequent appointment in several weeks, the canal is reentered and thoroughly cleansed of the Ca(OH)_2 medication before placing the apical plug of MTA as described in the following section.

Once the canal is thoroughly cleansed and disinfected, it may be dried with paper points and the apical plug of

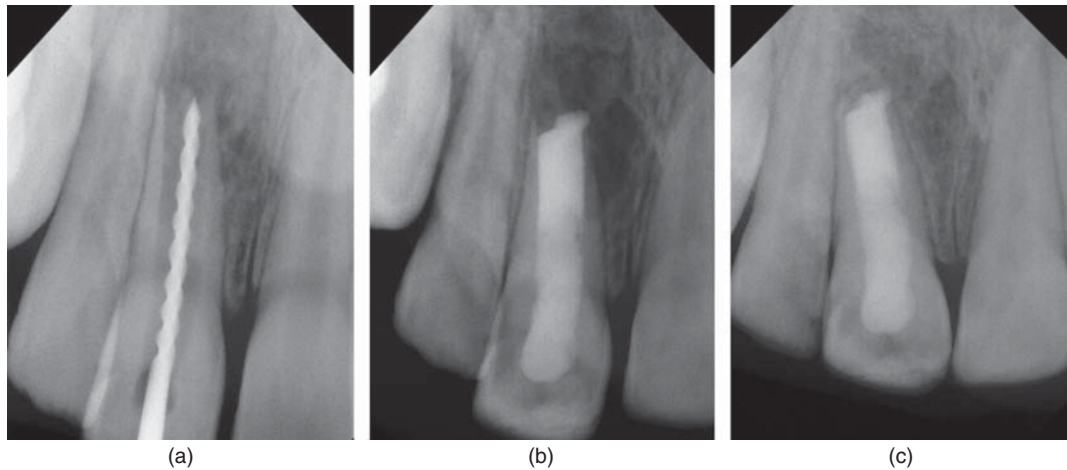


Figure 17.9 Apical plug with MTA. (a) Radiograph at time of treatment with endodontic file in canal to establish tooth length. Immature root with large periapical lesion. (b) Apical plug of MTA and remainder of canal bonded with composite resin. (c) Radiograph at 2.25 years. Apical lesion is healed and apex closed with cementum.

MTA placed. Placement of the MTA in the pulp chamber is easily done with the small end of an amalgam carrier. The MTA is carefully packed to the apex with *measured* pluggers. Care must be taken if using metal blunt-ended pluggers to prevent overfill. While care is exercised to avoid an overfill of MTA, overfills are not a disaster and do not have to be removed surgically as MTA is osteogenic. Any overfill will stimulate osteogenesis and will become encased in bone (Figure 17.10).

The author has found the use of a very large paper point turned in reverse makes an effective plugger for condensation. Small increments are placed in the chamber and condensed to the apex. As the end of the paper point becomes softened by moisture, it is discarded and a new one used. Small increments are easily condensed, whereas large amounts will block the canal and prevent condensation. Depth control is monitored by radiographs.

Placement of large amounts of MTA may lead to blockage of the canal before the material reaches the proper depth. Small increments of MTA can be achieved by filling the small end of an amalgam carrier, then partially extruding and removing part of the MTA plug before placing the remainder in the canal. If the canal becomes clogged with MTA before reaching the proper depth at the apex, the mass is easily loosened with a large endodontic reamer or file. If this happens, it may

be necessary to remove a portion of the MTA from the canal and then continue condensation (Figure 17.11).

A 4-mm plug of MTA has been shown to be significantly more effective than lesser amounts in preventing dye leakage (Valois, 2004). Therefore, the apical 4 mm is filled with the plug of MTA (Figure 17.8b). The entire canal is not filled with MTA, as a bonded composite will be placed in the remainder of the canal as described later to strengthen the root.

All excess MTA is removed from the canal walls. To remove the residue of MTA on the lateral walls of the root, the canal can be scrubbed with large damp paper points or the cotton-tipped applicators used to apply bonding agents in the composite technique. This is done so the remainder of the canal can be strengthened with composite resin bonded to the dentinal walls.

Once the canal is cleaned of excess MTA and the apical plug determined by radiograph to be satisfactory, a wetted cotton pellet is placed in the canal until the MTA sets. The cotton pellet is pulled away from the MTA, so cotton fibers will not be incorporated into the material as it sets. Other dry pellets are placed in the chamber and the coronal access is sealed with temporary cement such as IRM or Cavit. This must be left for a minimum of 6 h as the MTA sets.

Another appointment is made to complete bonding of the remainder of the canal to strengthen the root.

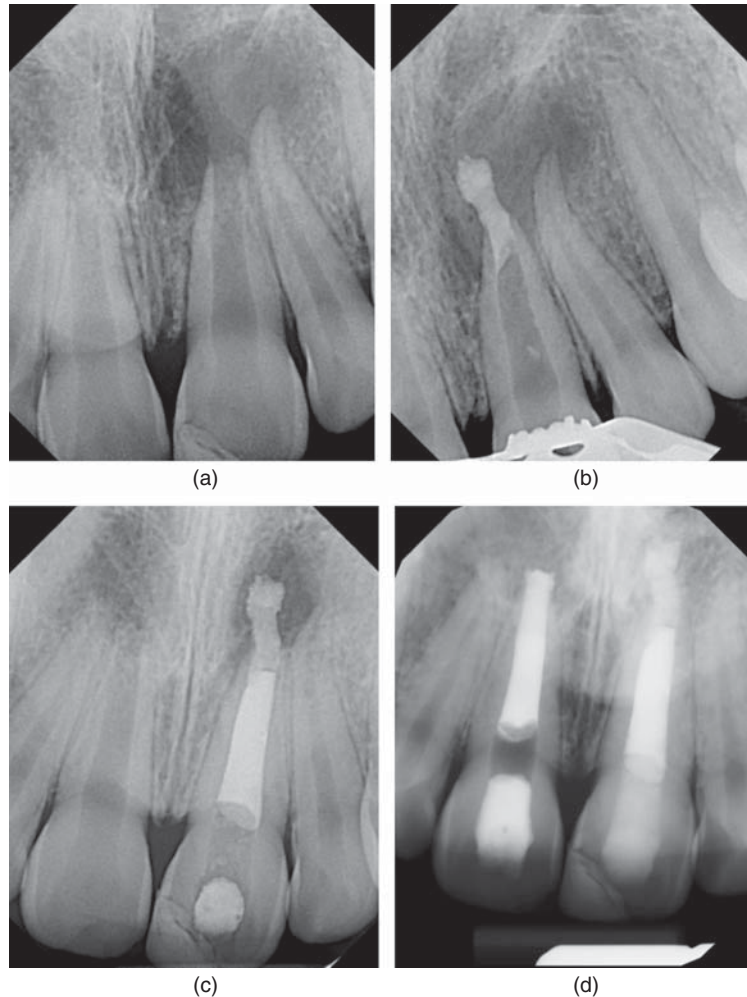


Figure 17.10 Healing of a gross overfill of MTA in an immature maxillary left central incisor. (a) Preop radiograph of central incisor with open apex and large periapical lesion. (b) Radiograph of accidental gross overfill of MTA while placing the apical plug. (c) Lesion on left central is healing, and canal has been filled with guttapercha incisal to the MTA plug. The right central incisor has developed an apical lesion. (d) Radiograph of central incisors at 3 years. The apical lesion on the left central incisor with MTA overfill is completely healed with the overfill surrounded by bone. The right central incisor has been filled with guttapercha and is healing.

Strengthening the root

The MTA is allowed to set for a minimum of 6 h. When the patient returns, the tooth is reentered and all the temporary cement and cotton pellets are removed. Verification of set of the MTA is done by probing against it with an endodontic file. The canal is thoroughly irrigated and dried with paper points. An acid etch gel is placed in the canal to etch the dentinal walls. After thoroughly rinsing and drying, a bonding agent is placed on

the dentinal walls and cured. It is not necessary to avoid contact of the MTA with the acid-etchant or the bonding agent, as it causes no deleterious affects to the apical plug (Tsujimoto, 2013).

The canal is then filled incrementally with 2-mm layers of any microfilled condensable composite (Figure 17.8c). Radiographic examination of the first increment of composite will help to avoid voids in the canal filling. The small amount of condensable composite is packed into place with blunt-ended pluggers or large paper points

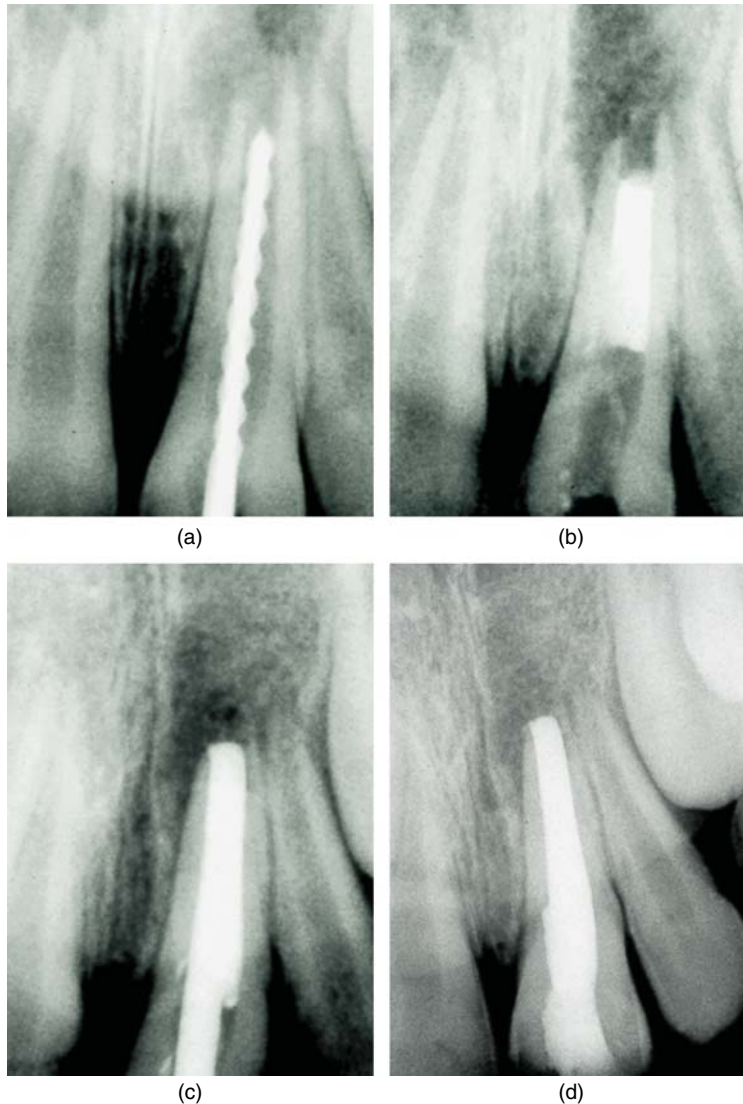

Figure 17.11 Reworking of apical plug of MTA short of correct length. (a) Radiograph of maxillary central incisor with open apex. Endodontic file in place to determine tooth length. (b) Radiograph showing MTA plug canal short of proper depth. The MTA is loosened with a large endodontic file and condensed to the proper depth. (c) MTA plug condensed to proper depth and remainder of canal being filled with guttapercha. (d) Radiograph 1 year later. The apical lesion is nearly healed.

reversed to use the larger end. Each increment of 2 mm of composite is cured. Curing times are four times the recommended curing time for the curing light to assure complete set of the composite. The light easily reaches the composite owing to the large access and the large canal.

The first increment of composite is the most difficult to place without a void. Once the first increment is placed,

a radiograph is recommended to ascertain that it is in contact with the MTA and has no voids. If this is not the case, it should be removed and a new increment placed and re-X-rayed. Once the first composite is cured in place, it is rare to have a void in the other increments. The canal should *not* be filled with a self-curing flowable composite, as voids will definitely be trapped. Also, the large volume of composite will shrink away from the

dentinal walls as polymerization occurs. The increments of condensable composite should fill only 2 mm to avoid shrinkage of the material. The material is placed in the tooth and cured until the root canal, pulp chamber, and access opening are obliterated (Figures 17.8c and 17.9b). Unless part of the crown is missing, this is the permanent restoration of the tooth.

Research (Hernandez *et al.*, 1994; Katebzadeh *et al.*, 1998) has shown that the use of newer dentinal bonding techniques will strengthen endodontically treated teeth to levels close to that of intact teeth. Utilization of this technique has virtually eliminated root fractures in these immature roots.

Regenerative endodontics

Reports of nonvital immature teeth with open apices and suppuration have demonstrated ingrowth of pulp-like tissue and complete root formation, both in length and thickness of dentin, after treatment with a triple antibiotic paste (Iwaya *et al.*, 2001; Banchs & Trope, 2004).

The root canal is endodontically accessed and disinfected with copious irrigation with full strength NaOCl for 10–15 min. No instrumentation is performed on the canal. After carefully drying the canal, a paste of ciproflaxin, metronidazole, and minocycline is mixed and placed in the canal. A paper point or lentulo spiral can be used to place the paste. The canal is sealed with a temporary filling.

The paste is left in place several weeks. The canal is reentered and the antibiotic paste is washed out with NaOCl and dried. The periapical tissues are instrumented with endodontic files through the apex to create hemorrhage into the canal. After the canal becomes filled with blood, it is allowed to clot.

The clot is carefully removed to the cervical line. The remaining clot is covered with several millimeters of MTA and the tooth closed with a temporary filling. After hardening of the MTA, the tooth is permanently sealed with a resin-bonded composite.

The clot serves as a scaffold for pulp regeneration. Over a period of 1–2 years, calcified tissue resembling dentin radiographically is deposited in the canal and is contiguous with the dentinal walls.

Minocycline stains dentin green. Clindamycin has been shown to be an acceptable substitute for minocycline. Therefore, clindamycin should be used as a

substitute for minocycline to prevent staining of the dentin (McTigue *et al.*, 2013).

References

- Abedi, H.R., Torabinejad, M., Pitt Ford, T.R. *et al.* (1996) The use of mineral trioxide aggregate cement (MTA) as a direct pulp-capping agent. *Journal of Endodontics*, **22**, 199. (abstract)
- Akimoto, N., Momoi, Y., Kohno, A. *et al.* (1998) Biocompatibility of clearfil linear bond 2 and clearfil AP-X system to non-exposed and exposed primate teeth. *Quintessence International*, **29**, 177–188.
- Banchs, F. & Trope, M. (2004) Revascularization of immature permanent teeth with apical periodontitis: new treatment protocol? *Journal of Endodontics*, **30**, 196–200.
- Berman, L.H. & Fleischman, S.B. (1984) Evaluation of the accuracy of the neosono-D electronic apex locator. *Journal of Endodontics*, **10**, 164–167.
- Cvek, M. (1978) A clinical report on partial pulpotomy and capping with calcium hydroxide in permanent incisors with complicated crown fractures. *Journal of Endodontics*, **4**, 232–237.
- Cvek, M. (1992) Prognosis of luxated non-vital maxillary incisors treated with calcium hydroxide and filled with guttapercha. A retrospective clinical study. *Endodontics and Dental Traumatology*, **8**, 45–55.
- Cvek, M. (1993) Results after partial pulpotomy in crown fractured teeth 3–15 years after treatment. *Acta Stomatol Croat*, **27**, 167–173.
- Cvek, M. & Lundberg, M. (1983) Histological appearance of pulps after exposure by a crown fracture, partial pulpotomy, and clinical diagnosis of healing. *Journal of Endodontics*, **9**, 8–11.
- Fuks, A.B., Chosack, A., Klein, H. *et al.* (1987) Partial pulpotomy as a treatment alternative for exposed pulps in crown-fractured permanent incisors. *Endodontics and Dental Traumatology*, **3**, 100–102.
- Hernandez, R., Bader, S., Boston, D. *et al.* (1994) Resistance to fracture of endodontically treated premolars restored with new generation dentin bonding systems. *International Endodontic Journal*, **27**, 281–284.
- Hulsman, M. & Pieper, K. (1989) Use of an electronic apex locator in the treatment of teeth with incomplete root formation. *Endodontics and Dental Traumatology*, **5**, 238–241.
- Iwaya, S., Ikawa, M. & Kubata, M. (2001) Revascularization of an immature permanent tooth with apical periodontitis and sinus tract. *Dental Traumatology*, **17**, 185–187.
- Katebzadeh, N., Dalton, B.C. & Trope, M. (1998) Strengthening immature teeth during and after apexification. *Journal of Endodontics*, **24**, 256–259.
- Lee, Y.L., Lee, B.S., Lin, F.H. *et al.* (2004) Effects of physiological environments on the hydration behavior of mineral trioxide aggregate. *Biomaterials*, **25**, 787–793.

- McTigue, D.J., Subramanian, K. & Kumar, A. (2013) Management of immature permanent teeth with pulpal necrosis: a case series. *J Pediatr Dent*, **35**, 55–60.
- Pitt Ford, T.R., Torabinejad, M. & Abedi, H.R. (1996) Mineral trioxide aggregate as a pulp-capping material. *Journal of the American Dental Association*, **127**, 1491–1494.
- Sarkar, N.K., Saunderi, B., Moiseyevai, R. *et al.* (2002) Interaction of mineral trioxide aggregate (MTA) with a synthetic tissue fluid. *Journal of Dental Research*, **81**, A-391., (abstract # 3155)
- Tittle, K.W., Farley, J., Linkhardt, M. *et al.* (1996) Apical closure induction using bone growth factors and mineral trioxide aggregate. *Journal of Endodontics*, **22**, 1998., (abstract #41)
- Torabinejad, M., Pitt, F.T., McKendry, D. *et al.* (1997) Histological assessment of mineral trioxide aggregate as a root-end filling in monkeys. *Journal of Endodontics*, **23**, 225–228.
- Tsujimoto, M., Tsujimoto, Y., Ookuba, A. *et al.* (2013) Timing for composite resin placement on mineral trioxide aggregate. *Journal of Endodontics*, **39**, 1167–1170.
- Valois, C.R., Costa, E.D. (2004) Influence of the thickness of mineral trioxide aggregate on sealing ability of root-end fillings in vitro. *Oral Surg Oral Pathol Oral Radiol Endod*, **97**, 180–111.

Reattachment of permanent incisor enamel fragments

Jane A. Soxman

Indications

Reattachment of an intact enamel fragment for both uncomplicated and complicated crown fracture provides a restoration that is less expensive, rapid, and esthetic with an identical match in original shape, occlusal alignment, natural translucency, surface finish, and unique coloration. This is considered to be interim treatment that does not preclude any future treatment, as no tooth structure is removed or modified. Fracture of permanent incisors is more likely to occur with incompetent lip posture and significant overjet (Bauss *et al.*, 2008; Schatz *et al.*, 2013). Anticipatory guidance is recommended to prepare the patient and parents/guardian for this event (Figure 18.1).

After an incisor fracture, the enamel fragment should be immediately located and stored in water or a damp paper towel to avoid desiccation, resulting in an opaque appearance and poor bonding (Sharmin & Thomas, 2013) (Figure 18.2). If a lip laceration has simultaneously occurred, the laceration should first be explored for the fragment (Figure 18.3). A lower occlusal radiograph may be obtained to rule out presence of the fragment in the lip.

Procedure

Occlusal, periapical, and eccentric shift shots of the fractured incisor may be obtained to evaluate for root fracture or displacement. The use of local anesthesia should not be necessary for reattachment. The fragment may be reattached with both uncomplicated and

complicated fractures. If the fracture has resulted in a borderline pulp exposure, a pulp capping agent, such as calcium hydroxide compounds or white mineral trioxide aggregate (MTA), should be applied, followed by glass ionomer before bonding. A pulpal exposure with a complicated fracture, seen within hours of the exposure and where complete hemostasis is achieved, may be treated conservatively with pulp capping. However, partial pulpotomy generally improves prognosis. If complete hemostasis cannot be achieved or more time has passed, a partial pulpotomy should be performed before reattachment.

If pulp capping with calcium hydroxide followed by glass ionomer is performed, bonding the fragment may no longer be possible due to the layers of material on the incisor now impeding the “fit” between the fragment and incisor. A trough could be prepped in the fragment to accommodate the capping agent and glass ionomer, but the reattachment is compromised. Ultimately, in this case, a composite restoration will most likely be required.

Successful reattachment using only a bonding agent has been reported (Martos *et al.*, 2012; Giudice *et al.*, 2012). Andreasen *et al.* (1993) reported that reattachment with a bonding resin provides only half the original strength of the intact tooth. Bonding with flowable composite and composite resin has been successfully performed, providing from 2–7 years of function.

A fracture sloping to the cervical enhances the bond with increased area for bonding (Figure 18.4). The use of an anterior Parkell dry-field mouth prop greatly facilitates the procedure (Figure 18.5). The incisor and

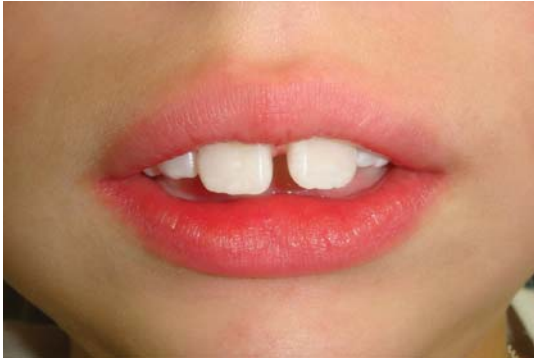

Figure 18.1 Incompetent lip posture with significant overjet.

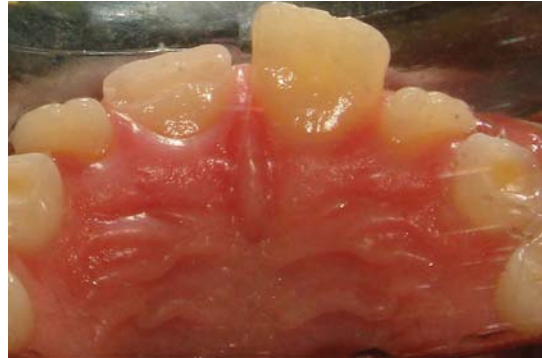

Figure 18.4 Fracture sloping to cervical.

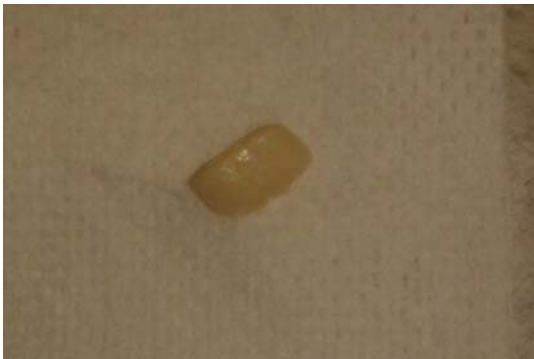

Figure 18.2 Enamel fragment.

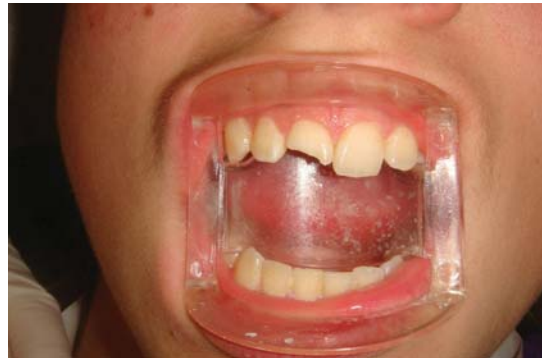

Figure 18.5 Parkell dry-field mouth prop.

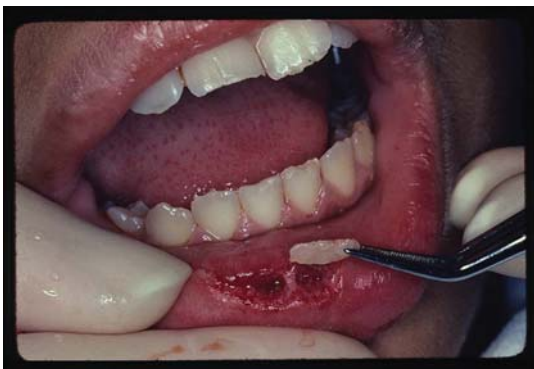

Figure 18.3 Enamel fragment being removed from lower lip laceration.

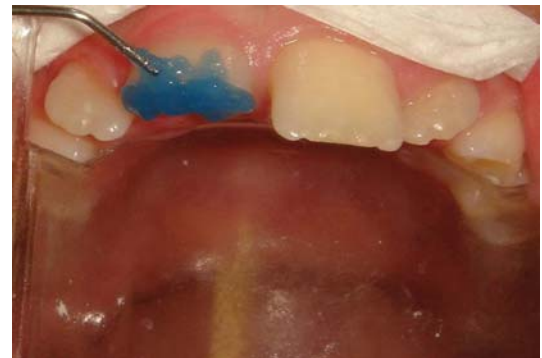

Figure 18.6 Phosphoric acid applied to central incisor.

enamel fragment are individually decontaminated with 0.2% chlorhexidine, conventionally etched with 37% phosphoric acid and thoroughly rinsed with water (Figures 18.6–18.8, and 18.9). The use of a bevel or other preparation does not enhance the retention of

the fragment (Giudice *et al.*, 2012). A bonding agent is applied to both the incisor and the fragment and light cured (Figures 18.10 and 18.11). A thin layer of composite resin may be applied to either or both the incisor and the fragment for enhanced retention

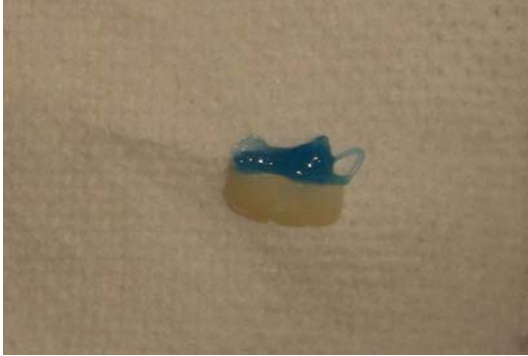

Figure 18.7 Phosphoric acid applied to fragment.

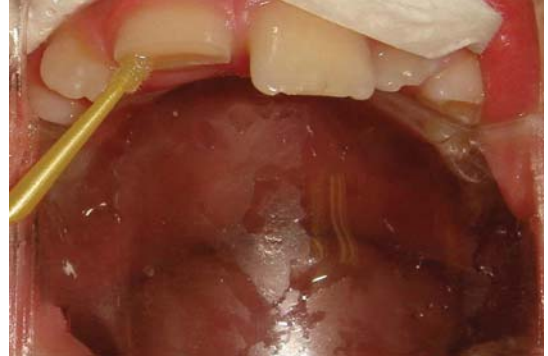

Figure 18.10 Bonding agent applied to central incisor.

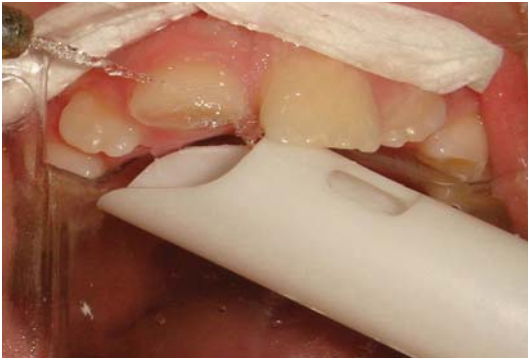

Figure 18.8 Central incisor rinsed.

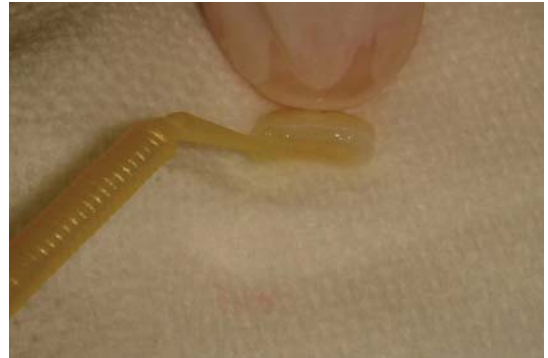

Figure 18.11 Bonding agent applied to fragment.




Figure 18.9 Fragment rinsed.

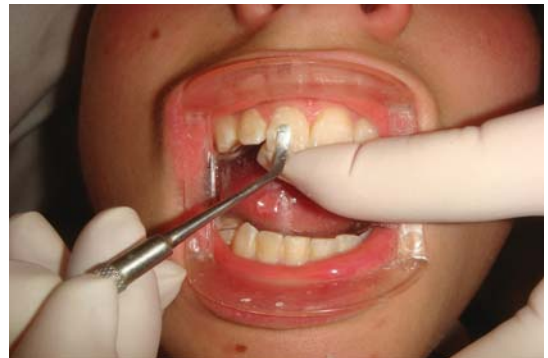

Figure 18.12 Excess composite removed with flat instrument.

(Cameron *et al.*, 2008). After matching the fragment to the coronal portion of the tooth, a flat instrument may be used to remove any excess composite from the facial and lingual surfaces (Figure 18.12). The bonded fragment is light cured on the facial and lingual surfaces.

The incisor is rapidly restored without discomfort and with an excellent esthetic result (Figure 18.13).

Reattachment of mandibular incisor enamel fragments may present a challenge due to their small size (Figure 18.14). The use of a holder with an adhesive

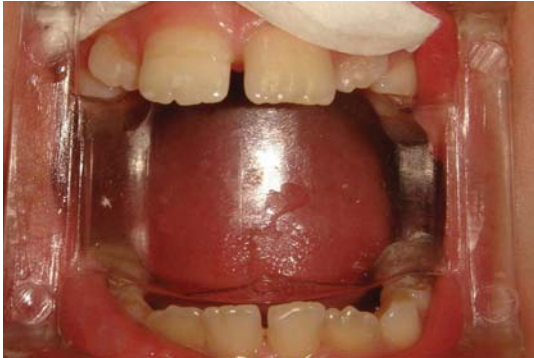

Figure 18.13 Fragment reattached to maxillary central incisor.

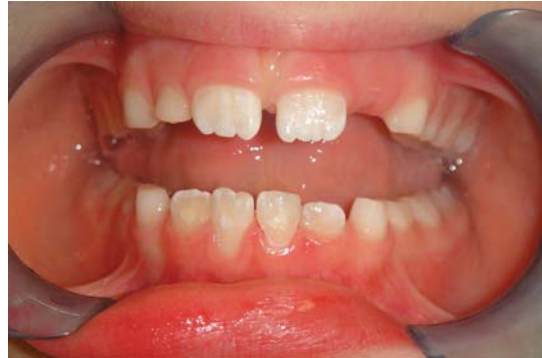

Figure 18.16 Fragment reattached to mandibular central incisor.

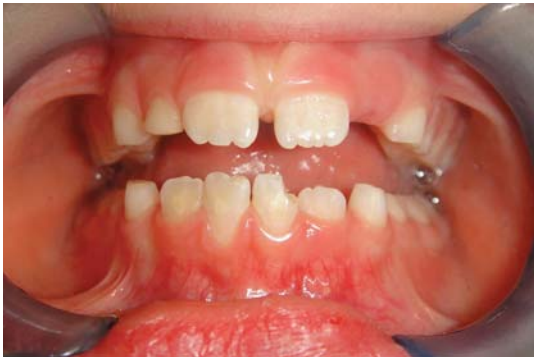

Figure 18.14 Class II fracture mandibular central incisor.

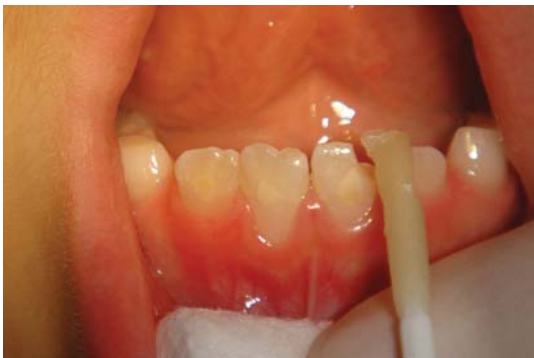

Figure 18.15 Pic-n-Stic carrying enamel fragment.

tip (Pic-n-Stic Pulpdent Corp.) (Figure 18.15) rope or sticky wax facilitates carrying the fragment to the incisor (Figure 18.16).

Repeated trauma and nonphysiologic use of the incisor are the primary reasons for fragment failure

(Macedo & Ritter, 2009). The patient is advised not to incise hard foods, not to bite his or her fingernails, and to notify the dentist for thermal discomfort, masticatory pain, or discoloration. Follow-up for evaluation of pulp vitality, along with periapical radiographs in 6–8 weeks and in 1 year is recommended (Cameron *et al.*, 2008). If orthodontic treatment is in progress or anticipated in the future, the orthodontist should be informed of the traumatic incident and the periapical radiographs shared. Orthodontic movement post-traumatic injury may result in pulpal changes; patient/parents/guardians should be informed of this possibility. A current periapical radiograph to evaluate radicular pathology or health should be obtained before commencing orthodontic movement. Parents/guardians should be informed that the bonded enamel fragment can separate from the tooth during removal of the orthodontic bracket at completion of orthodontic treatment.

References

- Andreasen, F.M., Steinhardt, U., Bille, M. *et al.* (1993) Bonding of enamel-dentin crown fragments after crown fracture. An experimental study using bonding agents. *Dental Traumatology*, **9**, 111–114.
- Bauss, O., Freitag, S., Rohling, J. *et al.* (2008) Influence of overjet and lip coverage on the prevalence and severity of incisor trauma. *Journal of Orofacial Orthopedics*, **69**, 402–410.
- Cameron, A., Widmer, R., Abbott, P. *et al.* (2008) Trauma management. In: Cameron, A.C. & Widmer, R.P. (eds), *Handbook of Pediatric Dentistry*, 3rd edn. Mosby, London, pp. 115–167.
- Giudice, G.L., Lapari, F., Lizio, A. *et al.* (2012) Tooth fragment reattachment technique on a pluri traumatized tooth. *Journal of Conservative Dentistry*, **5**, 80–83.

- Macedo, G.V. & Ritter, A.V. (2009) Essentials of rebonding tooth fragments for the best functional and esthetic outcomes. *Pediatric Dentistry*, **31**, 110–116.
- Martos, J., Koller, C.D., Silveira, L.F.M. *et al.* (2012) Crown fragment reattachment in anterior-fractured tooth: a five-year follow-up. *European Journal of General Dentistry*, **1**, 112–115.
- Schatz, J.-P., Hakeberg, M., Ostini, E. *et al.* (2013) Prevalence of traumatic injuries to permanent dentition and its association with overjet in a Swiss child population. *Dental Traumatology*, **29**, 110–114.
- Sharmin, D.D. & Thomas, E. (2013) Evaluation of the effect of storage medium on fragment reattachment. *Dental Traumatology*, **27**, 99–102.

19

Non-nutritive sucking and parafunctional habits

Jane A. Soxman

Prolonged pacifier and finger/thumb sucking have detrimental effects on both dentoalveolar and facial development. Protracted pacifier habits most often result in anterior open bite and bilateral Class II malocclusion, while protracted thumb and finger habits result in anterior open bite (Warren *et al.*, 2005). Frequency, intensity, and duration of the forces are considerations. Duration is considered to be most influential in the development of increased overjet, anterior open bite, and posterior crossbite. The use of pacifiers beyond the second or third year of life may result in a malocclusion that requires future orthodontic intervention. Thumb or finger sucking should be discontinued at the time of the eruption of the maxillary permanent incisors. Timely discontinuation or modification of non-nutritive sucking may prevent or significantly reduce malocclusion (American Academy of Pediatric Dentistry, 2014; Warren *et al.*, 2001; Warren *et al.*, 2005).

Pacifier habits

Parents/guardians are often unaware of the dramatic effects of prolonged pacifier use in the primary dentition (Figure 19.1). Both conventional and physiologic pacifiers have been shown to cause alterations in the dental arches and occlusion (Zardetto *et al.*, 2002). A typodont of the primary dentition is helpful to demonstrate normal occlusion (Figure 19.2). Two-year-old children may sit on the parent/guardian's lap for examination. The

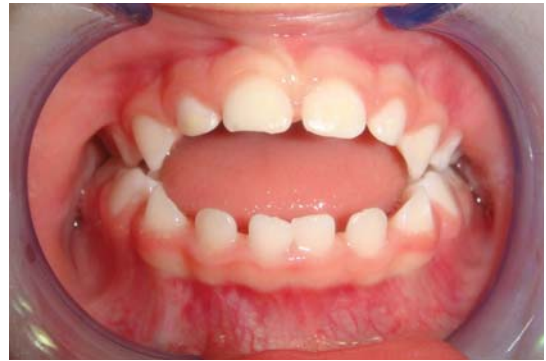

Figure 19.1 Anterior open bite with palatal constriction.

examiner offers a large mirror to the parent/guardian, places the child's teeth in centric occlusion, and retracts the lips to reveal the open bite and posterior crossbite (Figure 19.3). This visualization is typically astonishing to the parent/guardian and all that is necessary for immediate cessation of the habit.

Piercing or trimming the pacifier nipple shorter, dipping the nipple in white vinegar or immediate cessation, "cold turkey" may be recommended. A sippy cup containing water may be offered as an alternative. Rocking, singing, or reading to the child at bedtime may be suggested as a substitute for the pacifier (Adair, 2003). Cessation of a pacifier habit at the age of 2 years satisfies the early physical and psychological needs for sucking while minimizing the risk for malocclusion (Warren *et al.*, 2001). Resolution of malocclusion may

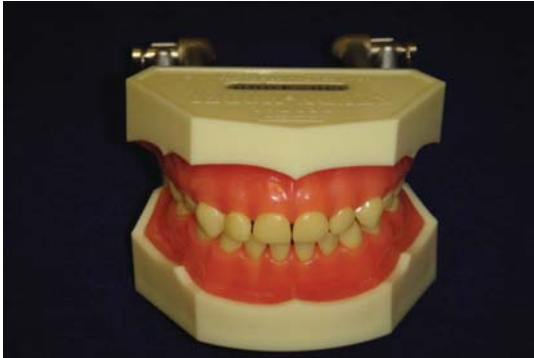

Figure 19.2 Typodont primary dentition Kilgore International.

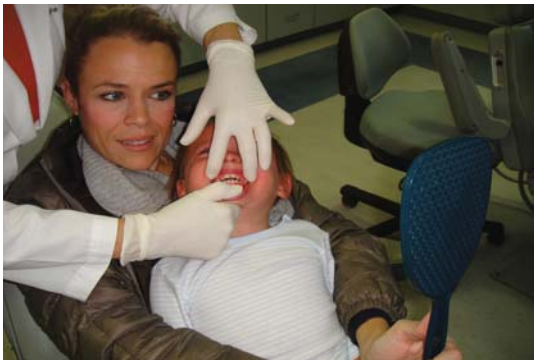

Figure 19.3 Showing occlusion to parent/guardian with hand mirror.

spontaneously occur in 6 months to 1 year with discontinuation of the pacifier under age 3 years. (Figure 19.4a and 19.4b) (Soxman, 2007). In the presence of accompanying crossbite, the open bite may resolve, but existing palatal constriction may or may not resolve without future palatal expansion (Figure 19.4c and 19.4d).

The Lily™ Pacifier Weaning System is proven to stop the pacifier habit in as few as 5 days. This patented system, which has passed all federal safety regulations, has five different nipples, with each nipple smaller and less satisfying than its predecessor (Figure 19.4e).

The mid palatal suture has not yet fused in a young child. The pressure exerted by the buccinator muscles on the maxillary primary molars during sucking causes palatal constriction. With the reduction in the width of the maxilla, the maxillary primary canines prematurely occlude with the mandibular canines, resulting in a functional crossbite (Figure 19.5a and 19.5b).

The need for future crossbite correction with continuation of the habit is discussed, along with the need for immediate habit cessation (Soxman, 2007). The canine interference can be painlessly corrected with a cooperative child. A coarse diamond bur is used for incisal reduction of the right and left maxillary and mandibular primary canines, removing the incisal contacts and interference. No local anesthesia is necessary, as only enameloplasty is being performed (Figure 19.5c and 19.5d). Once the incisal edges are removed, centric occlusion can be achieved along with improved muscle balance and unrestricted growth (Figure 19.5e).

Finger/thumb sucking

Habit therapy with an appliance to reduce overjet and open bite should be instituted when the maxillary permanent incisors erupt (Fricker *et al.*, 2008). Significant overjet is associated with maxillary incisor fracture (Schatz *et al.*, 2013). With accompanying incompetent lip posture, the incidence of incisor fracture is compounded (Bauss *et al.*, 2008). First-phase orthodontic treatment may be performed after eruption of the permanent maxillary central and lateral incisors.

Taste aversion with hot-tasting or bitter-flavored preparations applied to the thumb or fingers may stop the habit (Fricker *et al.*, 2008). For children older than 3 years, Mavala Stop (www.mavala.com) nail polish is applied to the finger(s) or thumb, with recommendation of daily application of a fresh coat. Mavala Stop is also recommended for persistent nail biting.

TGuard™ (www.TGuard.com) offers products for both thumb and finger sucking (Figures 19.6 and 19.7). Each product is available in three sizes; a small size for children aged 3 and 4 years, a medium size for ages 5 and 6 years, and a large size for ages 7 years and older. TGuards are made in the United States of an FDA-listed, medical-grade material, which is BPA and phthalate free. Sixty bracelets with instalock clasps and a reward chart, with stickers, are provided. The bracelets can be removed only with scissors. The TGuard is worn when thumb/finger sucking typically occurs, such as while watching television or bedtime. The guards may also be used to temporarily curtail finger or thumb sucking, permitting chaffed skin to heal. No banding, impressions, or laboratory fees are required. The TGuard

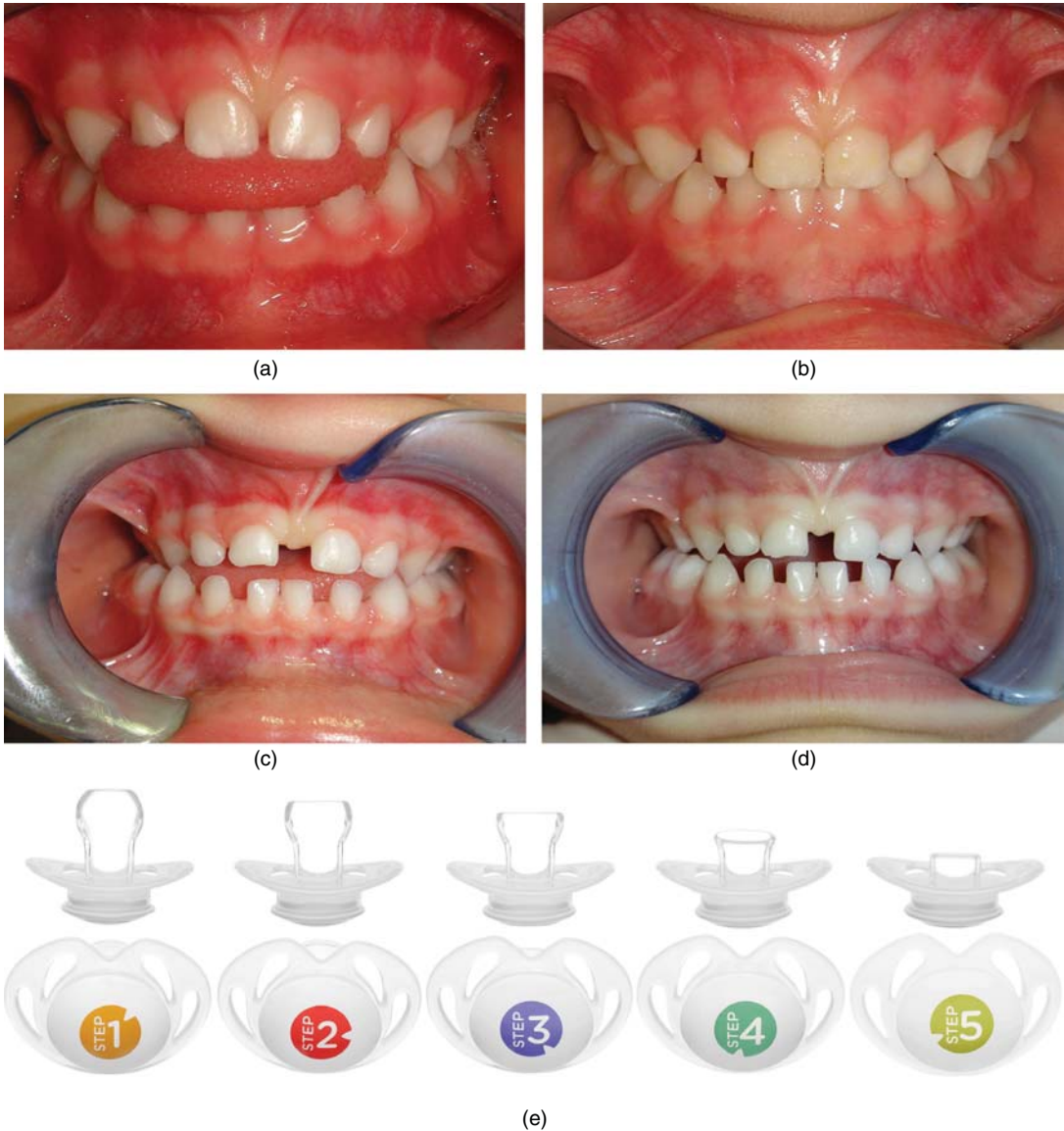

Figure 19.4 (a) Occlusion age 2 years 10 months during pacifier use. (b) Occlusion 6 months after cessation of pacifier habit. (c) Occlusion age 3 years 2 months during pacifier use. (d) Occlusion 6 months after cessation of pacifier habit with some residual palatal constriction. (e) Lily™ Pacifier Weaning System (Lily Child Development).

can be ordered on the Internet. The company states 90% success rates in about 3 weeks, with a money-back guarantee.

If alternative treatments such as a decorative band-aid on the finger/thumb, rewards, taste aversion, and TGuard are unsuccessful, fixed appliance therapy may be considered after the age of 4 years. Fixed appliances

should be presented to the child as “reminders.” The first follow-up visit is recommended in 2 weeks and then bimonthly. The seal with sucking is broken, and the pressure of the orbicularis oris muscle, which encircles the mouth, may assist to retract the maxillary incisors if sucking continues for a period after delivering the appliance.

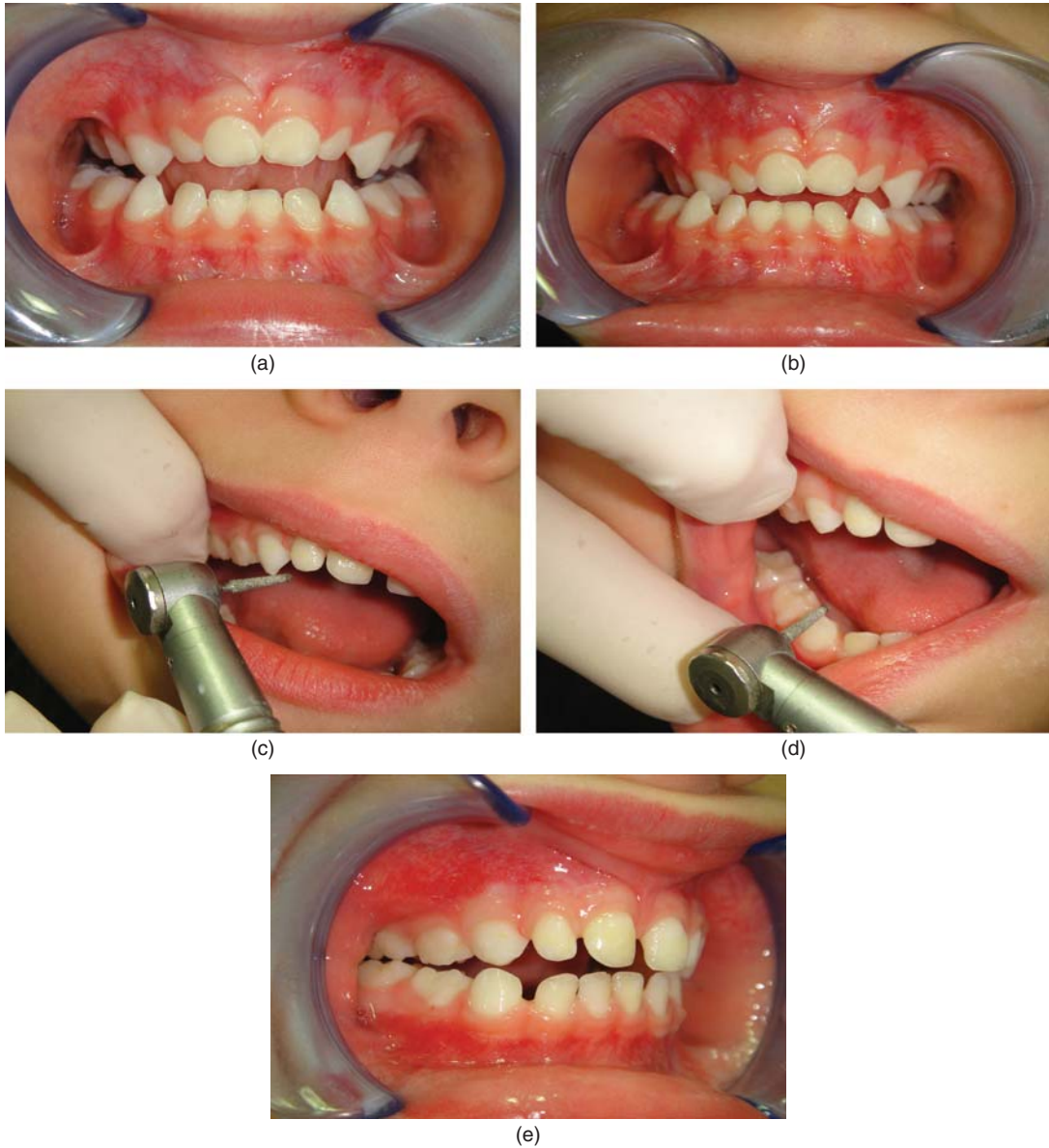

Figure 19.5 (a) Canine interference due to palatal constriction. (b) Functional crossbite due to canine interference. (c) Maxillary primary canine reduction with coarse diamond bur. (d) Mandibular primary canine reduction with coarse diamond bur. (e) Post primary canine reduction.

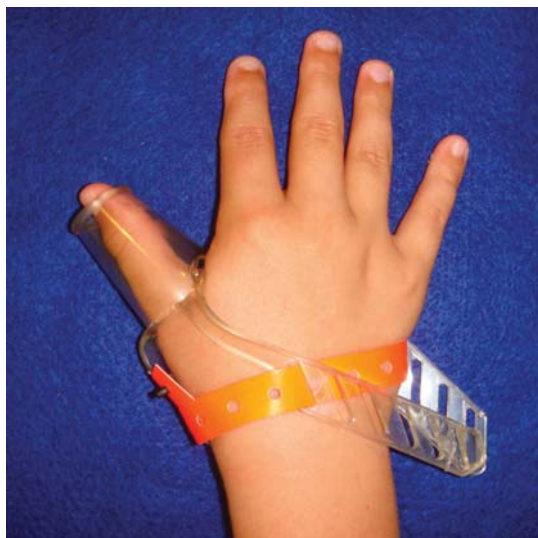


Figure 19.6 TGuard™ for thumb.

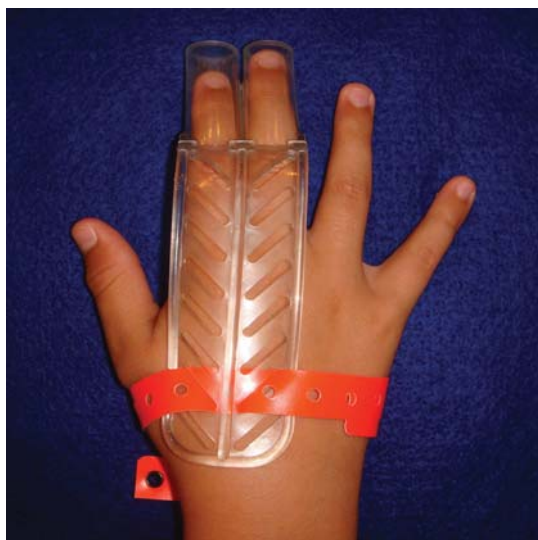

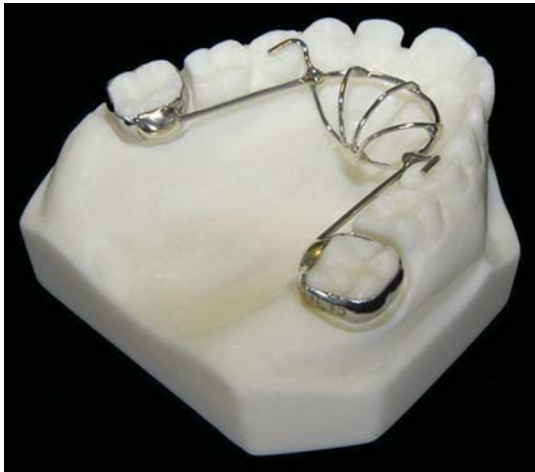Figure 19.7 TGuard™ for adjacent fingers.

The crib and Bluegrass are popular appliances to correct a finger/thumb habit (Figures 19.8a, 19.8b, 19.9a, and 19.9b). Orthodontic bands are fitted on the maxillary second primary molars or first permanent

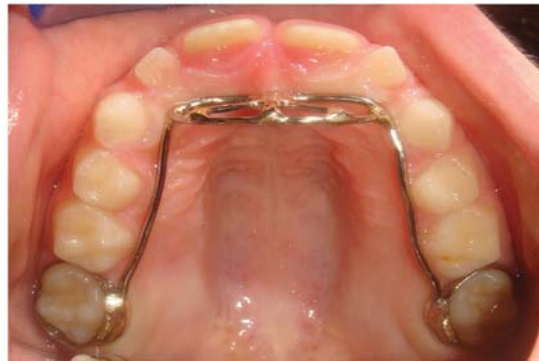molars. If the practice does not have orthodontic bands, the laboratory fabricating the appliance can band the molars on the plaster model. An impression of both arches and a wax bite registration, taken in centric occlusion, for fabrication assure no interferences. A crib is fabricated with a palatal bar with a vertical fence-like portion on a 0.040 stainless steel arch wire soldered to the bands. Fabrication of the Bluegrass appliance is the same as for the crib, but this appliance uses beads or a Teflon roller for distraction. The child can turn the roller or beads with his or her tongue instead of sucking a finger or thumb. This appliance may require up to 36 weeks before habit cessation (Greenleaf & Mink, 2003).

Tongue thrust

The tongue's normal resting posture is on the hard palate. The tongue may rest in a lower, forward position with hypertrophied tonsils, a constricted maxillary arch, macroglossia, or due to muscle memory after a prolonged pacifier, thumb, or finger-sucking habit. Swallowing with tongue thrust is of no clinical significance if resting tongue posture is normal. To determine presence of a tongue thrust, the patient's lower lip is retracted, and the patient is asked to swallow (Figure 19.10). The tongue will thrust forward through the incisors during swallowing with a tongue thrust. If the tongue protrudes forward through the incisors at rest, an open bite with incisor displacement may occur (American Academy of Pediatric Dentistry, 2014). Although success rates vary, an overextended crib may be used to close an anterior open bite, eliminate a tongue thrust, or reduce an anterior tongue position (Figure 19.11). The appliance may force the tongue to a more posterior and higher position. The appliance is worn for about 10 months. There is no agreement regarding the consistency of success with this appliance in changing tongue postures, but tongue adaptation may occur with the overextended crib. The existing morphology of the oral cavity appears to be more influential in tongue posture than the tongue molding the dental arches. (Taslan *et al.*, 2010) A crib with a rake that

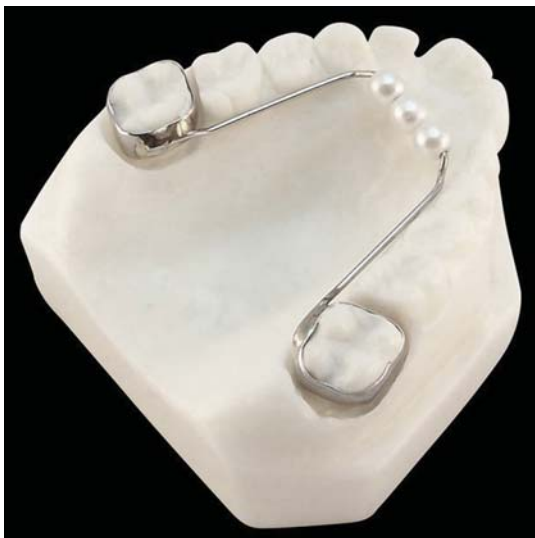

(a)

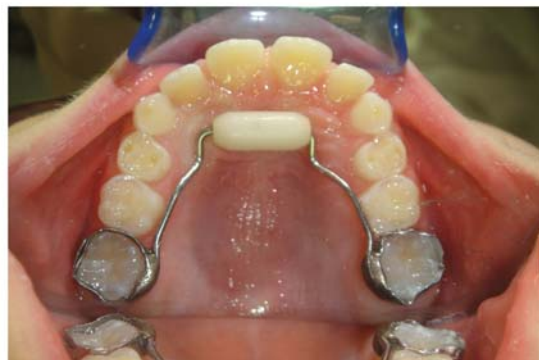

(b)

Figure 19.8 (a) Crib on laboratory model (courtesy of QC Orthodontics Lab, Inc.). (b) Intraoral photograph of crib.



(a)



(b)

Figure 19.9 (a) Bluegrass appliance with beads on laboratory model (courtesy of QC Orthodontics Lab, Inc.). (b) Intraoral photograph of Bluegrass appliance with teflon roller.

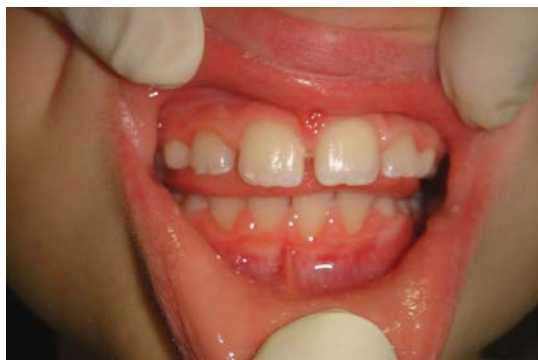

Figure 19.10 Demonstrating tongue thrust with upper and lower lip retracted.

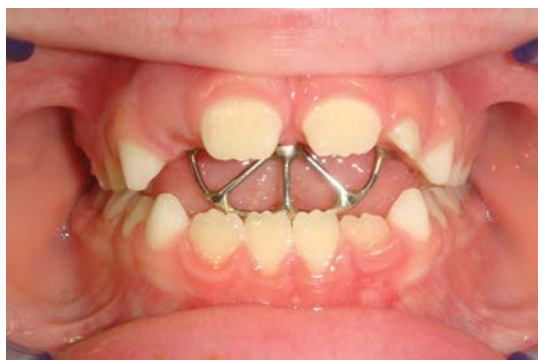
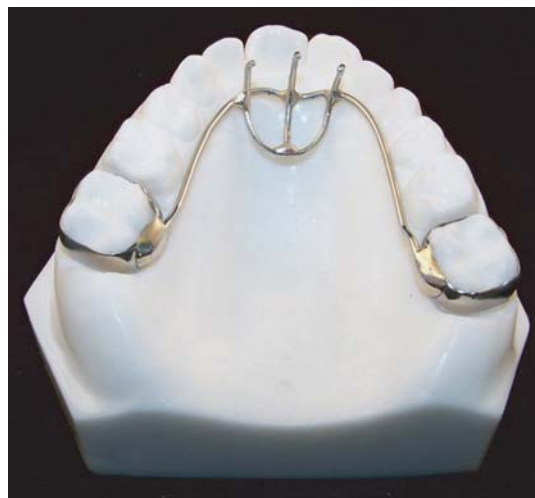
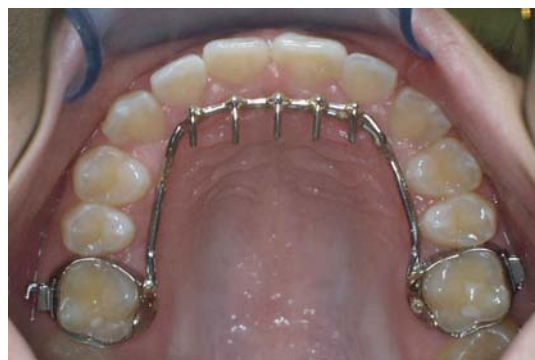Figure 19.11 Overextended crib for tongue thrust and anterior tongue position.

has sharp projections, commonly known as a hay-rake, is also an option (Figure 19.12a and 19.12b). A similar appliance may be used in the mandible (Figure 19.12c). A removable appliance combining a teflon roller to correct digit-sucking, a slow palatal expander to correct posterior crossbite, and a crib to correct tongue thrust was developed by Kulkarni and Lau (Kulkarni & Lau, 2010) (Figure 19.13). The fee to fabricate this appliance as a removable appliance is very high; a modified fixed appliance is shown in this section.



(a)

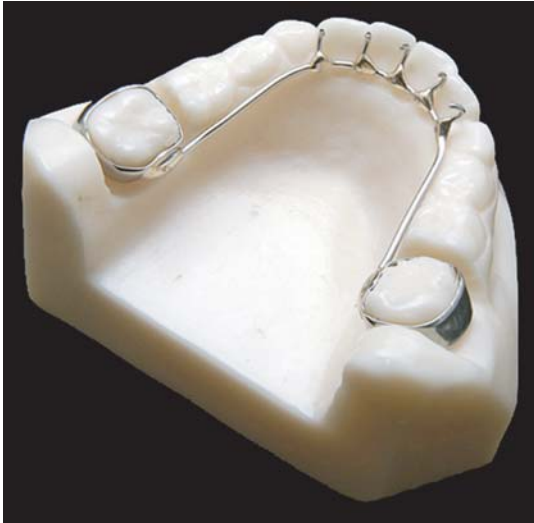

(b)

Figure 19.12 (a) Upper hay-rake for tongue thrust on laboratory model (courtesy of QC Orthodontics Lab, Inc.). (b) Intraoral photograph of crib with points on rake. (c) Lower tongue thrust appliance on laboratory model (courtesy of QC Orthodontics Lab, Inc.).

Bruxing

Bruxing during sleep is often cited as a parental concern. Numerous contributory factors have been suggested such as allergies, upper airway obstruction, emotional stress, fatigue, malocclusion, and neurologic disabilities



(c)

Figure 19.12 (Continued)

(Soxman, 2013; Marks, 1980; American Academy of Pediatric Dentistry, 2014). Insana *et al.* reported that almost 40% of preschoolers and 50% of first graders brux at least one night a week. In preschoolers, bruxing was associated with internalizing behaviors such as anxiety, depression, and withdrawal. Children who brux are also more likely to have reported health problems such as ear infections, frequent colds/flu, allergies, and constant rhinitis. Bruxing may be a sign of other medical/behavioral problems (Insana *et al.*, 2013). Gastric reflux may be suspected with a scalloped, rather than flat appearance of the occlusal surfaces in the mandibular primary molars. An association between

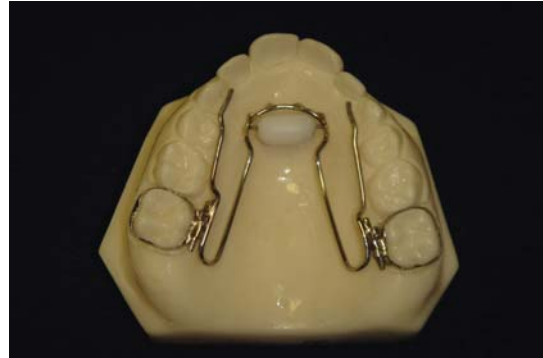

Figure 19.13 Combination appliance on laboratory model (courtesy of QC Orthodontics Lab, Inc.).

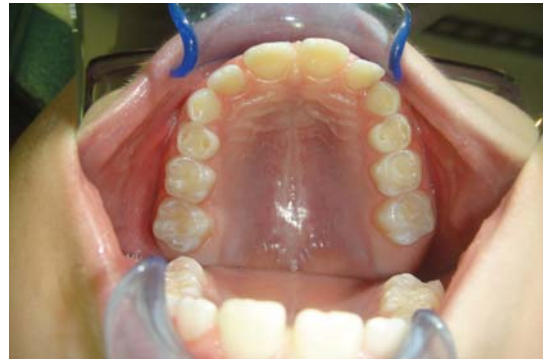
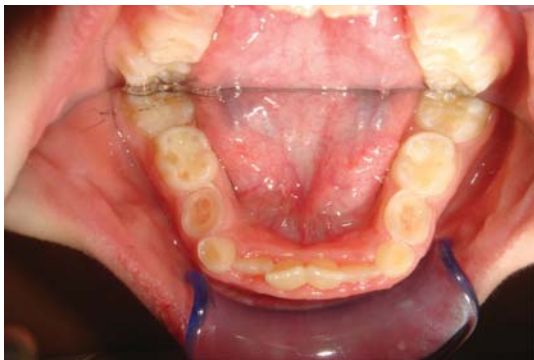
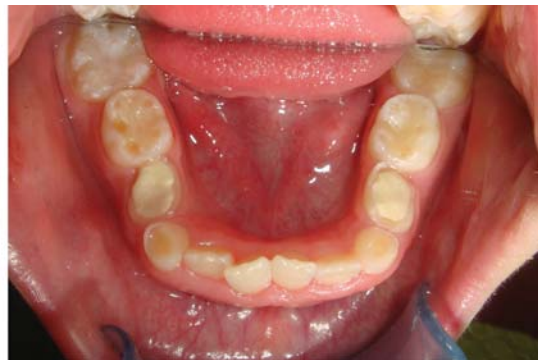Figure 19.14 Mild attrition maxillary primary molars.

gastroesophageal reflux and asthma in children has been suggested, but this has not been clearly shown (Thakkar *et al.*, 2010).



(a)



(b)

Figure 19.15 (a) Severe attrition mandibular primary molars. (b) Glass ionomer restoration in mandibular first primary molars.

A history of allergies may suggest instituting environmental changes to removing the fomites that may induce bruxing during sleep. Dust is a common allergen. Antiallergy bedding such as mattress and pillow covers may be purchased. Down harbors dust mites; down pillows and comforters should be replaced with cotton. Damp dusting, removal of carpet, and stuffed animals and pets from the bedroom may be advised. In general, childhood bruxing is considered to be a harmless habit that is self-limiting and does not evolve to adult bruxism (American Academy of Pediatric Dentistry, 2014).

Mild attrition requires no intervention. Significant attrition, with pending pulp exposure, may be restored with high-viscosity glass ionomer cement, placed out of occlusion (Figures 19.14, 19.15a, and 19.15b). Primary molars may be restored with stainless steel crowns, but continued bruxing may create a hole in the occlusal surface of the crown, trapping food under the crown. Preveneered crowns (stainless steel crowns with a composite facing) are contraindicated because bruxing would fracture the facings. A zirconia crown would be the better choice for severe bruxing with risk of pulp exposure if glass ionomer is not retained.

References

- Adair, S. (2003) Pacifier use in children: a review of recent literature. *Pediatric Dentistry*, **25**, 449–458.
- American Academy of Pediatric Dentistry. (2014) Guideline on management of the developing dentition and occlusion in pediatric dentistry. *Pediatric Dentistry*, **36** (special issue), 251–263.
- Bauss, O., Freitag, S., Rohling, J. *et al.* (2008) Influence of overjet and lip coverage on the prevalence and severity of incisor trauma. *Journal of Orofacial Orthopedics*, **69**, 402–410.
- Fricker, J., Kharbanda, O.P. & Dando, J. (2008) Orthodontic diagnosis and treatment in the mixed dentition. In: Cameron, A.C. & Widmer, R.P. (eds), *Handbook of Pediatric Dentistry*, 3rd edn. Mosby, London, pp. 341–377.
- Greenleaf, S. & Mink, J. (2003) A retrospective study of the use of the bluegrass appliance in the cessation of thumb habits. *Pediatric Dentistry*, **25**, 587–590.
- Insana, S.P., Gozal, D., McNeil, D.W. *et al.* (2013) Community based study of sleep bruxism during early childhood. *Sleep Medicine*, **14**, 183–188.
- Kulkarni, G.V. & Lau, D. (2010) A single appliance for the correction of digit-sucking, tongue-thrust, and posterior cross-bite. *Pediatric Dentistry*, **32**, 61–63.
- Marks, M.B. (1980) Bruxing in allergic children. *American Journal of Orthodontics*, **77**, 48–59.
- Schatz, J.-P., Hakeberg, M., Ostini, E. *et al.* (2013) Prevalence of traumatic injuries to permanent dentition and its association with overjet in a Swiss child population. *Dental Traumatology*, **29**, 110–114.
- Soxman, J.A. (2007) Non-nutritive sucking with a pacifier: pros and cons. *General Dentistry*, **55**, 59–62.
- Soxman, J.A. (2013) Upper airway obstruction in the pediatric patient. *General Dentistry*, **61**, 13.
- Taslan, S., Biren, S. & Ceylanoglu, C. (2010) Tongue pressure changes before, during and after crib appliance therapy. *Angle Orthodontics*, **80**, 533–539.
- Thakkar, K., Boatright, R.O., Gilger, M.A. *et al.* (2010) Gastroesophageal reflux and asthma in children: a systemic review. *Pediatrics*, **125**, e925–e930.
- Warren, J.J., Bishara, S.E., Steinbock, K.L. *et al.* (2001) Effects of oral habits' duration on dental characteristics in the primary dentition. *Journal of the American Dental Association*, **132**, 1685–1693.
- Warren, J.J., Slayton, R.L., Yonezu, T. *et al.* (2005) Effects of nonnutritive sucking habits on occlusal characteristics in the mixed dentition. *Pediatric Dentistry*, **27**, 445–450.
- Zardetto, C.G., Rodrigues, C.R.M.D. & Stefani, F.M. (2002) Effects of different pacifiers on the primary dentition and oral myofunctional structures of preschool children. *Pediatric Dentistry*, **24**, 552–560.

The various forms of behavior that present when treating the pediatric patient can be daunting. Describing the child's behavior with terms such as fearful, strong avoidance, combative, stubborn, defiant, and hysterical is a method to more clearly define the type of behavior affecting our ability to safely and/or ideally perform treatment. Individual temperament, the characteristic physiological and emotional state of an individual, which tends to condition responses to the various situations of life, significantly influences our ability or inability to modify behavior with basic techniques. Salem *et al.* (2012) found that dental fear and anxiety were more influenced by temperament than parental influence. Techniques using tell–show–do, desensitization, modeling, and distraction prove to be successful, especially for a child who is purely fearful or mildly apprehensive. Parents/guardians should be informed regarding limitations imposed by a child's behavior on our ability to provide quality care. Societal and parental influences are increasingly influential in our ability to guide behavior (Juntgen *et al.*, 2013). Diverse ethnic communities and various cultural influences increasingly impact our behavior guidance and the compliance of parents/guardians (Goleman, 2014).

Age-appropriate expectations

An age-appropriate approach insures that expectations of the dentist, staff, and parent/guardian are realistic regarding the child's ability to cooperate.

Toddlers are developing a sense of independence, but a strong attachment to the parent is appropriately present until the age of 2 years. Once a high level of distress is reached, calming the toddler is difficult. If the child is crying or exhibiting avoidance behavior, examine the child as quickly as possible to determine the existence of caries or pathology. The knee-to-knee examination for an infant provides safe, adequate immobilization for the examination (Figure 20.1). Apprehensive 2- or 3-year-old children may sit on the parent/guardian's lap for examination or a preventive care visit. A neck pillow may be offered for neck support for the parent/guardian (Figure 20.2). With combative or strong avoidance behavior, the child sits on the lap of the parent/guardian, and the parent/guardian holds the child's hands and places one of his or her legs over the child's legs (Figure 20.3). To avoid startling a child, place your hand on his or her shoulder before reclining the chair, while telling him or her that the chair is going to move backward (Figure 20.4). Tell–show–do, to explain what to expect, is a good tool for guidance at any age, but may begin with the toddler. The procedure is described in as few words as possible, the materials to be used are shown to the child, and the procedure begins (Figures 20.5a, 20.5b, and 20.5c). Start with the maxillary incisors, desensitizing the child, before examining or performing prophylaxis on the molars.

Suggest ideas for preparing the preschooler for the first visit to the parent/guardian such as reading a story about going to the dentist, using a reclining chair at home to experience the sensation of the chair moving backward, and using a battery powered spin brush. Preschool-age

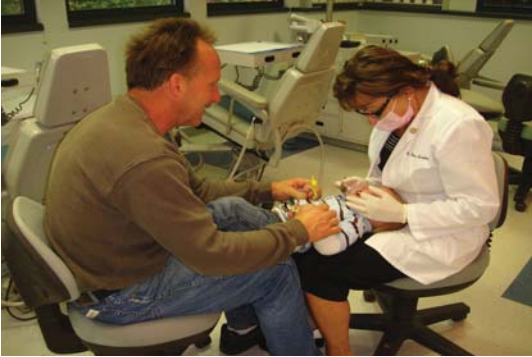

Figure 20.1 Knee-to-knee examination.

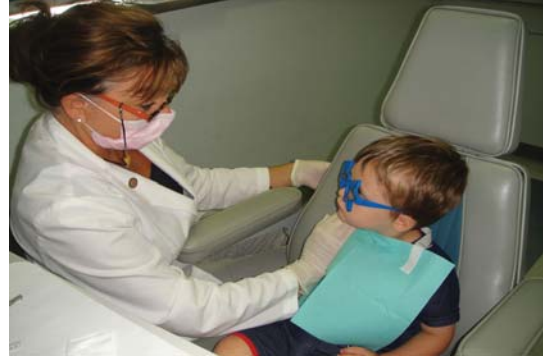

Figure 20.4 Placing hand on child's shoulder before reclining chair.

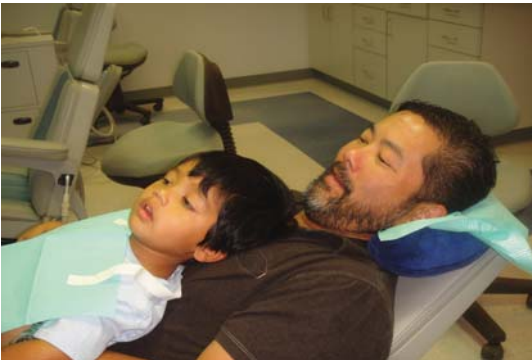

Figure 20.2 Child on parent's lap for examination.

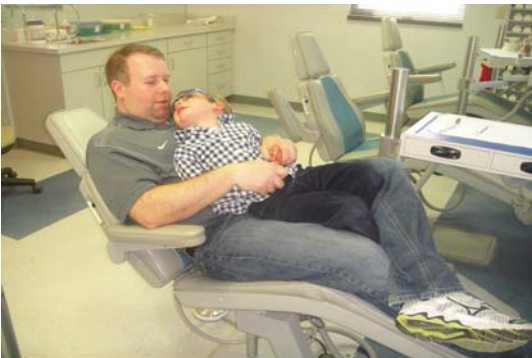

Figure 20.3 Parent stabilizing the child.

children are in the midst of multiple inoculations; fear of a "shot" may be the predominant concern (Salem *et al.*, 2012). Most preschool children are learning the ABC's and to count. Most children can count to 10 by the age of 3 years. Saying the ABC's or counting the

teeth during the examination provides distraction and familiarity. Count the child's fingers before placing the mirror in the child's mouth. Introduce the mirror by touching the inside of his cheek while describing the softness of the mirror. Explain that because you are counting baby teeth, you must be gentle, just as you would be with a baby. Pretending is common play for the preschool child. Modeling is a term used to describe a fearful or apprehensive child watching a relaxed child of similar or younger age undergoing a procedure. Modeling is typically not beneficial until the age of 4 years. Unless modeling with siblings, the parents/guardians of both children should give consent for this method of guidance (Figure 20.6). A parent/guardian, who believes a procedure may be too difficult for his or her child to cooperate, may also observe another child of same or younger age undergoing treatment with a similar procedure. An emotionally healthy 4-year-old child may be able to separate from the parent after the first visit.

The school-age child should be able to sit still and focus. He or she now understands consequences. Competence is gaining value in his or her life, and so accomplishing treatment goals is important not only for the dentist, but also for the child. If fearful behavior prohibits completion of the planned procedure, make an effort to accomplish something so the child does not leave the office with a sense of failure. In the same manner, do not permit combative or avoidance behavior to postpone treatment, possibly guaranteeing the same behavior in a manipulative child at the next appointment. Placing sealants is a good procedure to use modeling for behavior guidance. Voice

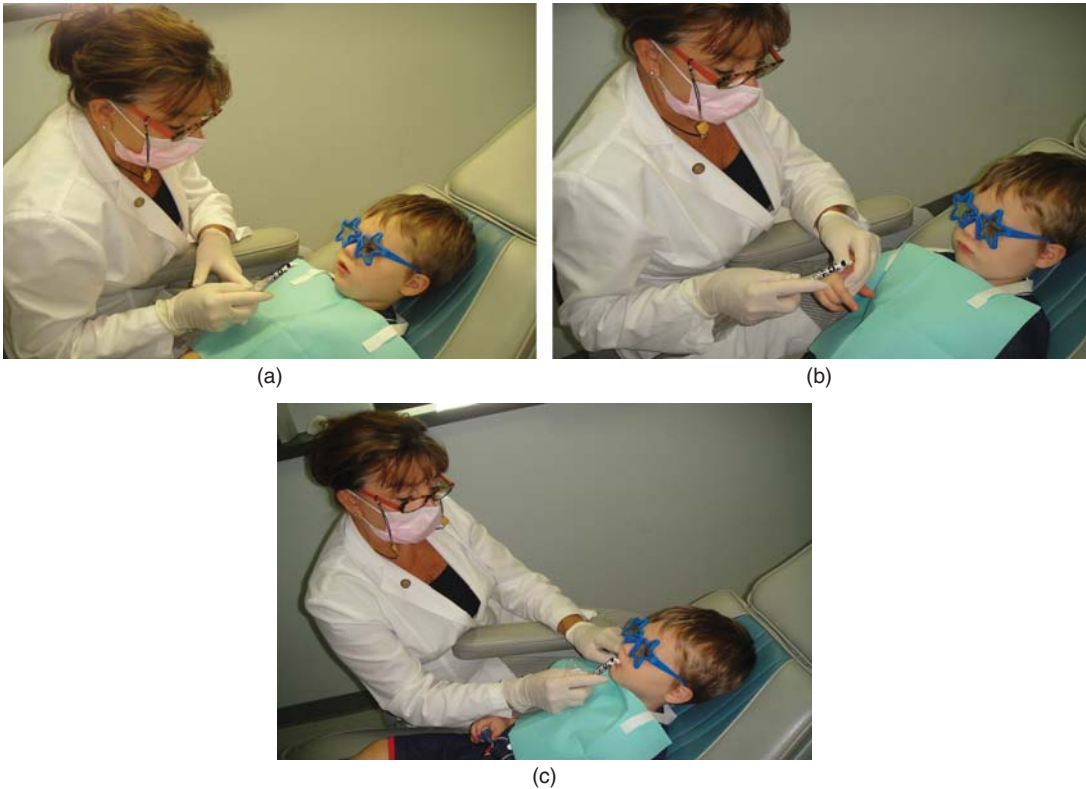

Figure 20.5 (a) Telling about the procedure. (b) Showing the procedure. (c) Doing the procedure.

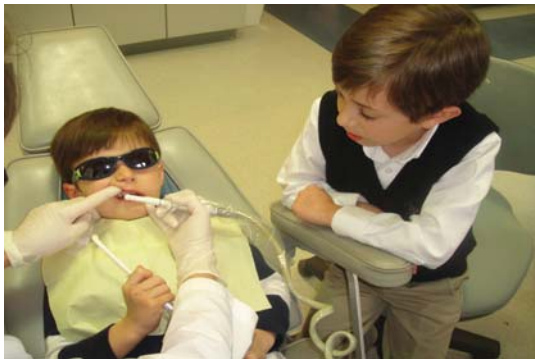

Figure 20.6 Modeling.

control is a form of behavior guidance that uses the tone of voice, loudness, or pace to gain cooperation or attention. Parents/guardians should be advised of this technique before use, as some may deem voice

control unacceptable (American Academy of Pediatric Dentistry, 2014). School-age or older children would be preferable for this form of guidance.

Watching television or playing computer games before a dental visit may relax a child (Campbell *et al.*, 2005). Sitting quietly beside a parent/guardian, who is reading a story before treatment, may be helpful for an apprehensive child. Systematic desensitization is also useful to reduce anxiety. An effort is made to begin treatment with a procedure that would evoke minimal fear and progress toward more fear-provoking stimuli (Widmer *et al.*, 2008). Think about desensitizing when determining the sequence of a treatment plan, considering local anesthesia and the length of the procedures. Davidovich *et al.* determined that treatment duration was the main factor influencing behavior for younger and older children. Treatment time should not exceed 30 min (Davidovich *et al.*, 2013).

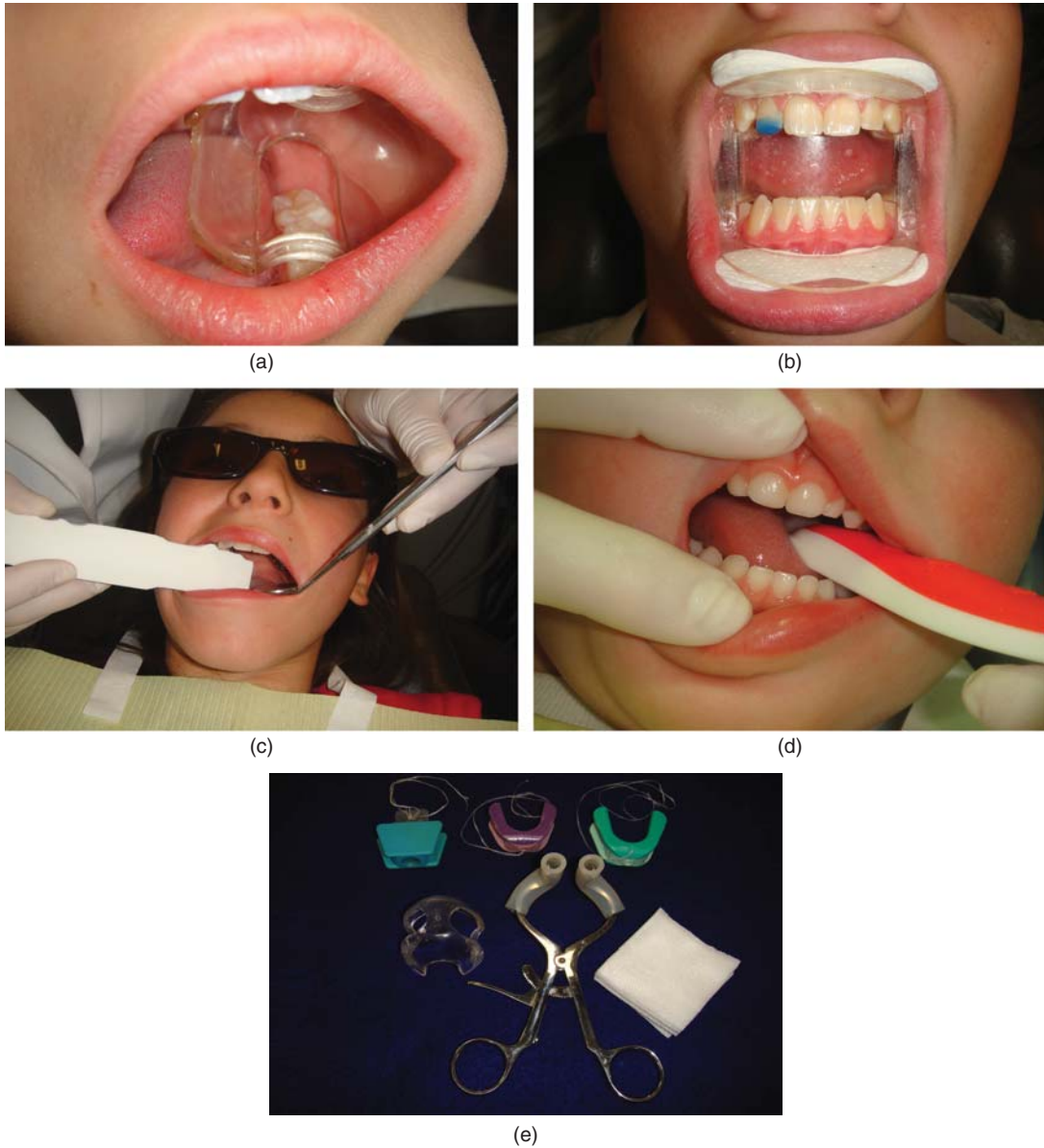


Figure 20.7 (a) Parkell dry-field mouth prop for posterior. (b) Parkell dry-field mouth prop for anterior. (c) Open wide disposable mouth rest. (d) Toothbrush with rubber handle for mouth prop. (e) Mckesson mouth props, Molt mouth prop, posterior Parkell dry-field mouth prop.

Mouth props

The Parkell dry-field posterior mouth prop (Parkell, Inc.) is made of clear, autoclavable plastic providing a dry field, throat partition and retraction of the cheek and

tongue (Figure 20.7a). An anterior version, to restore an incisor, is also available (Figure 20.7b). The Open Wide Disposable Mouth Rest (Specialized Care Company, Inc.) can be used with any age child who is unwilling to open his or her mouth or who is unable to reliably

maintain an open mouth. This mouth prop is especially useful for children with special needs (Figure 20.7c). The rubber handle of a pediatric toothbrush may also be used (Figure 20.7d). Rubber Mckesson mouth props come in various sizes and are available from many dental supply companies. Molt mouth props work well during sedation or general anesthesia. A few pieces of 2×2 gauze should be placed between the cheek and the mouth prop to avoid pressure/injury to the cheek and caution that the lip is not trapped under the mouth prop (Figure 20.7e).

Guidance techniques

For most procedures, offering the child a hand mirror to watch the procedure while it is being performed, a minute timer, or the child rubbing the palms of his or her hands together are methods to provide distraction for a mildly anxious, but cooperative child (Figures 20.8, 20.9, and 20.10). Dilated pupils may indicate fear and the need for more empathy and verbal support. Telling a story and asking about a family pet (guessing the pet's name, color, etc.) are methods to engage and relax the school-age child during a restorative procedure. He or she can answer with one finger for "yes" and two fingers for "no." Counting backward slowly from 20 or 30, while interjecting comments, will increase the amount of time necessary to get to "one," and talking about a movie, song, or anything that might be of interest to the child engages the child. Do not tell a child to raise his or her hand if anything is troubling. For some children, the hand may be constantly raised throughout the procedure (Figure 20.11). A gag reflex can be altered by

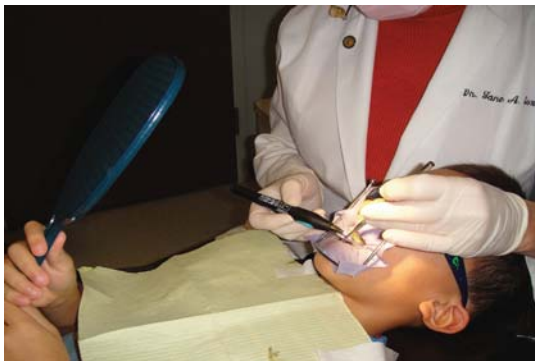

Figure 20.8 Mirror for distraction.

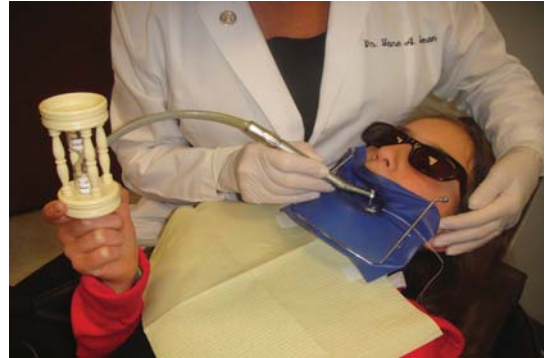

Figure 20.9 Minute timer for distraction.

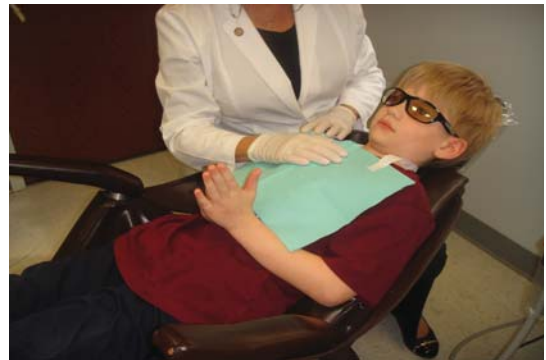

Figure 20.10 Rubbing palms together to reduce anxiety.

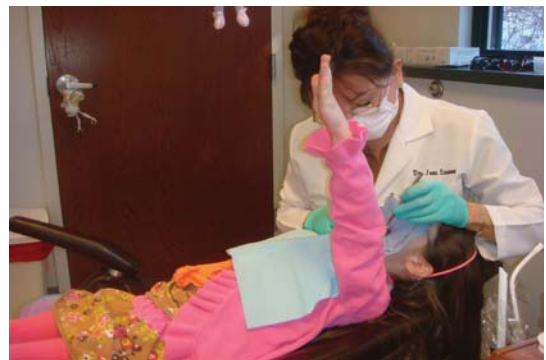


Figure 20.11 Child raising hand during operative procedure.

putting pressure with the eraser end of a pencil into the palm of the hand at the point where the long axis of the middle finger and thumb meet (Scarborough *et al.*, 2008) (Figure 20.12). Another acupressure technique, which may reduce mild anxiety, is squeezing the fleshy area of the hand between the index finger and thumb

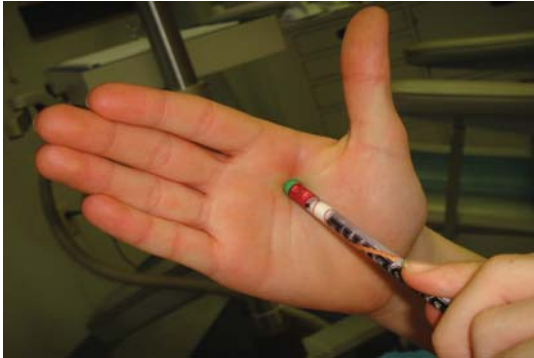


Figure 20.12 Palm pressure to reduce anxiety.

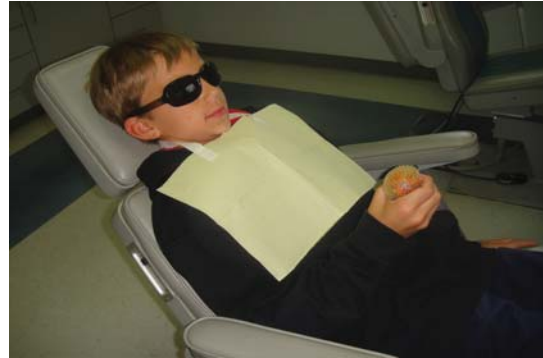

Figure 20.15 Squeezing a soft rubber ball for mild anxiety.



Figure 20.13 Squeezing fleshy area between index finger and thumb to reduce anxiety.

(Figure 20.13). Audio-visual glasses to watch a movie or an iPod to listen to music is very effective distraction for a mildly anxious child beginning at school age (Figures 20.14a and 20.14b) Squeezing a rubber ball is

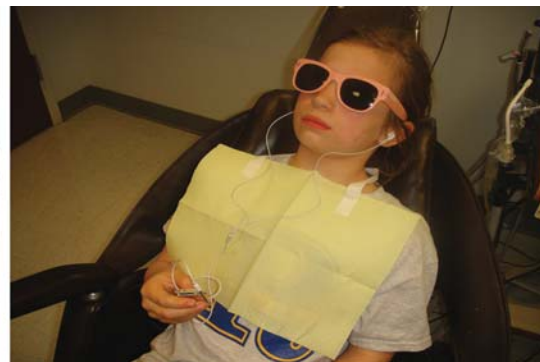also a good distraction technique (Figure 20.15). Permitting a child to leave the operatory chair for a drink of water, after the local anesthesia is administered, is a good method for reframing to change mindset (Figure 20.16).

Eye protection

Sunglasses or “fun glasses” shield sensitive young eyes from the bright chair light. They also provide eye protection from splatter and, more importantly, protection from injury with an instrument because of unanticipated movement or accidental dropping of an instrument. Multicolored sunglasses with various designs can be inexpensively purchased in bulk. Permitting the child to select his or her glasses before the procedure provides a good start, offering a choice. Parents/guardians are impressed with the thoughtfulness



(a)



(b)

Figure 20.14 (a) Audio-visual distraction with A-V glasses to watch a movie. (b) Auditory distraction with earphones and music.

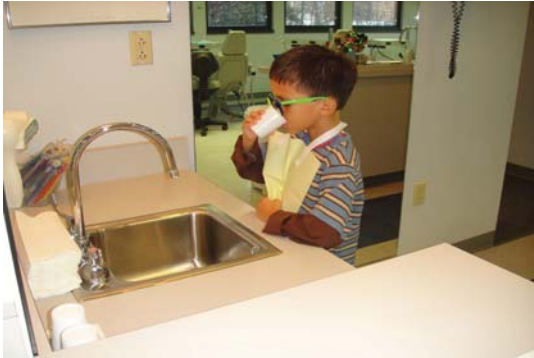

Figure 20.16 Reframing to change mindset.

of reducing the brightness of the light in the child's eyes and providing eye protection.

Isolation for restorative procedures

Isolation may be challenging in the pediatric population. The floor of the mouth is higher, protective reflexes are diminished, and the tongue is disproportionately large. The rubber dam often incites a strong negative response. Although it provides a reliable throat partition, moisture control, and tongue retraction, an open mouth narrows the oropharyngeal area, significantly reducing the volume of the upper airway patency and decreasing tidal volume (Iwatani *et al.*, 2013). If the rubber dam is covering the child's nose, that portion may be cut away with scissors, providing more ventilation and/or less intimidating isolation (Figure 20.17). The term rubber moustache is an amusing description for the

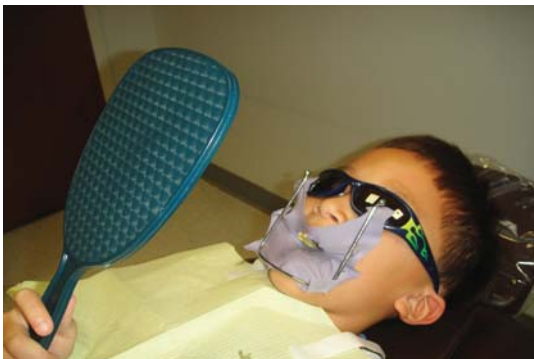

Figure 20.17 Rubber dam with a portion under nose cut away.

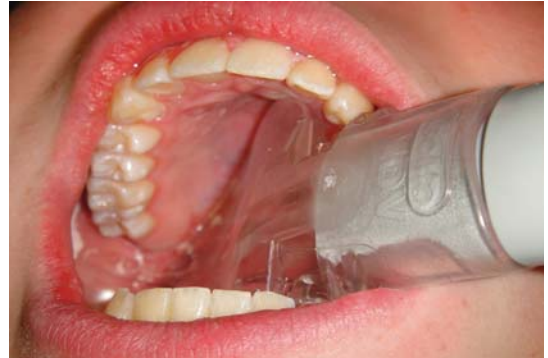

Figure 20.18 Isolite.

piece of rubber that is cut from the rubber dam. The use of a Breathe-Right Nasal Strip can also be very effective to improve airflow through the nose. The Isolite provides a generally well-accepted alternative with a single-use, latex-free unit in various sizes, cheek retractor, throat partition, suction, and an optional light source (Figure 20.18). It provides easy access and isolation for a partially erupted permanent second molar and the ability to restore the ipsilateral maxillary and mandibular quadrants without removal. The continuous suction also appears to offer a source of distraction. If necessary, the Isolite can easily be trimmed with scissors for more custom sizing. The rubber dam may be preferable with a strong gag reflex and for children younger than 4 years.

Radiographs

If using conventional radiography, position the cone head before placing the film in the child's mouth. If the size 0 film is too large, it may be bent or placed vertically (Figure 20.19). Permit the child to place the film in his or her mouth using a snap-a-ray or similar device, if he or she is reluctant to permit placement by staff or the dentist. Telling the child to open his eyes as wide as possible and using a mirror to watch film placement or to lift a foot off the chair are good distraction techniques (Figure 20.20). For a gag reflex, have the child bend his or her knee and press his or her foot into the chair (Figure 20.21). If unable to obtain an anterior periapical radiograph, use a size 4 film bent in the middle (Figures 20.22a, 20.22b, 20.22c, and 20.22d).




Figure 20.19 Size 0 film bent or placed vertically in a snap-a-ray film holder.

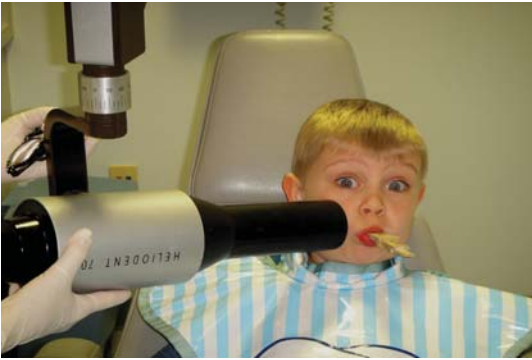

Figure 20.20 Eyes wide open for distraction.

For a lateral view, a size 4 film is placed in a film holder and the exposure time doubled (Figure 20.23).

Parent/guardian presence

The parent/guardian should be present for treatment for children younger than 4 years and with special needs. Parents/guardians of autistic children will be especially helpful with their knowledge of stress cues and tolerance level. Most parents/guardians prefer to be present for treatment. Kim *et al.* (2012) found that parents who are permitted to choose to be present or absent for the dental visit were more satisfied with the visit, had a more positive attitude toward the dentist, and had a more positive perception of their child's response to the visit.

The parent/guardian who is present is termed the dentist's "silent partner," stressing that his or her mere presence is support for the child. Explain the dentist's need

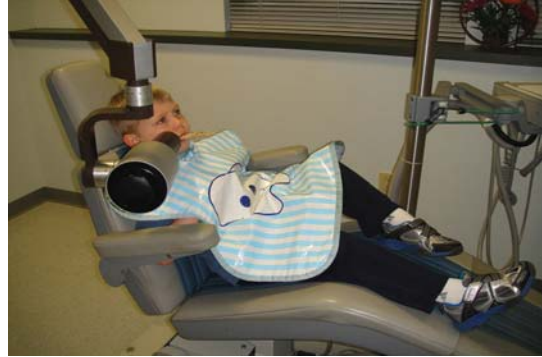


Figure 20.21 Foot pressing into chair to reduce gag reflex.

to give the child his or her undivided attention and that the dentist and staff want the child's undivided attention (Soxman, 2013).

Protective stabilization should be considered if behavior does not permit provision of care and lack of treatment would result in pain and/or poor results (McWhorter & Townsend, 2014). It may be necessary to minimize risks of injury to the child, parent/guardian, dentist or staff, and/or to complete treatment (American Academy of Pediatric Dentistry, 2014). A parent/guardian may be willing to assist with gently stabilizing a young child for restorative treatment by holding his hands. Fathers, straddling the chair, are particularly good for this type of assistance (Figure 20.24). If the child exhibits extreme fear or hysterical behavior, the stabilization should be released and the procedure stopped as quickly as possible.

If the child is doing well and the attending parent/guardian is calm and quiet, he or she may be encouraged to continue to accompany the child for each visit. Changing the attending parent/guardian may negatively impact the child's behavior. However, if the parent/guardian who is present is constantly interjecting comments, repeating the dentist's requests, appears to be very anxious or has a dental phobia, another parent/guardian or a close relative should be invited to accompany the child.

After a few visits, most parents/guardians do not feel the need to be present for treatment. Separating sends two messages to the child. First, that the parent/guardian believes the child is capable of undergoing treatment without his or her presence and also that he or she trusts the dentist. A trusting parent typically has a trusting child. If a parent/guardian remains in the

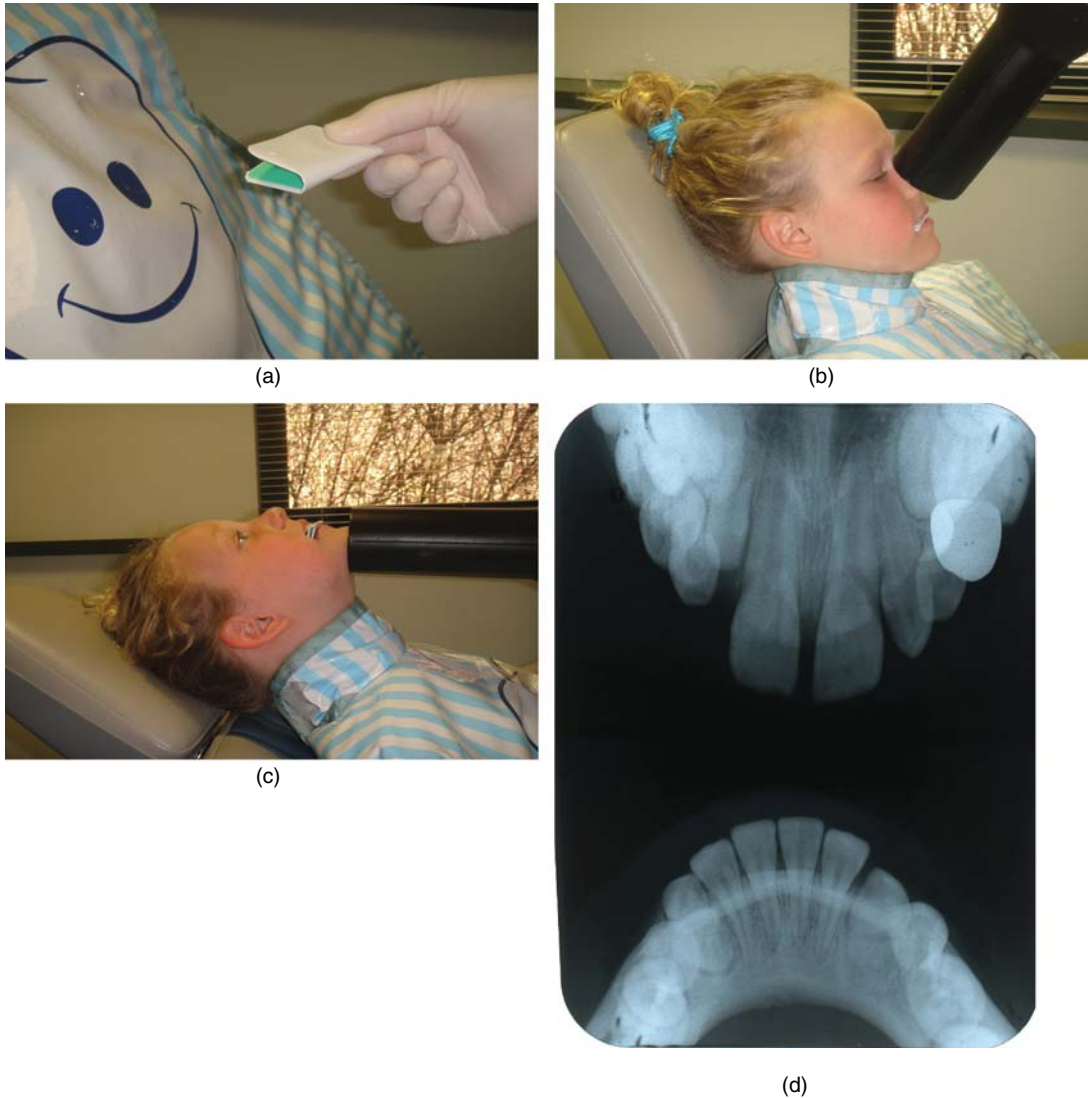


Figure 20.22 (a) Size 4 film bent in the middle to obtain upper/lower occlusal radiograph. (b) Obtaining upper occlusal view with size 4 film. (c) Obtaining lower occlusal view with size 4 film. (d) Upper/lower occlusal radiographic views with size 4 film.

reception room, and the child begins to cry or becomes hysterical, he or she should be brought to the operatory. In some instances, this may be helpful to complete the procedure. Often, the crying begins with the simple act of placing topical anesthetic. If a parent/guardian perceives improper behavioral guidance by the dentist or staff, ensuing complaints or other problems are likely. Parents/guardians who hear the child crying need to see what is provoking this reaction and for the assurance of

the child's well-being. Once the parent/guardian is by the child's side, the door to the operatory may be closed for privacy and to avoid distress for other patients.

Frankl behavioral rating scale

This scale uses numbers from 1 to 4 to describe specific behaviors. A rating of 4 is a positive rating given to a cooperative, engaging child. A rating of 3 describes mild apprehension or reluctance, and a need for some

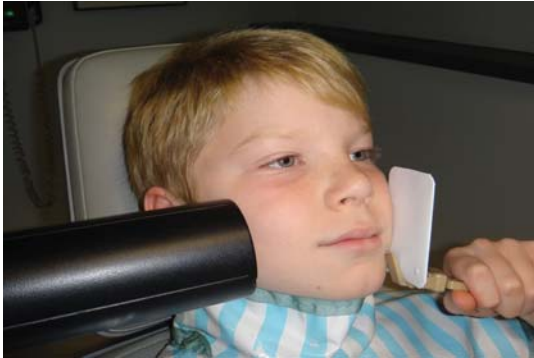

Figure 20.23 Size 4 film for lateral radiographic view.



Figure 20.24 Father straddling the chair and assisting with stabilization.

additional behavior guidance to obtain full cooperation. A rating of 2 describes an uncooperative child, and a rating of 1 describes fearfulness and/or strong avoidance or combative behavior. (American Academy of Pediatric Dentistry, 2014)

Behavior guidance may be the most challenging aspect of treating pediatric patients. Strong avoidance, combative, hysterical, and/or defiant behaviors prevent our ability to safely perform restorative treatment and reduce the quality of care we provide. Observation or “watching” to await more maturity or improved coping skills may be recommended for early lesions and/or application of fluoride varnish for noncavitated

lesions. Performing an interim therapeutic restoration for asymptomatic caries may offer another alternative. Restorative appointments should be scheduled during the morning for young children. If sedation or general anesthesia is deemed necessary for treatment, rationale may include young age, acute stress reaction, extent of caries, and medical or emotional circumstances.

References

- American Academy of Pediatric Dentistry (2014) Guideline on behavior guidance for the pediatric dental patient. *Pediatric Dentistry*, **36** (special issue), 179–191.
- Campbell, C., Hosey, M.-T. & McHugh, S. (2005) Coping behavior in children prior to dental general anesthesia: a randomized controlled trial. *Pediatric Anesthesia*, **15**, 831–838.
- Davidovich, E., Wated, A., Shapira, J. & Ram, D. (2013) The influence of location of local anesthesia and complexity/duration of restorative treatment on children’s behavior during dental treatment. *Pediatric Dentistry*, **35**, 333–336.
- Goleman, J. (2014) Cultural factors affecting behavior guidance and family compliance. *Pediatric Dentistry*, **36**, 121–127.
- Iwatani, K., Matsuo, K., Kawase, S. *et al.* (2013) Effects of open mouth and rubber dam on upper airway patency and breathing. *Clinical Oral Investigation*, **17**, 1295–1299.
- Juntgen, L.M., Sanders, B.J., Walker, L.A. *et al.* (2013) Factors influencing behavior guidance: a survey of practicing pediatric dentists. *Pediatric Dentistry*, **35**, 539–545.
- Kim, J.S., Boynton, J.R. & Inglehart, M.R. (2012) Parents’ presence in the operatory during their child’s dental visit: a person-environmental fit analysis of parents’ perception. *Pediatric Dentistry*, **34**, 407–413.
- McWhorter, A.G. & Townsend, J.A. (2014) Behavior symposium workshop a report - current guidelines revision. *Pediatric Dentistry*, **36**, 152–153.
- Salem, K., Kousha, M., Anissian, A. *et al.* (2012) Dental fear and concomitant factors in 3-6-year-old children. *Dental Research Dental Clinics Dental Prospects*, **6**, 70–74.
- Scarborough, D., Bailey-Van Kuren, M. & Hughes, M. (2008) Altering the gag reflex via a palm pressure point. *Journal of the American Dental Association*, **139**, 1365–1372.
- Soxman, J. (2013) Parental presence. *General Dentistry*, **61**, 2–3.
- Widmer, R., McNeil, D.W., McNeil, C.B. *et al.* (2008) Child management. In: Cameron, A.C. & Widmer, R.P. (eds), *Handbook of Pediatric Dentistry*, 3rd edn. Mosby, London, pp. 9–37.

Index

Note: Page numbers in **bold** refer to illustrations

A

- Abscess, considerations with, 73–74
- Adhesive primary molar tooth restoration, 30–34
 - Class I restorations, 33
 - Class II restorations, 33
 - Class V restorations, 33
 - compomers, 33
 - holes and slit placement for rubber dam, 30, **31**
 - pit and fissure sealants, 30
 - resin-based composites (RBCs), 30–33
 - resin-modified glass ionomer restorative cements, 33–34
- Adper Prompt L-Pop (3M-ESPE), 78
- Age-appropriate expectations, in behavior guidance, 173–175
 - modeling, 174, **175**
 - preschool-age children, 174
 - school-age child, 174
 - toddlers, 173
- Alternative/atraumatic restorative technique (ART), 1
- Alveolar bone covering permanent successor, 133
- Amalgam, 90
- Amalgambond Plus (Parkell), 90
- American Academy of Pediatric Dentistry (AAPD), 1, 6–8, 39, 51, 55, 59, 62, 63, 65, 72–74, 77, 83, 121, 127, 133, 135, 163, 167, 170, 171, 175, 180, 182
- Ammoniated silver nitrate, 29
- Anterior esthetic fixed appliances, 20–24
 - considerations, 20–24
 - contraindications, 24
 - preoperative labial view, **21**
 - preoperative palatal view, **21**
- Apexification, 147–151
- Apical barrier technique with MTA, 151–153
- Apical plug, 147–151
 - with MTA, 151–152, **151–152**
- Appliance fabrication, banding and impression for, 139–140
- Articaine, 6–7

B

- Band and loop, 136–137, **135–136**
 - after appliance delivery, 141–142
 - with first permanent molar banded and loop extending distally to mesial of partially erupted first permanent molar, **137**
 - distally to mesial of the first permanent molar, 136, **136**
 - mesially to distal of the first primary molar, 136, **136**
 - for premature loss of
 - mandibular first primary molar, 135, **135**
 - maxillary first primary molar, 135, **135**
 - removing band, **141**
- Behavior guidance, 173–182
 - age-appropriate expectations, 173–176
 - child on parent's lap for examination, 173, **174**
 - eye protection, 178–179
 - guidance techniques, 177–178
 - isolation for restorative procedures, 179
 - knee-to-knee examination, 173, **174**
 - mouth props, 176–177
 - parent/guardian presence, 180–182
 - radiographs, 179–180
- Biodentine (Septodont), 55
- Black copper cement, 29
- Bleach–etch–seal technique (BEST), 102
- Blue Boa, 78, **79**
- Bluegrass to correct finger/thumb sucking, 167, **168**
- Boley gauge, **129**
 - to measure mesial–distal width, 41, **41**
- Bonded resin composite strip crown, 14, **15**
- Bonding agent, 78–79
- Brass wire technique, 109–114
 - bitewing radiograph, 109, **110**
 - brass wire placement, 110–112
 - elastomer placement, **111**
 - initial attempt to place a 0.028-in. wire, 113
 - local anesthesia, 110
 - separators, 112–113
 - wire removal, 113–114
 - wire tightening, 113
- Breathe-Right Nasal Strip, 179
- Bruxing, 169–171
- Bupivacaine, 6

C

- Calcium hydroxide (Ca(OH)₂), 85–86, 93–94
- Canine interference, 164, **166**
- Caries detection, 77–78
- Caries removal and crown placement, 17–19, **18**
 - curing, 17–19
 - finishing, 17–19
- Cementation, 20, 48–50
 - stainless steel crown, 91–92
- Cervical caries, 1, **2**
- Chairside fabrication, 140–141
- Cheng Crowns, 19
- Chromium alloy deciduous crowns, 29
- Clindamycin, 155
- Compomers, 33

Congenitally missing permanent successor, 129–131
 Copper amalgam, 29
 Crib to correct finger/thumb sucking, 167, **168**
 Curette, in extraction of primary dentition, 71, **71**
 Cvek pulpotomy, 143, **147–150**

D

Dental age, 133
 DentalVibe™ device, 10–11, **10–11**
 to augment topical anesthetic, **11**
 for buccal infiltration, **11**
 for palatal injection, **11**
 Dicalcium silicate, 96
 Direct pulp capping, 143
 Direct pulp therapy (DPT) for young permanent molars, 93–98
 complications, 98
 diagnosis, 95
 follow-up, 98
 indications for, 95
 medicament, 95–96
 MTA direct pulp cap, **94**
 permanent tooth pulp capping, 94
 permanent tooth pulpotomy, 94–95
 Portland cement, 96
 success criteria, 98
 success rate, 98
 technique, 96–98
 Caries excavation, **96**
 rubber dam placement, **96**
 sodium hypochlorite irrigation, 96, **97**
 Distal shoe, 138–139, **139**
 Distal tipping techniques, 114–117
 Dri-angles, 1–3, **3, 78**
 Dycal, 85–86, **85, 89**

E

Early childhood caries (ECC), 13–28, **25–27**, *See also* Anterior esthetic fixed appliances
 appliance design, 24
 bonded resin composite strip crown, 14, **15**
 caries removal and crown placement, 17–19
 curing, 17–19
 finishing, 17–19
 clinical procedure, 24
 elastomer method, 16
 full coverage prefabricated crowns, 19–20
 indications, 13–14
 inflamed gingiva, 13, **14**
 isolation, 14–17
 oral hygiene, 13
 pretreatment, 13
 routine use of ligature, 15, **16**
 rubber dam placement, 14–17
 steps in fabrication, 24–27
 first appointment, 24
 second appointment, 24–27
 strip crown preparation, 14, **15**
 timing of placement, 27
 Ectopic eruption (EE) of maxillary first permanent molar, 107–119,
 See also Brass wire technique
 adjacent maxillary second primary molar, disking of, 114–118
 black chain elastic removed, **117**
 distal tipping techniques, 114–117
 ectopic spring-loaded distalizer appliance, 114, **117**

 space control, 117–118
 elastomer separators, 108–109
 identification, 108
 observation, 108
 removable appliance, **119**
 treatment modalities, 107
 distal tipping, 107
 interproximal wedging, 107
 Ectopic eruption of maxillary permanent canines, 121–124
 intervention, 121–124, **121–124**
 overretained maxillary right primary canine, **123**
 Ectopic spring-loaded distalizer appliance, 114, **117**
 Elastomer separators, 108–109
 jumbo separators, 108
 Enamel hypomineralization, 99
 Enameloplasty, 79, **80**
 Endoflas®, 63
 Endoflas F. S., 64
 Epinephrine, 7
 Esthetic crowns, 43–50, *See also* Preveneered stainless steel crowns;
 Zirconia crowns
 crimping with pliers, **43**
 preveneered SSCs, 43
 procedure for, 43–46
 shades of, 43, **44**
 Etching/primer, 78
 Extraction of primary dentition, 71–76
 abscess, considerations with, 73–74
 after extraction, 74–76
 169L carbide bur to split primary molar from buccal to lingual,
 72, **75**
 curette, 71, **71**
 injection
 in distal papilla, 72, **73**
 in mesial papilla, 72, **73**
 into sulcus, 72, **73**
 luxation, 71–72, **72**
 straight forceps for primary incisors, 72, **74**
 Eye protection, 178–179
 EZ Pedo, 19

F

Facial caries, 1, **2**
 Ferric sulfate, 55
 Filler resorbability, 63–65
 Finger/thumb sucking, 164–167
 Bluegrass to correct, 167, **168**
 canine interference, 164, **166**
 Crib to correct, 167, **168**
 first-phase orthodontic treatment, 164
 First primary molar, 135
 Fleck's Red Copper Cement, 29
 Fluoride affecting oral bacteria *in vivo*, 85–86
 Formocresol, 55–56
 Frankl behavioral rating scale, 181–182
 Full coverage prefabricated crowns, 19–20
 Full coverage restoration for primary molars, 39–50, *See also*
 Esthetic crowns; Stainless steel crowns (SSCs)

G

Glass ionomer (GI), 85–86, 102
 cements, 91
 temporary restoration, 83
 Groper appliance, 24, **25**

- Guidance techniques, 177–178
 audio-visual distraction, 178, **178**
 auditory distraction, 178, **178**
 minute timer for distraction, 177, **177**
 mirror for distraction, 177, **177**
 palm pressure to reduce anxiety, 177, **178**
 reframing to change mindset, **179**
 rubbing palms together to reduce anxiety, 177, **177**
 soft rubber ball squeezing for mild anxiety, 178, **178**
 fleshy area between index finger and thumb squeezing to reduce anxiety, 178, **178**
- H**
 Habit therapy, 164
 Hall technique, 43
 Halterman appliance, 114, **116–117**
 Hay-rake for tongue thrust, 169, **169**
 Hollenback carver, 16
 Howe plier to reduce mesial–distal size, 41, **43**
 Hypomineralization, 99–105, *See also* Molar–incisor hypomineralization (MIH)
- I**
 Indirect pulp therapy (IPT), for young permanent molars, 83–92
 amalgam, 90
 caries excavation, **87**
 composite, 90
 criteria for success, 90
 diagnosis, 84
 final restoration, **88**, 90
 fluoride affecting oral bacteria *in vivo*, 85–86
 follow-up, 90
 indicated for teeth with reversible pulpitis signs, 84–85
 medicaments, 85
 calcium hydroxide (Dycal), 85
 glass ionomer (Vitrebond), 85
 permanent stainless steel crown, 91
 rubber dam placement, **87**
 success rate, 90
 two-step (stepwise) method, 83
 Vitrebond placement over remaining caries, **88**
 Inferior alveolar nerve block anesthesia, 8–9, **9**
 Infraocclusion of mandibular primary molars, 127–131
 management, 131
 submerged with congenitally missing permanent successor, 129–131
 submerged with permanent successor, 128–129
 submerging mandibular second primary molar, 127, **127**
 Injection
 in distal papilla, 72, **73**
 injection discomfort, 7–8
 in mesial papilla, 72, **73**
 into sulcus, 72, **73**
 Interim therapeutic restoration (ITR), 1–3
 in primary dentition, 1–3
 cervical caries, 1, **2**
 dri-angles, 1–3, **3**
 facial caries, 1, **2**
 indications, 1
 materials, 2–3
 mesial caries, 1, **2**
 occlusal caries, 1, **2**
 procedure, 1–2
 superficial caries, 1, **2**
 Intermediate restorative material (IRM), 55–56, **56–57**
 Intermediate Restorative Material (IRM), 65
 Iodoform-based paste (KRI), 63
 Isodry® isolation techniques, 65
 Isolation for restorative procedures, 179
 Isolite, 78, **78**, **179**
- K**
 Kinder Crowns, 19
 Kri paste, 63, 65
 Kryptex, 29
- L**
 Lidocaine, 6–7
 Light curing, 80, **80**
 Local anesthesia for the pediatric patient, 5–11
 articaine, 6
 bupivacaine, 6
 choice of anesthesia, 6–7
 DentalVibe™ device, 10
 describing to child, 5
 ecchymosis due to lip chewing, **6**
 lip swelling due to lip chewing, **6**
 rash due to anxiety, **6**
 rash due to suspected allergy, **6**
 distraction, 10–11, **10**
 27-gauge long needle, 8, **8**
 27-gauge short needle, 8, **8**
 inferior alveolar nerve block, 8–9, **9**
 injection discomfort, 7–8
 lidocaine, 6
 mepivacaine, 6
 prilocaine, 6
 topical anesthetic placement for long buccal injection, **8**
 in vital pulp therapy, 51
 Lower lingual holding arch/passive lingual arch, 138
 Luxation, in extraction of primary dentition, 71–72, **72**
- M**
 Mandibular pedo partials for premature loss of primary incisors, 135, **135**
 Mandibular primary molars, infraocclusion of, 127–131, *See also individual entry*
 Maxillary first permanent molar, ectopic eruption of, 107–119, *See also* Ectopic eruption (EE)
 Maxillary pedo partials for premature loss of primary incisors, 135, **135**
 Maxillary permanent canines, ectopic eruption of, 121–124, *See also individual entry*
 Mckesson mouth props, **176**, 177
 Mepivacaine, 6–7
 Mesial caries, 1, **2**
 Mineral trioxide aggregate (MTA), 55, 93–96, 143, 147–151
 apical barrier technique with, 151–153
 apical plug with, **151**, **154**
 healing of a gross overfill of, **153**
 loading amalgam carrier with, **97**
 MTA direct pulp cap, **94**
 Mixed dentition typodont, **134**
 Modeling, 174, **175**
 Moisture control, 78
 Molar–incisor hypomineralization (MIH), 99–105
 diagnosis, 99–105

Molar–incisor hypomineralization (MIH) (*continued*)

- etiology, 99–100
 - management of, 101, **102**
 - incisors, **102**
 - molars, **102**
 - prevalence, 99–100
 - severity score of teeth affected with, 101, **101**
 - caries, **101**
 - crown appearance, **101**
 - enamel loss, **101**
 - esthetics, **101**
 - sensitivity, **101**
 - treatment of, 99–105
- Molt mouth prop, **176**, 177
- Mouth props, 176–177
 - Mckesson mouth props, **176**, 177
 - Molt mouth prop, **176**, 177
 - Open Wide Disposable Mouth Rest, 176, **176**
 - Parkell dry-field posterior mouth prop, 176, **176**
 - toothbrush with rubber handle for mouth prop, **176**

N

- Nance appliance, 138, **138**
- Nance holding arch, 24, **24**
- Nano-ionomer, 34
- Non-nutritive sucking, 163–171, *See also* Finger/thumb sucking
- NuSmile ZR crowns, 19, **21–22**

O

- Occlusal caries, 1, **2**, **34**
- Open Wide Disposable Mouth Rest, 176
- Oral hygiene, 13
- Orthodontic elastomeric ligatures, 16

P

- Pacifier habits, 163–164
- Pain evaluation in pulpectomy, 59–60
- Parafunctional habits, 163–171, *See also* Finger/thumb sucking
 - bruxing, 169–171
 - pacifier habits, 163–164
 - tongue thrust, 167–169
- Parent/guardian presence, 180–181
- Parkell dry-field mouth prop, 78, **78**, 158, **158**
 - anterior, 176, **176**
 - posterior, 176, **176**
- Partially erupted teeth, 79
- Periodontal ligament (PDL), 127
- Permanent incisor enamel fragments, reattachment of, 157–160
 - to mandibular central incisor, 159, **160**
 - to maxillary central incisor, 159, **160**
 - Parkell dry-field mouth prop, 157, **158**
 - phosphoric acid in, 158–159, **158–159**
 - procedure, 157–160
 - pulp capping, 157
- Permanent stainless steel crown, 91
- Permanent successor, 127–129, **128**
 - root development of, 133
- Permanent tooth pulp capping, 94
- Permanent tooth pulpotomy, 94–95
- Pit and fissure sealants, 30
- ‘Plastic’ filling materials, 29
- Portland cement, 95
- Preformed anterior crowns (PACs), 19
 - cementation, 20

- crown reduction, 19
 - crown size, 19
 - subgingival reduction, 20, **23**
 - try-in, 20
- Preveneered stainless steel crowns, 43
 - coarse football diamond bur for 2-mm occlusal reduction, **44**, **45**
 - coarse tapered round end diamond bur for buccal and lingual reduction, **44**, **45**
 - donut diamond bur for 2-mm occlusal reduction, **44**, **45**
 - donut diamond bur to check depth of occlusal reduction, **44**, **45**
 - fine tapered diamond bur for mesial and distal reduction, **44**, **45**
 - fine tapered round end diamond bur, **44**, **45**
 - preveneered versus zirconia, 50
 - size selection, **44–45**
- Prilocaine, 6–7
- Primary dentition, 1–3
 - extraction of, 71–76, *See also* Extraction of primary dentition
 - ITR in, 1–3
- Primary incisors, 134–135
 - restoration, 13–28, *See also* Early childhood caries (ECC)
- Primary molar adhesive tooth restoration, 29–36, *See also* Adhesive
 - primary molar tooth restoration
 - ideal operative field, 29–30
 - rubber dam isolation, 29–30
- Primary molars, 51–57
 - full coverage restoration for, 39–50
 - vital pulp therapy for, 51–57, *See also individual entry*
- Pulp capping, 143–147, 157
 - direct pulp capping, 143
- Pulp necrosis, 98
- Pulp tests, 61–62
- Pulp Therapy Guideline, 59
- Pulpal bleeding, 62
- Pulpal treatment in young permanent incisors following traumatic injuries, 143–155
 - apexification and apical plug, 147–151
 - apexification of right incisor, **144**
 - direct pulp capping, 143
 - mineral trioxide aggregate (MTA), 143
 - pulp capping, 143–147
 - pulpotomy, 143–147
 - regenerative endodontics, 155
 - strengthening the root, 153–155
- Pulpotomy, 143–147
 - and SSCs crown model, **52**
- Pulpectomy for primary teeth, 59–68
 - clinical diagnosis, 59
 - clinical evaluation, 60–65
 - history, 60–61
 - mobility, 61–62
 - percussion, 61–62
 - pulp tests, 61–62
 - pulpal bleeding, 62
 - radiographic assessment, 62–63, **63**
 - root resorption, 63
 - tooth color change, 62
 - diagnostic concerns, 59–60
 - interim therapeutic restorations for diagnosis, 59–60
 - mandibular first primary molar, 65, **66–68**
 - mandibular second primary molar, 66, **66**
 - pain evaluation, 59–60, **61**
 - pulpectomy research and filler resorbability, 63–65

R

Radiographs, guidance during, 179–180
 size 4 film for lateral radiographic view, 179, **181–182**

Rapid setting plastic filling materials, 29

Reattachment of permanent incisor enamel fragments, 157–160

Regenerative endodontics, 155

Resin-based composites (RBCs), 29–33

Resin-modified glass ionomer (RMGI), 48
 restorative cements, 30, 33–34

Restorative procedures
 isolation for, 179
 Breathe-Right Nasal Strip, 179
 rubber dam with a portion under nose cut away, **179**

Reversible pulpitis signs, IPT for, 84–85

Root canal obliteration, 98

Root resorption, 63

Root strengthening, 153–155

Routine use of ligature, 15, **16**

Rubber dam isolation, 29–30
 dam placed on winged clamp extraorally, 52, **53**
 steps for, 30
 in vital pulp therapy, 51–53
 W8A rubber dam clamp ligated with floss, 52, **52**

Rubber dam placement, 14–17

Rubber dam with slit technique, **40**

S

Sealants, 77–80
 AAPD recommendations for, 77
 bonding agent, 78–79
 caries detection, 77–78
 dri-angles, **78**
 etching/primer, 78
 light curing, 80, **80**
 moisture control, 78
 Parkell dry-field mouth prop, **78**
 partially erupted teeth, 79
 retention and follow-up, 80
 surface preparation, 79–80, **80**

Second primary molar, 135–136

Separators, 108–109

Sequence of eruption, 133

Silver amalgam, 29

Silver nitrate, 29

Slit dam technique, 14, 30, **31–32**

Sodium hypochlorite (NaOCl), 55, 147

Space control, 117–118

Space maintenance, 133–142
 alveolar bone covering permanent successor, 133
 appliance fabrication, banding and impression for, 139–140
 appliances for, 134
 band and loop, 135–137, **135–136**
 chairside fabrication, 140–141
 dental age, 133
 distal shoe, 138–139, **139**
 first primary molar, 135
 lingual arch wire interfering with mandibular second premolar eruption, 134, **134**
 lower lingual holding arch/passive lingual arch, 138
 mixed dentition typodont, 134, **134**
 nance appliance, 138, **138**
 permanent successor, root development of, 133

prefabricated space maintainers, **142**

primary incisors, 134–135

problems with space maintainers, 134

second primary molar, 135–136
 sequence of eruption, 133
 time elapsed since loss of primary tooth, 134
 transpalatal arch/palatal arch bar, 137–138, **138**

Spoon excavator, **2**

Stainless steel crowns (SSCs), 19, 29, 39
 Boley gauge to measure mesial–distal width, 41, **41**
 cements, 91–92
 glass ionomer cements, 91
 checking, **42**
 cleaning, **42**
 crimping with pliers, **43**
 with difficulty fitting, 41–43
 distal reduction of second primary molar, **40**
 Howe plier to reduce mesial–distal size, 41, **43**
 operator seating, **42**
 permanent stainless steel crown, 91
 precontoured, **40**
 procedure for, 39–41
 rubber dam with slit technique, **40**
 subgingival interproximal reduction, **40**
 uncountoured, **40**

Strip crown preparation, 14, **15**

Subgingival interproximal reduction, **40**

Subgingival reduction, 20, **23**

Submerged with congenitally missing permanent successor, 129–131

Submerged with permanent successor, 127–129

Superficial caries, 1, **2**

Surface preparation, 79–80, **80**

T

Tetracalcium alluminoferrite, 96

TGuard™, 164, 167

Tongue thrust, 167–169
 hay-rake for, 169, **169**
 overextended crib for, **169**

Tooth color change, 62

Transpalatal arch/palatal arch bar, 137–138, **138**

Tricalcium aluminate, 96

Tricalcium silicate, 96

Tylenol, 74

V

Vital pulp therapy for primary molars, 51–57
 intermediate restorative material (IRM), 55–56, **56–57**
 local anesthesia, 51
 medicaments, 55
 ferric sulfate, 55
 formocresol, 55–56
 mineral trioxide aggregate (MTA), 55
 occlusal reduction with large round bur, **53**
 procedure, 53–55
 access opening, 54, **54**
 curette to remove tissue tag, 54, **54**
 hemostasis, 54, **55**
 irrigation with monoject syringe, 54, **54**
 pulpotomy and SSCs crown model, **52**
 radiographic evaluation, 51
 restoration, 56–57

Vital pulp therapy for primary molars (*continued*)

rubber dam isolation, 51–53

slit technique, **53**

Vitapex®, 63–64, 67–68

Vitrebond, 85–86, **85, 88**

W

W8A rubber dam clamp, 52, **52**

X

Xylocaine, 51

Y

Young permanent incisors, 143–155

pulpal treatment in, 143–155, *See also individual entry*

Young permanent molars, 83–84

direct pulp therapy for, 93–98, *See also individual entry*

IPT for, 83–92, *See also Indirect pulp therapy (IPT)*

Z

Zinc oxide eugenol (ZOE) pulpectomy, 63–65, **64**

Zirconia crowns, 19, 46–50

cementation, 48–50, **48**

common problems with preparation, 47–48

digital pressure holding, 49, **49**

for mesial–distal space loss, 46, **47**

occlusion, checking and adjusting, 49, **49**

pink try-in zirconia crown for size selection, **47, 48**

preveneered versus zirconia, 50

procedure for, 47

size selection, 47, **47**

try-in, 48

